

The first laboratory confirmed invasive meningococcal disease of serogroup C with abdominal clinical presentation in Slovakia, 2019

Kružlíková A.¹, Gőczeová J.¹, Šoltys K.^{2,3}, Piťková R.⁴, Ťažký B.⁴, Mikas J.¹

¹National Reference Centre for Meningococci and Laboratory of Molecular Diagnostic – Department of Medical Microbiology, Public Health Authority of the Slovak Republic, Bratislava, Slovak Republic

²Department of Microbiology and Virology, Faculty of Natural Sciences, Comenius University in Bratislava, Slovak Republic

³Comenius University Science Park, Comenius University in Bratislava, Slovak Republic

⁴Forensic-Medical and Pathological-Anatomical Workplace, The Health Care Surveillance Authority, Banská Bystrica, Slovak Republic

ABSTRACT

Acute abdominal clinical presentations as initial manifestation of meningococcal infection are uncommon and frequently provoked by hyperinvasive isolates of meningococci. 10% of patients infected by the meningococcal strain, that is on the rise in Europe, suffer from abdominal pain. We hereby report the first laboratory confirmed fatal case of an otherwise healthy adult male presented with acute abdominal pain during first 24–48 hours, masking *Neisseria meningitidis* (*N. meningitidis*) infection. In the National Reference Center for meningococci, in the blood of a man post-mortem, we identified *N. meningitidis* serogroup C using real time polymerase chain reaction (PCR). Subsequently, massively-parallel sequencing (MPS) was performed on isolated total DNA for pathogen confirmation and further investigation.

KEYWORDS

invasive meningococcal disease – IMD – abdominal pain

ABSTRAKT

Kružlíková A., Gőczeová J., Šoltys K., Piťková R., Ťažký B., Mikas J.: Prvé laboratórne potvrdené invazívne meningokokové ochorenie séro skupiny C s abdominálnou klinickou prezentáciou na Slovensku, 2019

Akútne brušné klinické prejavy ako počiatočný prejav meningokokovej infekcie sú neobvyklé a často ich vyvolávajú hyperinvazívne izoláty meningokokov. Iba 10 % pacientov infikovaných meningokokovým kmeňom, ktorý je v Európe na vzostupe, trpí bolesťami brucha. V tejto práci prezentujeme prvý laboratórne potvrdený smrteľný prípad, inak zdravého dospelého muža, s akútnou bolesťou brucha počas prvých 24–48 hodín maskujúcim infekciu *Neisseria meningitidis* (*N. meningitidis*). V Národnom referenčnom centre pre meningokoky sme v krvi post mortem identifikovali *N. meningitidis* séro skupiny C pomocou polymerázovej reťazovej reakcie (PCR) v reálnom čase. Následne sa realizovalo masívne paralelné sekvenovanie (MPS) na izolovanej celkovej DNA pre potvrdenie patogénu a pre ďalšie jeho skúmanie.

KLÚČOVÉ SLOVÁ

invazívne meningokokové ochorenie – IMD – bolesti brucha

Epidemiol Mikrobiol Imunol, 2021;70(1):72–75

INTRODUCTION

Early abdominal presentations of invasive meningococcal disease have been increasingly described in Europe in the last 5–7 years. Atypical clinical presentation is associated with higher case fatality rates and can lead to misdiagnoses. Such risks highlight the need for clinicians to consider IMD in their differential diagnoses of patients with acute gastrointestinal symptoms and intensive abdominal pain. In fatal cases of IMD, the involvement of all compartments of laboratory diagnostics is important. In medical practice, in addition to routine autopsy and histopathology, other diagnostic methods are used to examine body fluids and tissues, such as microbiological tests, immunohistochemistry and molecular methods especially real time PCR, which

often definitively determines the etiological agent. The aim of this report is to describe the first laboratory confirmed fatal case of IMD with atypical abdominal course in Slovakia, in the first 24 hours.

CASE REPORT

In December 2019, 45-years-old male without any previous significant health problems, complaining about severe cramping abdominal pain, not subsiding following non-steroid-anti-inflammatory drug administration, during the first 24 hours was treated. He vomited and had diarrhea several times. Later he suffered from meteorism and anuria. The patient was afebrile all the time and severe cramping abdominal

pain without peritoneal irritation was present. Chest and abdominal X-rays showed no focal pain-related changes. Abdominal ultrasound and subsequent CT examination did not reveal any cause of the acute abdomen. The condition of the patient was evaluated with a preliminary conclusion as other and unspecified abdominal pain. The patient's condition deteriorated rapidly. It was associated with tachypnea, acral cyanosis, and areas of petechiae throughout the body. Complete arrest of abdominal peristalsis was found. The patient experienced marked changes in consciousness; acute respiratory insufficiency, tachycardia 120–150/min and hypotension occurred. The patient had a severe septic condition. Presence of whole body rash and fulminant course of the disease raised suspicion of meningococcal septicaemia. No symptoms of meningeal irritation appeared throughout the hospitalization. Because of severe sepsis the patient was admitted to the Department of Anesthesiology and Intensive Care. Laboratory results suggested thrombocytopenia and bleeding disorder. Later, disseminated intravascular coagulation (DIC) developed and hepatorenal failure occurred. Despite all medical and rescue treatments the patient died. An autopsy was recommended to definitely determine the cause of death.

Diagnostical methods and laboratory results

Molecular detection of meningococcal DNA in blood specimen using real-time PCR was performed. DNA template was prepared with QIAamp DNA extraction kit. Real-time PCR assay was performed for detection of *N. meningitidis* using primers and probe as described in the WHO manual [1]. For serogroup identification a multiplex PCR using primers described in Désirée E Bennett *et al.* [2] were used. Total DNA isolated from whole blood was fluorometrically quantified, diluted and fragmented using transposon-based chemistry (Illumina, CA, USA). Fragments that were consecutively non-specifically amplified and simultaneously indexed using limited number of PCR cycles (Illumina, San Diego). The concentration of the final library was measured with Qubit™ dsDNA HS Assay Kit (Thermo Fisher Scientific, Waltham, USA) and the fragment length determined using Agilent 2100 Bioanalyser (Agilent Technologies, CA, USA). Finally the library was sequenced with paired-end sequencing 2 x 300 on Illumina MiSeq platform. Data analysis was performed with CLC Genomics Workbench.

PCR tested blood specimen was confirmed to contain DNA *N. meningitidis* serogroup C.

High-throughput sequencing

Totally, over 6 million paired reads were obtained. After trimming low quality reads ($Q < 30$), length filtering and de novo assembly with strict parameters set more than 300.000 contigs were obtained. Within 128 con-

tigs ranging from 159 bp to 515 bp positively identified as *N. meningitidis* 3 of them were annotated as partial genes (rplO, rplT, rpmC) producing the 50S ribosomal proteins and 3 as partial genes (rpsD, rpsE, rpQ) producing the 30S ribosomal proteins S4, S5 and S17. The detected sequences of rpsD, rpsE, rpQ matched with the sequences deposited within GenBank database with 100% identity while each of the detected genes coding 50S proteins possessed 1 mutation. The set of genomic data comprised sequences of beta-barrel assembly machinery (BAM) including BAM complex represented by two sequences matching the bamA gene and BamA/TamA family outer membrane protein. Also two of three inner membrane proteins, TonB and ExbB, participating at siderophore transmembrane transport have been found. Furthermore a fragment of IgA1 protease activity gene, PilD gene as well as Opacity-associated protein Op54 have been detected. The remaining sequences belonged mostly to genes involved in metabolic and biosynthetic processes, signal transduction (protein-P-II uridylyltransferase), manganese, zinc, heme binding and also transposable elements (IS110 and IS30 family transposase, putative IS1106 transposase). Two genes involved in glycan metabolism (lgtB2, ftsW) were found. Either none or without sufficient length or coverage sequences have been detected that could help in the identification of the clonal complex or sequence type (ST) of the MPS sequenced total DNA of *N. meningitidis* from blood. Unfortunately, neither the ST nor the clonal complex (CC) could be determined from the isolated DNA.

Autopsy results

An autopsy was performed approximately 20 hours after death. Gross external examination of the body revealed purpuric lesions covering the head, trunk, abdomen and limbs, with some petechial haemorrhage of the conjunctiva, skin and acral cyanosis. Internal examination showed numerous petechiae in the mucosa of pharynx and larynx and in the scalp as well as in the subpleural, subepicardic and subendocardic tissue with haemorrhagic infiltration of the periaortic tissue. The brain showed oedema, with no macroscopic evidence of purulent meningitis. Also, there was observed cardiomegalia, oedema of the lungs. Both adrenal glands showed massive diffuse parenchymal haemorrhage (Figure 1). Moreover, there were signs of cardiopulmonary resuscitation. Meningitis or other inflammatory foci were not found in any organs. The lungs were congested with areas of haemorrhagic extravasation. In the heart perivascular cardiomyofibrosis was detected. Microscopic tissue examination was performed by using formalin-fixed paraffin embedded tissue sections at 4 mm and stained with hematoxylin-eosin and confirmed macroscopic findings. The autopsy revealed and reported Waterhouse-Friderichsen syndrome as a cause of death.

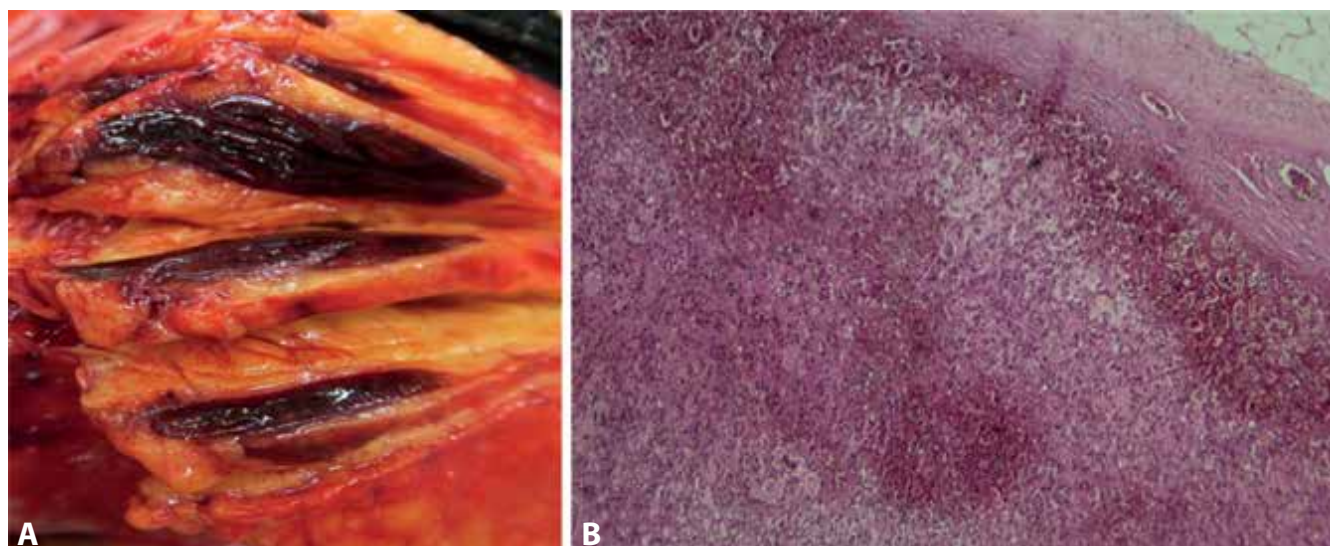


Figure 1. Macroscopic findings (A) and histopathology (B) of massive diffuse parenchymal haemorrhage in both adrenal gland

DISCUSSION

Over the past few years, however, abdominal pain has been observed as another early clinical sign – but physicians tend not to think of invasive meningococcal disease. Acute abdominal pain as an initial manifestation of meningococcal infection is rare. It can present both as an isolated entity, as well as in the context of meningococcal sepsis. In this article, is the first described fatal case of meningococcal disease in Slovakia, presented by atypical abdominal symptoms in initial phase, followed by septic shock.

Suspecting and diagnosing meningococcal disease early is critical for initiating timely prophylaxis and preventing secondary cases. The risk for disease is the highest during the initial 1–4 days after exposure [3]. The course of fatal meningococcal septicemia is severe and associated with high mortality.

In fatal cases of meningococcal septicemia, bacteriological diagnostics may not be simple due to postmortem replication and relocation of endogenic microflora. In medicolegal practice, aside from routine autopsy and histopathology, also other diagnostic methods, such as microbiological tests, immunohistochemistry and PCR, are used to examine body fluids and tissues [4]. PCR, especially real-time PCR, is sensitive and specific enough to detect meningococcal invasive disease. And it is irreplaceable, especially if the results of conventional bacteriological examination appear to be controversial [5]. Our present findings suggest that molecular microbiology should be accepted as the dominant detection method for postmortem evaluation.

Confirmed IMD cases in France between 1991 and 2016 were screened for the presence within the 24 hours before diagnosis of at least 1 of the following criteria: abdominal pain, gastroenteritis with diarrhea and vomiting, or diarrhea only. A higher case fatality

rate was observed in these cases compared to 10.4% in all IMD in France ($P = 0.007$) with high levels of inflammation markers in the blood and with previous abdominal surgery. Isolates of group W were significantly more predominant in these cases compared to all IMD. The recent increase of the cases with abdominal presentation since 2014 seems to be driven by the increase of IMD cases due to CC11 isolates of groups C and W. While group C isolates belonged to several lineages of CC11, group W isolates with abdominal presentation belonged exclusively to the lineage of the South American-UK strain. These observations were in line with those obtained in the United Kingdom and in Chile suggesting that these isolates are significantly associated with abdominal presentations of IMD. The causal relationship between *N. meningitidis* CC-11 and its presentation in IMD with abdominal pain remains unclear. Changes in genes responsible for metabolic functions in South American/UK and Anglo-French Hajj strains have been demonstrated. Guiddir *et al.* suggest these changes may also affect genes responsible for virulence factors in the meningococcal bacterial wall (lipopolysaccharide and peptidoglycan), which are potent inducers of the inflammatory response; this in turn implies that the induction of an abdominal inflammatory response may be involved in abdominal pain [6].

Several other theories attempt to explain the underlying pathophysiology associated with this clinical entity including, mesenteric hypo-perfusion, septiceiploic micro infarcts, splanchnic invasion via hematogenous spread or ascending infection from the urogenital tract or immune complex deposition. Severe diseases commonly associated with higher antigenic loads could trigger immune complex formation and later deposition to abdominal vascular cells and pericardium responsible for initial presentation and secondary complication respectively [7, 8]. Recently, inflammation and

detectable meningococci were reported in a duodenal biopsy during a case meningococcemia with abdominal pain [9].

CONCLUSION

We concluded that the patient died of IMD caused by *N. meningitidis* serogroup C, which manifested during his life with an unusual abdominal clinical presentation and finally septic shock associated with Waterhouse-Friderichsen syndrome. The findings are beneficial and very important for the necessary consideration in the differential diagnosis of abdominal pain in the initial phase of atypically occurring IMD.

REFERENCES

1. *Streptococcus pneumoniae*, and *Haemophilus influenzae*: WHO manual, 2nd ed, 2011. World Health Organization. Available at [www: https://apps.who.int/iris/handle/10665/70765](https://apps.who.int/iris/handle/10665/70765).
2. Désirée EB, Mary TC. Consecutive use of two multiplex PCR-based assays for simultaneous identification and determination of capsular status of nine common *N. meningitidis* serogroups associated with invasive disease. *J Clin Microbiol*, 2006;44(3):1127–1131.
3. Ridpath AD, Halse TA, Musser KA et al. Post-mortem diagnosis of invasive meningococcal disease. *Emerg Infect Dis*, 2014;20(3):453–455.
4. Mularski A, Žaba C. Fatal meningococcal meningitis in a 2-year-old child: A case report. *World J Clin Cases*, 2019;7(5):636–641.
5. Maiden MC, van Rensburg MJ, BrayJE, et al. MLST revisited: the gene-by-gene approach to bacterial genomics. *Nat Rev Microbiol*, 2013;11(10):728–736.
6. Guiddir T, Gros M, Hong E, et al. Unusual initial abdominal presentations of IMD. *Clinical Infectious Diseases*, 2018;67(8):1220–1227.
7. Akinosoglou K, Alexopoulos A, Koutsogiannis, et al. *Neisseria meningitidis* presenting as acute abdomen and recurrent reactive pericarditis. *Braz J Infect Dis*, 2016;20(6):641–644.
8. Sanz Álvarez D, Blázquez Gamero D, Ruiz Contreras J. Abdominal acute pain as initial symptom of invasive meningococcus serogroup A illness. *Arch Argent Pediatr*, 2011;109(2): e39–41. doi: 10.1590/S0325-00752011000200015.
9. Cheddani H, Desgabriel AL, Coffin E, et al. No neck pain: meningococcemia. *Am J Med*, 2018;131(1):37–40.

Acknowledgments

This publication is the result of the project implementation ITMS 26240220086.

We thank the Faculty of Natural Sciences and Comenius University Science Park in Bratislava and The Health Care Surveillance Authority in Banská Bystrica for their cooperation in this case.

All authors participated in the design, analysis, and interpretation of the study.

No reported conflicts of interest.

Do redakce došlo dne 19. 7. 2020.

Adresa pro korespondenci:

RNDr. Anna Kružlíková

Úřad veřejného zdravotnictví SR

Trnavská cesta 52

826 45 Bratislava

Slovenská republika

e-mail: anna.kruzlikova@uvzs.sr