

FORMS OF OCULAR LARVAL TOXOCARIASIS IN CHILDHOOD. A REVIEW

Krásný J¹, Šach J²

¹Department of Ophthalmology, Královské Vinohrady University Hospital, Prague

²Institute of Pathological Anatomy, Královské Vinohrady University Hospital, Prague and ³rd Faculty of Medicine, Charles University Prague

The authors of the study declare that no conflict of interests exists in the compilation, theme and subsequent publication of this professional communication, and that it is not supported by any pharmaceuticals company. The study has not been submitted to any other journal or printed elsewhere, with the exception of congress abstracts and recommended procedures.

Dedicated to Professor I. Karel, Knight of the Czech Medical Society for 2007 and my first teacher of clinical ophthalmology

Received: 14 January 2022

Accepted: 24 August 2022

Available on-line: 10 October 2022



MUDr. Jan Krásný
Oční klinika FNKV
Šrobarova 50
10 034 Praha 10
E-mail: jan.krasny@fnkv.cz

SUMMARY

The aim of this paper is to present an outline of forms of ocular manifestations of visceral larva migrans in children, as illustrated by the extensive photographic documentation. Ocular larval toxocariasis (OLT) has various clinical manifestations even in childhood age, in which age representation has an influence. The most common is presence of peripheral granuloma of the eye, frequently with a tractional vitreal streak leading from the retinal periphery to the optic nerve papilla. This is followed by granuloma of the posterior pole of the eye, usually reaching from the macular landscape to the central retinal periphery, always with vitritis. In children OLT may be manifested also in affliction of the optic nerve (cystic granuloma of the head of the optic nerve or neuropathy with vitreal reaction), fulminant endophthalmitis and in rare cases also diffuse chorioretinitis. The diagnosis rests upon a clinical ophthalmological finding, as well as laboratory examination of the levels of antibodies with potential eosinophilia. Histological examination may demonstrate spherical polypoid ossification in the choroid at the posterior pole of the eye as a consequence of fibrotisation and calcification, proceeding from the surrounding area of the absorbed larva. General combined treatment with antihelminthics and corticosteroids is arduous and does not always produce the desired effect in the sense of a satisfactory improvement of visual acuity. In differential diagnostics, manifestations of OLT in small children are still associated with retinoblastoma and a clinical picture of other intraocular diseases.

Key words: ocular larval toxocariasis, visceral larva migrans, antihelminthics

Čes. a slov. Oftal., 79, 2023, No.2, p. 59–67

INTRODUCTION

Manifestations of larval toxocariasis are triggered in humans by third-stage larvae predominantly of dog roundworms (*Toxocara canis*) or cat roundworms (*Toxocara cati*). The pathology has a number of clinical forms. After infection, visceral, ocular or mixed forms may appear. Another form is covert, which is subclinical and probably the most common. These adult roundworms (nematodes) live in the small intestine of dogs and cats. After copulation, their females release eggs daily into the contents of the intestines. After defecation, under favourable climatic conditions larvae develop in soil substrates or in water, where they can survive. This is therefore an omnipresent parasite [1]. From this there ensues the problem of geophagia in the case of children who may become infected in this manner, since the presence of eggs or larvae was found in

10–30% of soil samples in locations of both public parks and children's playgrounds [2]. Another possible cause of infection is the ingestion of larvae or eggs in insufficiently cooked meat of infected animals. After ingestion, the larvae may attack the parasite's host, i.e. humans, since they are released from mature eggs in the digestive tract. They do not develop further here and penetrate from the small intestine into the blood stream. Through the bloodstream, but also by means of their own migration, they may penetrate into various organs, including the eye [1].

Larvae were first detected by H. Wilder in 1950 upon an analysis of 46 enucleated eyes of children with retinoblastoma, pseudoglioma and unclear endophthalmitis. In 24 of them he detected larvae or larval capsules of roundworms accompanied by the presence of eosinophils [3]. Two years later, P.C. Beaver et al. detected toxocariasis as an intestinal parasite of dogs and cats in connection with

a human pathology, which they termed visceral larva migrans (VLM), accompanied by eosinophilia [4]. In 1956 R.L. Nichols reviewed the histological preparations of H. Wilder and identified the majority of larvae as *Toxocara canis* [5]. A detailed examination of inflammatory intraocular lesions demonstrated granulomas with the presence of eosinophils, as well as epithelioid cells, plasmocytes, macrophages, polymorphonuclear leukocytes and fibroblasts [6].

The first reports of probable occurrence of the ocular form of larval toxocariasis (OLT) in Czechoslovakia appeared at the turn of the 1970s [7–10]. A fundamental watershed in the diagnosis of larval toxocariasis in the Czech Republic was brought about by the introduction of modern serological methods at the end of the 20th century, in connection with the spouses M. Uhlíková and J. Hübner, whose studies remain highly significant to this day [11–14]. This fact was reflected in several articles which were of fundamental importance in Czech and Slovak ophthalmology at the beginning of this century. Above all this concerns an analysis of forms of OLT with regard to seeking their causes and the manner of ocular affliction, including the frequency of ocular affliction and the importance of serological diagnosis in differential diagnostic considerations [1]. In addition, there was the possibility of toxocariasis from the fluid of the anterior chamber of the eye [15], or the significance of pars plana vitrectomy (PPV) in its diagnosis [16]. The first two studies were not accompanied by photographic documentation of OLT, while the third study, together with a chapter in the monograph “Uveitides”, presented images of peripheral granuloma [17]. Individual forms of OLT do not differ according to the age of affliction and have their clinical characteristics according to localisation. The prevalence of OLT is stated at 9.7 cases per 100 000 schoolchildren, incorporating definitive and highly suspected manifestations of this parasitic infection [18].

Systemic manifestations of VLM

Systemic visceral infection has generally known symptoms of inflammations, namely fever and nausea, as well as cough, but the majority of patients are asymptomatic [6]. Children also manifest lymphadenopathy or hepatosplenomegaly, as well as alaragia and arthritis [19], or abdominal pains and loss of appetite [20]. There are also non-specific symptoms associated with the central nervous system: drowsiness or conversely hyperactivity [19], and above all headaches [19,20]. The possibility of parasitic pathology is considered in the case of higher eosinophilia, which may be 20–80%, upon a background of concurrent increased lymphocytosis within the values of several thousand, mainly in the first months of the illness. The number of ingested mature eggs, together with the current immune condition of the host, then evidently determines the severity and scope of the clinical symptoms of larval toxocariasis. A severe general course of VLM upon a background of myocarditis or affliction of the central nervous system, incorporating focal and generalised seizures with co-participation of excessive immunological response to parasitic infection, may even lead to fatality [6]. In children the visceral form is far more

common, OLT represents only 5% of cases [20]. To date opinions differ regarding the cause of ocular affliction. In the case that the individual does not develop sufficient immunity, the larvae may migrate freely through the bloodstream without any especial limitation. For the clinical picture it is decisive as to whether they penetrate from the retinal artery or through the choroidal capillaries [21]. Histologically, direct invasion by *Toxocara* larvae was confirmed for the peripheral vitreoretinal form of the pathology [12]. The inflammatory reaction of intraocular tissues itself is most probably triggered by sensitisation of the host to secretions excreted by the larvae or larval antigens which are released from decaying or dead larvae, which may also be a consequence of treatment [6]. Following recognition of the antigen nature of the roundworm, a defensive immune reaction of the immune complex and late cellular mechanism is triggered, contributing to the destruction of the larvae. It is the release of additional antigens that accentuates a further immune response beneath an image of inflammatory granulomatous uveitis [22]. In the case of solitary OLT, eosinophilia does not exceed 5–7%, and the number of lymphocytes is generally within the norm, the levels of antibodies are generally low to potentially medium. Higher values then indicate the mixed form [1].

Clinical picture of OLT

Ocular manifestations are generally unilateral, regardless of whether this concerns the right or left eye [23], an important diagnostic symptom in connection with a deterioration of visual acuity (VA), which the patient may not always be aware of in the initial stages. Bilateral affliction is rare, but possible. Patients are prompted to visit a doctor only after a fundamental deterioration of vision due to vitreous manifestations. In children this may be strabismus due to a deterioration of VA or leukocoria. OLT is stated as one of the possible causes of posterior uveitis in the child population with regard to the aforementioned geophagia in 3–18% of cases. In the Czech population there is substantial affliction of the adult population. Out of a cohort of 182 patients with ocular manifestations, children aged up to 15 years constituted only 6% of cases, whereas the age group of 36 to 75 years represented 73% [1], which corresponded also to the representation of the visceral form in the Czech Republic [13]. Boys are afflicted more frequently than girls. A different age representation is stated for the three basic forms of ocular affliction: for fulminant endophthalmitis this is the age range of 2–9 years, when it is most severe. Granuloma of the posterior pole of the eye has its main representation within the age range of 6–14 years. The most common manifestation of this parasitic infection is peripheral granuloma, which belongs to the image of OLT primarily in adulthood [2,17]. The frequency of representation of peripheral granuloma in children is around 60% [25,26], and is generally stated without age difference at 44% [6,25]. The actual granuloma masses of OLT are highly reflective and confirm close contact of the vitreous membranes with the retina [26]. The response to infiltration by larvae (a number of larvae are presumed, not

only one) is massive local inflammation in the form of granuloma of a whitish colour, which incorporates affliction of the retina and peripheral vitreous. An important factor for the possibility of occurrence of granuloma of toxocara etiology is anamnestic data concerning the consumption of raw meat, which applies mainly to adult patients [27,28].

Peripheral granuloma is manifested in parasitic affliction in the periphery of the ocular fundus, in which it is not entirely clear as to why toxocara larvae have an apparent preference for this localisation. It may reflect the local retinal and choroidal vascular microanatomy with regard to the fact that the majority of the spreading of this parasite is initially haematogenous. Inflammation may be diffuse (Figure 1 – left) and may resemble the “snowbank” that is a classic manifestation of pars planitis, which may present a differential diagnostic problem. The vitreous membranes often surround the actual granuloma around the circum-

ference and enter deeper into the vitreous body and are less frequently in a transvitreal direction. The contraction of these membranes subsequently generates traction in the form of a radial retinal falciform fold. The granuloma may thus extend from the periphery to the optic nerve papilla (Figure 1 – right). Many peripheral lesions, primarily nasally, are asymptomatic. It is only vitreous inflammatory reaction or retinal traction with affliction of the macula that may lead as far as retinal detachment. The inflammatory process itself is then detected in a diagnostic analysis.

Granuloma of the posterior pole of the eye may be localised anywhere on the posterior pole, mainly tending to be in a subfoveolar (Figure 2 – left) or juxtapapillary position (Figure 2 – right). It constitutes a granulomatous mass mostly with a size of one papillary diameter, although it may also be larger. Its colour is generally whitish or greyish-white. A long-term persistent process may lead to se-

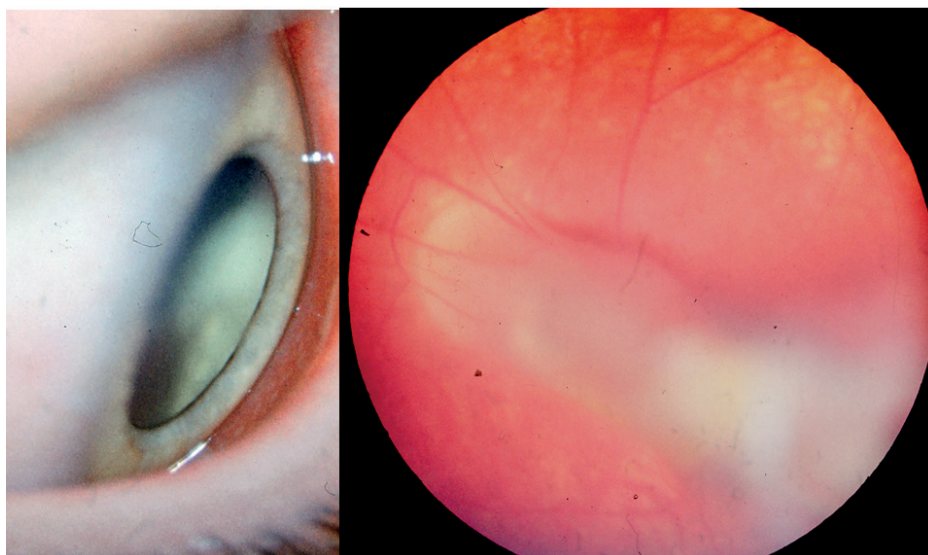


Figure 1. Left: Diffuse peripheral vitreoretinal inflammation of toxocara etiology
Right: Tractional vitreous streak of toxocara granuloma extending from the retinal periphery to the optic nerve papilla

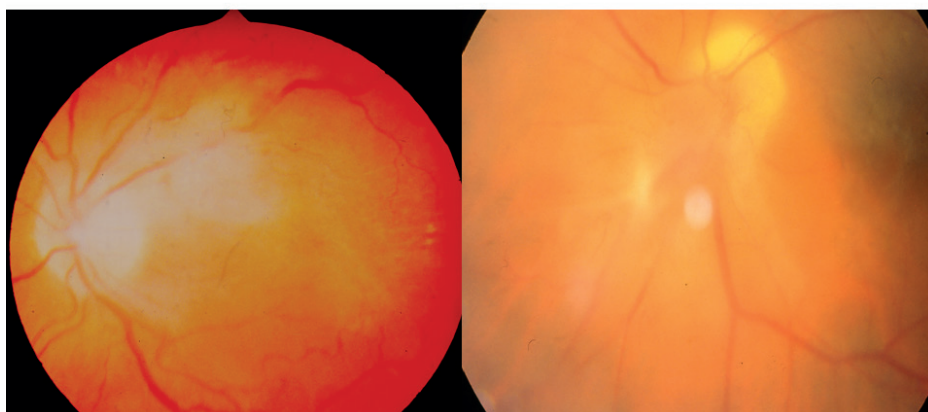


Figure 2. Left: Toxocara granuloma with subfoveolar location inducing CME
Right: Toxocara granuloma with juxtapapillary location accompanied by pronounced vitritis

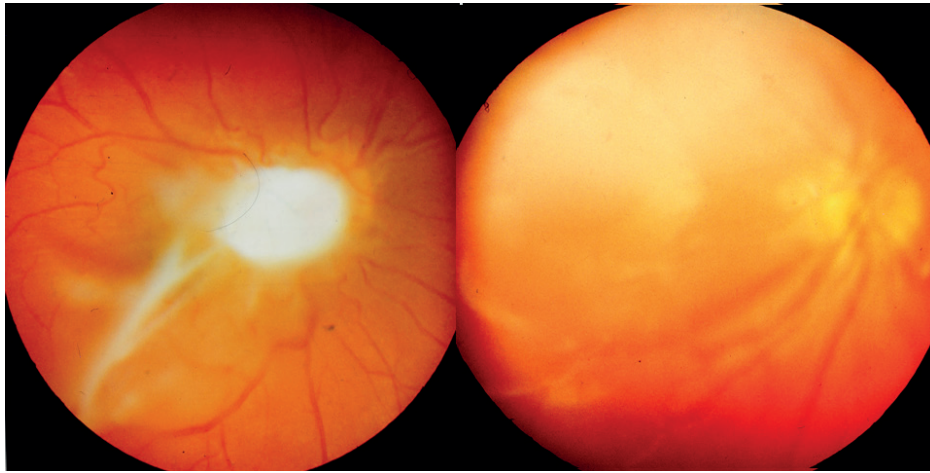


Figure 3. Left: Toxocara granuloma lying above the optic nerve papilla and macular region with preretinal membranous structures and vitritis

Right: Extensive whitish toxocara granuloma extending from the macular area into the upper central periphery of retina with vitritis

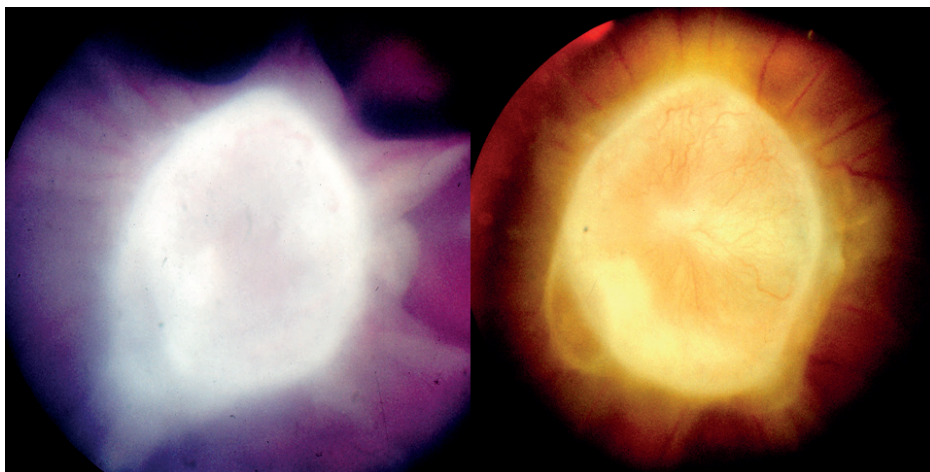


Figure 4. Left: Cystic granuloma of the optic nerve papilla of toxocara etiology with vitreous streaks before general therapy

Right: Cystic granuloma of the optic nerve papilla of toxocar etiology with capillaries on its surface six months after combined treatment

condary atrophy or conversely to hyperplasia of the retinal pigment epithelium. It is accompanied by vitritis of varying scope, from minimal to massive, with the formation of pre-retinal membranous structures (Figure 3 – left). Granuloma of the posterior pole may be localised without contact with the macular region or optic nerve, potentially also with a larger diameter (Figure 3 – left), which necessitates differential diagnostic contemplation in relation to retinoblastoma. In small children its detection is mostly as late as in connection with the development of strabismus due to deprivation of VA, or upon a determined deterioration of vision within the framework of preventive examinations.

Affliction of the optic nerve represents a clinical picture of neuropathy accompanied by vitreoretinal reaction in its surrounding area (Figure 4) or a cyst in the region of the head of the optic nerve (Figure 5). The image of toxocara optic neuropathy may be different; it is a painful

acute inflammatory neuropathy or sectoral edema, or a diffuse edema mostly with peripapillary infiltration.

Endophthalmitis of toxocara etiology may also be accompanied by a painful condition and an image of mixed injection on the eyeball at the onset of the pathology. The reaction in the anterior chamber is often minimal, but in rare cases it may be manifested even in hypopyon or an occlusive fibrin membrane in the pupil. The fundamental image represents a cellular reaction in the vitreous body, rendering differentiation of the ocular fundus impossible (Figure 6 – left), up to an image of leukocoria. On ultrasound imaging (US) irregular hyperechogenicity of the vitreous body is present in toxocariasis, conditioned by cellular infiltration, and a dense fibrous streak of vitreoretinal traction can be detected, extending from the central region to the periphery (Figure 6 – left), which represents a further differential diagnostic problem in relation to retinoblastoma.

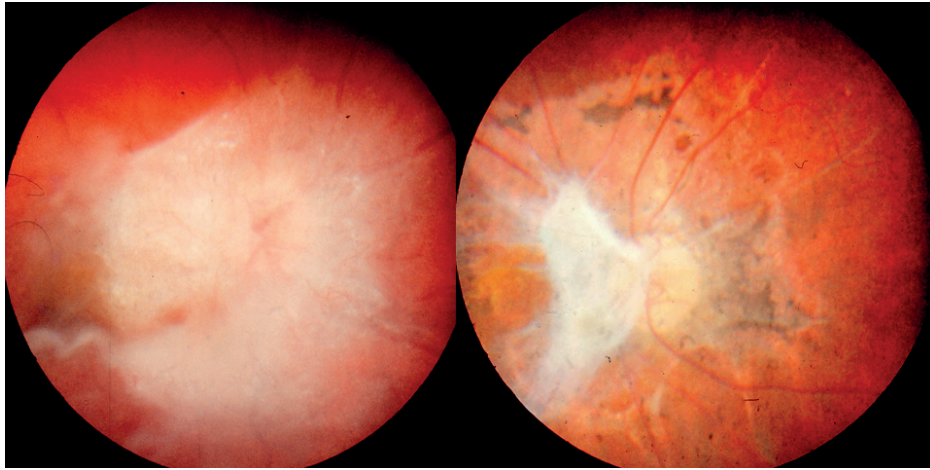


Figure 5. Left: Image of toxocara neuropathy with vitreoretinal reaction in the vicinity before general therapy

Right: Significant cicatricial retinal changes with optic nerve papillary atrophy and residues of vitreous membrane one year after combination treatment

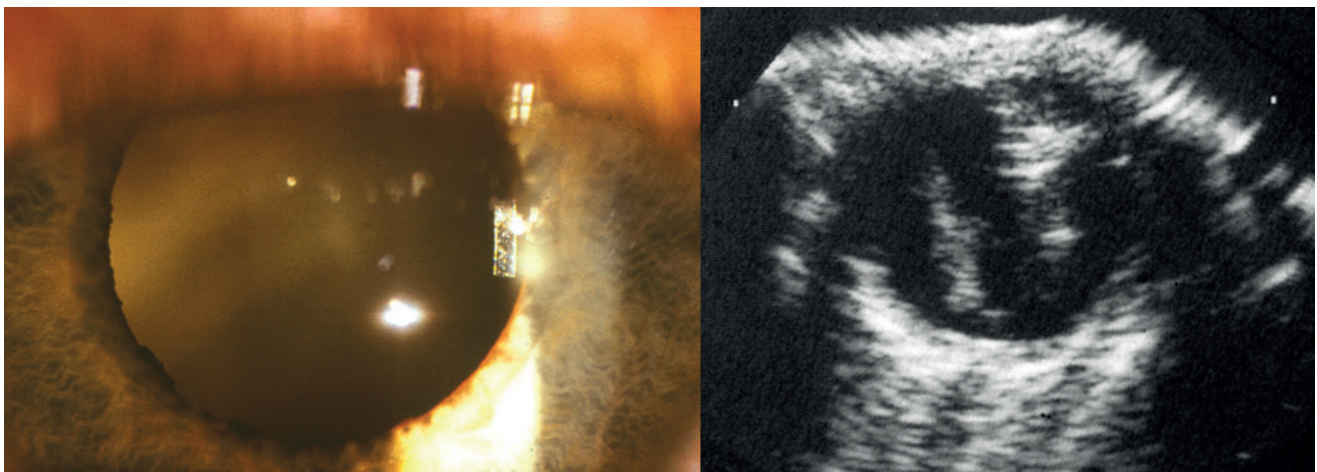


Figure 6. Left: Opacities of vitreous body of toxocara etiology visible retrolentally

Right: Ultrasound image of toxocara endophthalmitis with inflammatory conglomerates of the vitreous body and tractional streak running from the papilla to the periphery of retina

Diffuse chorioretinitis is considered as another possibility of OLT, despite the fact that this has not been convincingly identified. Its images include diffuse unilateral subacute neuroretinitis (DUSN), which usually leads to severe loss of sight, and in addition this infection may also have an impact on the other eye. Diffuse chorioretinitis or DUSN is rare, characterised by the form of individual small whitish-yellow lesions of the centre and central periphery (Figure 7), with potential edematous affliction of the optic nerve papilla. It is speculated that its cause may be subretinal meandering migration of larvae, with regard to isolated observations [6]. All indications are that it is caused by a sole unidentified worm, but to this day only a small number of roundworms have been determined in eyes afflicted by this condition [29]. As a result, mixed form of toxocariasis could apply here in the case of high levels of antibodies, in which an inflammatory reaction in the inte-

raocular tissues ensues from sensitisation of the host by larval antigens distributed through the bloodstream [1]. Bilateral affliction has also been documented in a ten-year-old Brazilian girl. Roundworms with a size of 500–660 μm were discovered in both eyes, in the superior and inferior temporal quadrant of the retina respectively [30].

Affliction of the anterior segment ranks among rare observations pertaining only to adult patients, since this has not been recorded in children. The passage of a larva via the arteries of the corneoscleral limbus into the clear cornea has been described [6], which may trigger scleritis and keratitis in the initial stages of the pathology [1]. A significant observation of a larva in the lens was made by the Czech professor Karel. The development of peripheral chorioretinal granuloma was described in the first phase of the pathology in a young woman, and it was only subsequently that a larva was observed several times in the re-

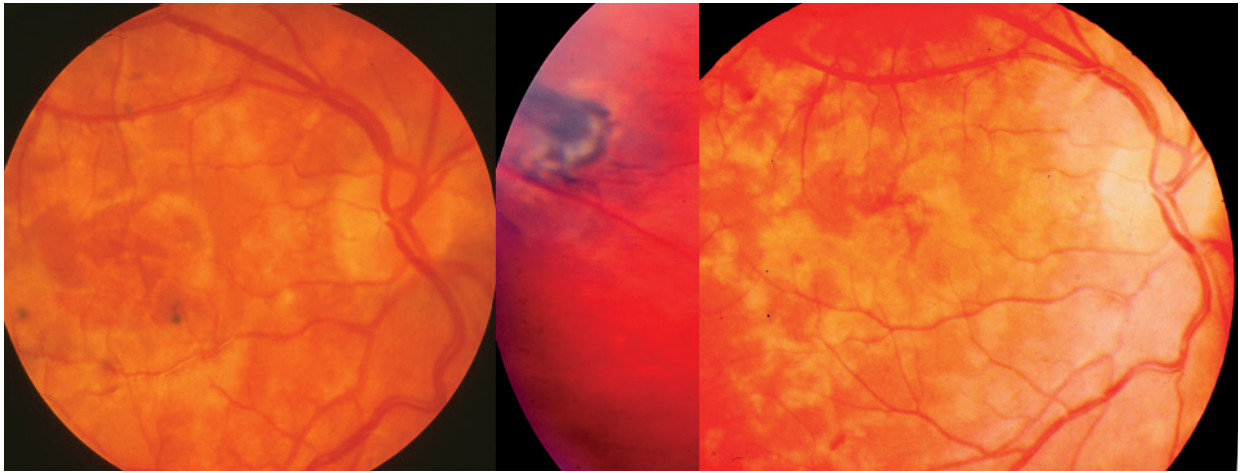


Figure 7. Left: Clinical picture of infiltration of the central region of the posterior pole of the eye upon DUSN toxocara etiology
Centre: Single chorioretinal scar v.s. after tapeworm on average 1 PD with pigment traction in the temporal periphery after combined treatment
Right: Mapped yellowish retinal scarring accompanied by partial optic nerve atrophy six months after combined therapy

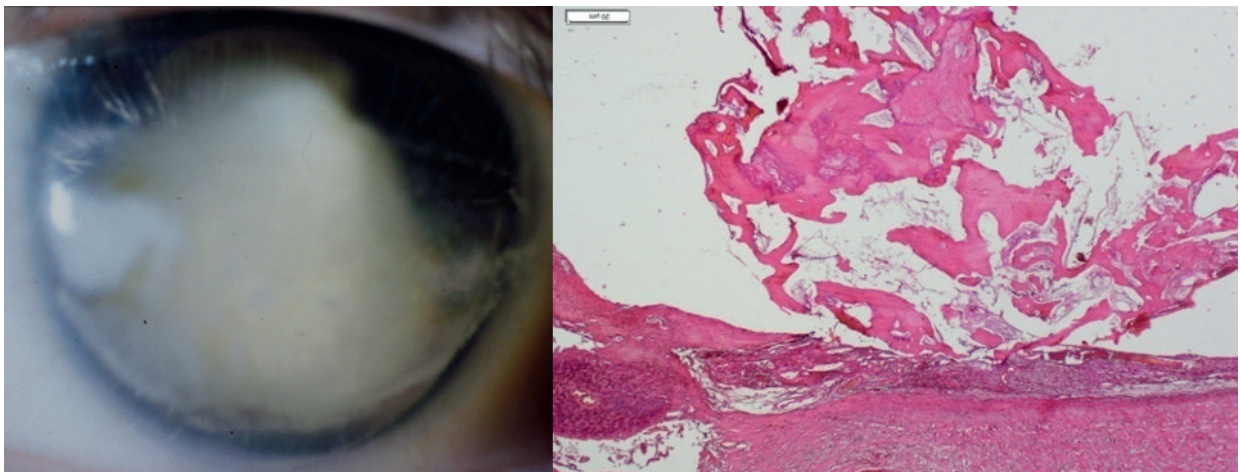


Figure 8. Left: Phthisis of bulbus after toxocara inflammation
Right: Ossified cyst after tapeworm in the choroid, HE, magnification 20x

gion of the pupil, beneath the anterior and posterior lens capsule, even despite intensive treatment with antihelminthics [31]. To date, no potential independent affliction of the conjunctiva has been demonstrated [6].

Differential diagnosis of OLT in children

In small children OLT represents a fundamentally significant differential diagnostic problem, simulating retinoblastoma. Further pathologies which have an image of leukocoria must be excluded: persistence of primary hyperplastic vitreous (PHPV) in 19% of cases, cicatricial form of retinopathy of prematurity in 13.5% and also congenital disorders of the posterior pole of the eye. These conditions include coloboma of the choroid and optic nerve in 11.5% of cases, Coats disease in 6% and Weve syndrome in 5.5%. Posterior uveitides are also of differential diagnostic significance in 16.5% of cases, of which OLT as a separate unit

constitutes 9% [32]. These pathologies continue to be a diagnostic problem [33]. Differential diagnosis [2,6,34,35]: The first two stated pathologies have their anamnesticly substantiated origin already at birth. PHPV is associated with a clinical picture of microphthalmia, frequently accompanied by cataract and above all retrolenticular masses, all of which should be diagnosed in the first months after birth. Cicatricial form of retinopathy of prematurity represents a bilateral pathology with a clear anamnesis of premature birth and postnatal care. In the case of both pathologies, US detects funnelled retinal detachment or fibrous streaks extending from the optic nerve papilla. Coats disease does not have vitreoretinal membranes in the clinical picture, the vitreous is clear, on the ocular fundus it is possible to detect crystals of cholesterol and potentially teleangiectasia. US detects subretinal exudation. Familial exudative vitreoretinopathy (Weve syndrome) is

characterised by a retinal falciform streak, similar to peripheral granuloma in OLT. This represents a bilateral autosomal dominant pathology, frequently accompanied by microphthalmia. The differentiation of this manifestation of OLT from retinoblastoma, the most common malignant ocular pathology in small children, is of fundamental importance. Here also US may be of assistance, since by contrast with retinoblastoma it does not confirm calcifications in toxocariasis, though their absence does not exclude the possibility of a tumour. As a result, toxocariasis still remains a masking diagnosis of this tumour, which is sometimes detected only histologically, following enucleation. OLT results in the formation of granulomas or eosinophilic pseudoabscesses, with the possibility of tractional retinal detachment accompanied by subretinal fluid. The retinal pigment epithelium atrophies, with breach of the Bruch's membrane [6]. It is only later that the remodelling of granulomas through their progressive fibrosis to calcification is manifested [36], which is confirmed by the finding from the enucleated eyeball due to phthisis (Figure 8 – left) generated by toxocara inflammation. Spherical ossification with a diameter of approx. 8 mm localised in the choroid, with polypoid prominence into the vitreous cavity in the originally formed inflammatory infiltrate (Figure 8 – right).

In differential diagnostics, examination of the chamber fluid may be of assistance, in retinoblastoma lactate dehydrogenase is detected [37], whereas in toxocariasis its antibodies are present [15,16].

Laboratory diagnosis of OLT

For confirmation of the diagnosis of toxocariasis, in the initial stages it was of decisive importance to detect and locate a larva in a fragment of tissue. It was not until as late as the 1970s that the use of serological diagnosis commenced, which used antigens prepared from adult worms but did not produce satisfactory results. Finally in 1975 De Savigny prepared an excretory-secretory antigen (ESA) produced by live larvae. This antigen was highly genus-specific and was used in an ELISA (enzyme-linked immunosorbent assay) reaction for individual forms of larval toxocariasis [1]. A titre of 1:8 is already sensitive for OLT [2,38] if the clinical ocular finding corresponds thereto, though on the other hand it is necessary to be aware that there is a 55–80% prevalence in the child population, which does not render this diagnosis entirely specific [6]. The antibody background in the population is stated within the range of 40–80%. A level of antibodies higher than 1:32 is now sensitive for detection of toxocariasis in 78% of cases [38]. The National Reference Laboratory for Tissue Helminthiasis at the IPME (Institute of Postgraduate Medical Education) in Prague compiled its own modification [13], in which the results are expressed by optic density, which is evaluated as negative up to 0.4, and within the range of 0.4–0.5 as borderline. Values of 0.5–0.9 are assessed as low positivity, 0.9–1.2 as medium and above 1.2 indicates high levels. At the same time, they use an avidity test (expressing the strength of the connection between the given serum sample and the multivalent antigen) of IgG in order to determine the probability of fresh infection in

the case of a low level, or infection of a longer-term duration in the case of a high level [7]. An integral component of the diagnosis is a comparison of levels of antibodies in serum and in intraocular fluids. The use of the "Goldmann-Witmer coefficient" (GWC) assists in the confirmation of OLT, since the formation of intraocular specific IgG antibodies is presumed. However, no systematic evaluation of GWC application exists in immunological diagnosis [39]. Positivity is assumed of at least 1.4 times for the level in the intraocular fluid in comparison with serum. Czech authors have demonstrated a similar level of IgG toxocara antibodies in serum and the vitreous body or higher. Furthermore they have recorded the presence of eosinophils in the vitreous body, by contrast with serum [16]. Slovak authors have confirmed the positivity of toxocara antibodies in the chamber fluid in fewer cases than positivity in serum [15], which did not exclude the possibility of mixed form [9]. A higher yield of the GWC has been demonstrated in children than in adults and may be useful if posterior uveitis or vitritis of unclear etiology is discovered in the patient. Serological screening is only of informative value for the actual diagnosis of this parasitic pathology [40]. High production of specific IgG antibodies within the framework of the GWC was in correlation with the production of non-specific IgE [39]. In children the diagnosis of larval toxocariasis was supported by a finding of higher eosinophilia and hypergammaglobulinaemia E. The younger the child, the higher the levels were [20]. It was precisely high eosinophilia that was in first place in indicating the possibility of diagnosing toxocariasis, out of 1000 examined patients it was present in one half, and only next in order were allergic illnesses and secondary reactions to medications [41]. A correlation between high eosinophilia and positivity of toxocara IgG antibodies by the ELISA method confirmed their high statistically significant representation in contrast with absent pathological eosinophilia [42]. In patients with eosinophilia above 10%, toxocara IgG antibodies were positive in 30% of cases using the ELISA method, whereas using the western blot method they were positive in practically 50% [43]. For the diagnosis of OLT, a significant role is played by the clinical experience of the ophthalmologists, but this must always be supported by auxiliary diagnostic methods [19]. In affected adult patients the presence of eosinophilia aided the diagnosis, and in ELISA only anamnestic values of IgG were present, with verified anamnestic data on the ingestion of raw meat [27]. In an adult woman following ingestion of raw meat, an edema of the optic nerve papilla was also detected due to a deterioration of vision, with a cystic lesion with peripapillary serous retinal detachment. Eosinophilia and serum positivity of IgG assisted in confirming toxocara etiology [28].

Treatment of OLT

OLT can be treated conservatively or surgically, depending on the severity of the intraocular inflammation. Medicamentous therapy is the first choice for the treatment of an active inflammation, according to the current standard by corticosteroids. These serve for reducing vitreous opacities and the formation of membranes. The role of antihel-

minthic therapy for OLT remains controversial, because no randomised controlled trials have been conducted on the use of antihelminthic substances, either intraocular pharmacokinetic or pharmacodynamic. Studies for systemic toxocariasis are used as the basis. The foundation of treatment constitutes benzimidazole derivatives. Albendazole (20 mg/kg/day) is administered for a period of 1 to 2 weeks, which strongly inhibits the migration of larvae. In general, albendazole is administered for the treatment of OLT in a dose of 400 mg twice per day for children, and 800 mg for adults [17,38], for a period of up to 3 weeks. Albendazole appears to be more effective than thiabendazole (50 mg/kg/day), which is recommended only for a period of 3–7 days [38]. Furthermore, albendazole is the only antihelminthic drug that acts against all the developmental stages of roundworms (egg, larva and adult worm). The mechanism of effect presupposes the degeneration of microtubules of the intestinal cells of worms, and simultaneously reduces the formation of ATP (adenosine triphosphate), by which it exhausts energy and reduces their motility. It thereby also kills adult roundworms. Thiabendazole inhibits fumarate reductase, which reduces the absorption of glucose. Fumarase is a terminal acceptor in the metabolism of roundworms, but not in mammals [44]. The role of antihelminthic therapy alone on OLT remains unclear, since it has not been demonstrated that it could kill larvae by itself. Furthermore, clinical results have demonstrated that combined therapy of generally administered antihelminthics and corticosteroids is more successful than therapy by corticosteroids alone, since it reduced the incidence of recurrence of inflammation. The two therapeutic procedures did not differ in their impact on improvement of vision. The fact that the death and breakdown of the larva may trigger a subsequent inflammatory reaction, which is suppressed by corticosteroids, is an argument in favour of the concurrent use of corticosteroids [38]. The success of diagnosis and treatment has been confirmed by a decrease in the level of toxocara IgG antibodies (ELISA) in serum [45]. By contrast, persistent higher titres of IgG indicated ineffective treatment of concurrent infection, requiring a change thereof [21]. In the case of positivity of the IgE level and its monitoring, it was possible during the course of treatment to point to a therapeutic effect in the case of a decrease [38]. A positive response to treatment with antihelminthic drugs was accompanied by a reduction of eosinophilia, which confirmed the diagnosis of toxocariasis [41]. Combined treatment with systemic corticosteroids and an antihelminthic drug produced a definite improvement of VA and the clinical intraocular finding upon affliction of the optic nerve [28]. Despite the fact that no standardised parameters of the dose, duration and method of administration exist, the majority of authors prefer combined therapy [19]. Localisations of OLT granuloma in the periphery and on the posterior pole could be influenced by treatment. Baseline VA was always better in the case of peripheral granuloma, but after treatment there was no significant difference between both localisations of the inflammation [44]. The role of medicamentous therapy has its limits. Retinal detachment, epiretinal membranes and persistent vitreous

opacities are indications for PPV, which applies above all in the case of adult patients. The greatest effectiveness was achieved in the case of vitreous opacities, and the least in the case of retinal detachment. PPV nevertheless brought about a stabilisation of visual function [38], sometimes also an improvement thereof upon the removal of inflammatory agents in the vitreous and verification of the diagnosis by analysis of the vitreous for toxocara antibodies [16]. The majority of operators incline towards leaving the granuloma in place, since it is generally firmly attached to the retina and its removal could cause damage thereto [16]. Overall, a surgical procedure individually helped [19] in approximately one half of cases, also in macular traction [46]. A larva localised subretinally was liquidated with the aid of an argon laser in the case of DUSN [30], and intravitreally applied ranibizumab was effective in the treatment of secondary neovascularisation in OLT [47]. Both therapeutic procedures were applied in children aged around ten years.

Prevention

In a situation where there is insufficient knowledge concerning OLT, it is important for the prevention of this pathology to raise the public awareness regarding toxocariasis, and thereby bring about a reduction of the possibility of exposure thereto in humans. In order to reduce the risk of infection, it is above all necessary to understand the source of transmission. Direct contact with untreated infected puppies was previously considered an important source of transmission, but with regard to the percentage affliction of dogs by toxocariasis this has not been sufficiently explained. By contrast, accidental ingestion of eggs within geophagia is of fundamental significance for toxocariasis in children. It is therefore hugely important to ensure the prevention of the possibility of ingesting eggs or larvae. Good hygiene, as well as washing and wiping of hands before eating in exposed locations are important. This applies to sandpits, outside playgrounds and parks, which may be contaminated. Fencing off of children's playgrounds and sandpits also helps prevent the possibility of contamination if dog owners respect such regulations, in addition to which they should clean up their pets' excrement. In adult patients the main risk is represented by insufficiently cooked meat and consumption of raw beef, above all liver.

CONCLUSION

In addition to the aforementioned comprehensive clinical analysis of the issue in question, the main emphasis of this communication is placed on the photographic documentation of clinical findings of OLT of the posterior pole of the eye only in children. Individual clinical pictures indicate the variety of intraocular manifestations of this parasitic infection. In differential diagnostics, manifestations of OLT in small children continue to be connected primarily with retinoblastoma. Treatment is arduous and does not always produce a desirable effect. As a consequence, prevention of the possibility of ingestion of eggs or larvae, leading to the formation of granulomas, is of the utmost importance.

REFERENCES

- Uhlíková M, Hübner J, Leissová M. Oční forma larvální toxokarózy v České republice. [Form of ocular larval toxocarosis in Czech Republic]. *Cesk Slov Oftalmol.* 2002;58:75-83. Czech.
- Wright KW, Spiegel PH. *Pediatric Ophthalmology and Strabismus*, 2nd ed. New York (USA). Springer; 2003; Rao, N.A.: Uveitis in Children. Chapter 29. pp.499-522.
- Wilder HC. Nematodes endophthalmitis. *Trans Am Acad Ophthalmol Otolaryngol.* 1950;55: 99–109.
- Beaver C, Snyder CH, Carrera GM, et al. Chronic eosinophilia due to visceral larva migrans. *Pediatrics.* 1959;9:7-19.
- Nichols RL. The etiology of visceral larva migrans. *J Parasitol.* 1956;42:349-362.
- Pepose JS, Holland GN, Wilhelmus KR. *Ocular Infection and Immunity*. St. Louis (USA). Mosby; 1996; Parke DW, Shaver RP. Toxocarosis. Chapter 86. pp.1225-1235.
- Divišová G, Kadlecová V, Lomičková H, Brůnová B. Dětské uveitidy. [Childhood uveitis]. *Cesk Oftalmol.* 1967;23: 86-94. Czech.
- Karel I, Peleška M. Fluoroangiografický obraz pravděpodobné toxokarové granulomatózní chorioretinitidy. [The fluoroangiographic picture in likely granulomatous chorioretinitis of toxocarosis]. *Cesk Oftalmol.* 1972;28:276-231. Czech.
- Uhlíková M, Hübner J. Možnosti výskytu onemocnění visceral larva migrans v Československu. [Possibility of occurrence of Visceral larva migrans disease in Czechoslovakia]. *Cesk Pediatr.* 1968;23:715-718. Czech.
- Valníčková J, Kouba K, Uhlíková M, et al. Centrální retinitida pravděpodobně toxokarové etiologie. [Retinitis centralis likely etiology toxocarosis]. *Cesk Oftalmol.* 1975;31:209-212. Czech.
- Hübner J, Uhlíková M, Leissová M. Diagnostika časné fáze larvální toxokarózy využitím avidity IgG [Diagnosis of early phase of larval toxocarosis with application of avidity IgG]. *Epidemiol Mikrobiol Imunol.* 2001;50:67-70. Czech.
- Uhlíková M, Hübner J, Kolářová L, Poláčková M. Immunological studies on human larval toxocarosis. *Centr Eur J Publ Hlth.* 1996;4:242-245.
- Uhlíková M, Hübner J. Seroprevalence of *Toxocara canis* infection in Czech Republic. *Centr Eur J Publ Hlth.* 1998;6:195-198.
- Uhlíková M, Hübner J. Larvální toxokaróza – klinika, diagnostika a léčba nemoci [Larval toxocarosis – clinic, diagnosis and therapy of disease]. *Remedia – Clinic mikrobiology.* 1999; 3:255-259. Czech.
- Kostolná B, Gerinec A, Ondříška F. Diagnostika toxoplasmózy a toxokarózy z moku prednej očnéj komory. [Diagnosis toxoplasmosis and toxocarosis from a humour of anterior chamber]. *Cesk Slov Oftalmol.* 2003;59:312-318. Slovak.
- Šišková A, Říhová E, Skalická P, et al. Význam pars plana vitrektomie v diagnostice oční toxokarózy. [Importance of pars plana vitrectomy in diagnosis of ocular toxocarosis]. *Cesk Slov Oftalmol.* 2003;59:304-311. Czech.
- Říhová E, et al. Uveitidy [Uveitides]. Praha (Czech Republic), Grada; 2009. Chapter 2, 17. Kontur-Šišková A. Toxokaróza, pp.38-40. Czech
- Good B, Holland CV, Taylor MR, et al. Ocular toxocarosis on school children. *Clin Infect Dis.* 2004;39:173-178.
- Martinez-Pulgarin DF, Muñoz-Urbano M, Gomez-Sula LD, et al. Ocular toxocarosis: new diagnostic and therapeutic perspectives. *Recent Pat Antiinfect Drug Discov* 2015;10:35-41.
- Mazur-Melewska K, Mania A, Figlerowicz M, et al. The influence of age on a clinical presentation of *Toxocara* spp. infection in children. *Ann Environ Med.* 2012; 19:233-236.
- Hogan MJ, Kimura SJ, Spencer WH. Visceral larva migrans and periferic retinitis. *J Am Med Assoc.* 1965;194:1346-1347.
- Krásný J. Granulomatózní uveitidy toxokarové etiologie. [Granulomatous uveitis by etiology of toxocarosis]. Volume of abstracts XI. Symposium of pediatric ophthalmology; ISBN 978-80-89797-00-4, Bratislava, 2015:5.
- Duguid IM. Features of ocular manifestation by toxocara. *Br J Ophthalmol.* 1961;45:789-796.
- Wisniewska-Ligier M, Woznakowska-Gesicka T, Sobolewska-Dryjanska J, et al. Analysis of the course and treatment of toxocarosis in children, a long-term observation. *Parasitol Res.* 2012; 110:2363-2371.
- Urban B, Bakunowicz-Lazarczyk A, Michal S. Clinical features, the effectiveness of treatment and function of vision organ in children and adolescents with ocular toxocarosis. *Klin Oczna.* 2008;110:364-366. Polish.
- Morais FB, Maciel AL, Arantes TE, et al. Ultrasonographic findings in ocular toxocarosis. *Arg Brasil Oftalmol.* 2012;75:43-47.
- Choi K-D, Choi J-H, Choi S-Y, Kung JH. Toxocara optic neuropathy: clinical features and ocular findings. *Int J Ophthalmol.* 2018;11:520-523.
- Kim YJ, Moon CH, Chang JH. Toxocarosis of the optic disc. *J Neuroophthalmol.* 2013; 33:151-152.
- Sabrosa NA, de Souza EC. Neomade infection of the eye: toxocarosis and diffuse unilateral subacute neuroretinitis. *Curr Opin Ophthalmol.* 2001;12:450-454.
- de Souza EC, Abujamra S, Nakashima Y, Gass JD. Diffuse bilateral subacute neuretinis: first patients with documented nematodes in both eyes. *Arch Ophthalmol.* 1999;17:1349-351.
- Karel I, Peleška M., Uhlíková M, Hübner J. Larva migrans lentis. *Ophthalmologica.* 1977;174:14-20.
- Howard GH, Ellsworth RM. Differential diagnosis in retinoblastoma. A statistical survey of 500 children. Relative frequency of lesions simulate retinoblastoma. *Amer J Ophthalmol.* 1965;60:610-622.
- Shields JA. Ocular toxocarosis. *Surv Ophthalmol.* 1984;28:361-381.
- Harley RD. *Pediatric Ophthalmology*, 2nd ed. Philadelphia (USA):W.B.Sauders comp.; 1983; Volume II. pp.767-1402.
- Wright KW, Spiegel PH. *Pediatric Ophthalmology and Strabismus*, 2nd ed. New York (USA). Springer; 2003; Murphree AL, Christensen LE. Retinoblastoma and Malignant Intraocular Tumors. Chapter 35. pp.584-599.
- Šach J, Krásný J. Ocular toxocarosis. Protocol of 51st Annual Meeting of EOPS (European Ophthalmic Pathology Society), London; 2012.
- Řehůřek J. Aktivita laktodehydrogenázy v diagnostice retinoblastomu [Lactate dehydrogenase activity in the diagnosis of retinoblastoma]. *Cesk Slov Oftalmol.* 1995;51:14-18. Czech.
- Ahn SJ, Ryoo NK, Woo SJ. Ocular toxocarosis: clial features, diagnosis, treatment, and prevention. *Asia Pac Alergy.* 2014;4:134-141.
- Wang ZJ, Zhou M, Cao WJ et al. Evaluation of the Goldmann-Witmer coefficient in the immunological diagnosis of ocular toxocarosis. *Acta Trop.* 2016;158:20-23.
- Bae KW, Ahn SJ, Park KH, Woo SJ. Diagnostic value of the serum anti-Toxocara IgG titer for ocular toxocarosis in patients with uveitis at a tertiary hospital in Korea. *Korean J Ophthalmol.* 2016;30:258-264.
- Yoon SY, Baek S, Park SY, et al. Clinical course and treatment outcome of toxocarosis-related eosinophilic disorder. *Medicine.* 2018;97: e12361 doi 10.1097
- Karadam SY, Ertug S, Ertabaklar H, Okyay P. The comparison of IgG antibodies specific to *Toxocara* spp. among eosinophilic and non-eosinophilic groups. *New Microbiol.* 2008;31: 113-116.
- Artinyan E, Uysal HK, Akgul O, et al. Research on *Toxocara canis* antibodies obtained from patients with eosinophilia. *Indian J Med Microbiol.* 2014;32:383-86.
- Kalant H, Roschlau WEH. *Principes of Medical Pharmacology*, Oxford (Great Britain) Oxford University Press; 1998; Keystone JS. Chemotherapy of common parasitic infection. Chapter 21. pp.712-728.
- Kwon JW, Lee SY, Jee D, Cho YK. Prognosis for ocular toxocarosis according to granuloma location. *PLoS One*, 2018; 13: doi: 10.1371/journal. PLOS
- Amin HI, McDonald HR, Han DP, et al. Vitrectomy update for macular traction in ocular toxocarosis. *Retina.* 2000;20:80-85.
- Lyall DA, Hutchinson BM, Gaskell A, Varikara M. Intravitreal Ranibizumab in the treatment of chorioidal neovascularisation secondary to ocular toxocarosis. *Eye.* 2010;24: 1730-1731.