

TUBE VERSUS TRABECULECTOMY IN JUVENILE-ONSET OPEN ANGLE GLAUCOMA – TREATMENT OUTCOMES IN TERTIARY HOSPITALS IN MALAYSIA

Abd Hadi MR.^{1,2,3}, Ang WJ.¹, Raja Norliza RO.¹, Norhalwani H.⁴, Azhany Y.^{2,3}, Liza-Sharmini AT.^{2,3}

¹Department of Ophthalmology, Hospital Melaka, Melaka

²Department of Ophthalmology and Visual Sciences, School of Medical Sciences, Health Campus, Universiti Sains Malaysia, Kota Bharu, Kelantan

³Eye Clinic, Hospital Universiti Sains Malaysia, Kota Bharu, Kelantan

⁴Department of Ophthalmology, Hospital Raja Perempuan Zainab II, Kota Bharu, Kelantan

The authors of the study declare that no conflict of interest exists in the compilation, theme and subsequent publication of this professional communication, and that it is not supported by any pharmaceutical company.

Source of funding:

This research received no specific grant from any funding agency in the public, commercial, or not-for-profit sectors.

Received: 11 July 2022

Accepted: 15 October 2022



First author:

Dr Abd Hadi Bin Mohd Rasidin

Corresponding author:

Professor Dr Liza-Sharmini

Ahmad Tajudin

Department of Ophthalmology
and Visual Science

School of Medical Sciences

Health Campus, Universiti Sains
Malaysia

Jalan Raja Perempuan Zainab 2

16150 Kota Bharu, Kelantan

Email:

liza@usm.my; sharminiliz@live.com

SUMMARY

Aim of the study: To compare the intraocular pressure (IOP) lowering effect and postoperative complications between primary augmented trabeculectomy and glaucoma drainage device (GDD) implantation as primary surgical intervention in patients with juvenile-onset open angle glaucoma (JOAG).

Patients and Methods: A retrospective review study involving 20 eyes that underwent primary augmented trabeculectomy with mitomycin (MMC) and 10 eyes GDD implantation in 3 tertiary centres in Malaysia between 1 January 2013 and 31 December 2019. They were followed up for at least 12 months postsurgical intervention. Intraocular pressure (IOP), number of topical IOP lowering medication and complications were evaluated at 1, 3, 6 and 12 months post-intervention. Based on the IOP, the success was divided into complete and partial success, and failure. IOP and postsurgical complications were compared using the Repetitive Measure Analysis of Variance (RM ANOVA) and the Pearson chi-square test.

Results: Both methods were effective in lowering the IOP. Eyes with primary augmented trabeculectomy have significant lower IOP compared to GDD implantation ($p = 0.037$). There was a higher incidence of postoperative hypotony (30%) in the trabeculectomy group. There was also a significant reduction of mean number of topical pressure-lowering drugs required postoperatively ($p = 0.015$). Complete success was achieved in 100% of eyes with trabeculectomy and 67% in GDD implantation ($p = 0.047$).

Conclusions: Primary augmented trabeculectomy and GDD implantation are good surgical options for the treatment of JOAG. Both methods provide IOP lowering at 1 year. However, trabeculectomy provides better pressure lowering, compared to GDD implantation in patients with JOAG.

Keywords: juvenile-onset open angle glaucoma, augmented trabeculectomy, glaucoma drainage device

Čes. a slov. Oftal., 78, 2022, No. 6, p. 298–303

INTRODUCTION

Juvenile-onset open angle glaucoma (JOAG) is characterised by high intraocular pressure (IOP), retinal nerve fibre layer (RNFL) and optic nerve head changes and a co-

responding rapid progression of visual field, which develops at a young age (between the ages of 5 and 35 years) [1]. There is a strong association with a family history of glaucoma [1]. However, genetic inheritance is non-specific but autosomal dominant inheritance is commonly

observed [2]. Management of JOAG is challenging; often medical treatment is not effective. Surgical intervention is preferred as first-line management [3].

Augmented trabeculectomy is the most common and popular mode of surgical intervention. The success rate has been reported as between 50–87% among patients with JOAG [1]. Conjunctival scarring and vision-threatening complications, including hypotony maculopathy and bleb-related infection affect the long-term success of trabeculectomy [4]. Glaucoma drainage device (GDD) implantation has gained popularity due to the nature of JOAG that requires long-term and more sustainable IOP control. GDD implantation, such as the Ahmed valve and Baerveldt, has been the popular option for glaucoma in the pediatric age group [5]. GDD implantation reduces the lifelong risk for endophthalmitis and a success rate of 63–100% among various age groups has been reported [6].

However, there is no comparative study to compare the pressure-lowering effect of these two modes of surgical intervention to guide the clinical decision. The objective of the present study was to compare the 12-month IOP lowering effect and postoperative complications between augmented trabeculectomy with mitomycin C (MMC) and GDD implantation as primary surgical intervention in patients with JOAG.

MATERIAL AND METHODS

A retrospective comparative record review study was conducted involving 24 patients with JOAG (30 eyes) seen in 3 tertiary hospitals in Malaysia: Hospital Melaka, Hospital Universiti Sains Malaysia, and Hospital Raja Perempuan Zainab II. This study received ethical approval from the Malaysia Ethical Research Committee and is registered in the National Medical Research Registry (NMRR). This study was conducted in accordance with the Declaration of Helsinki for human research.

Patients with JOAG were identified from the ophthalmic surgical database of all three hospitals. The inclusion criteria included those who were diagnosed with JOAG based on the European Glaucoma Society Guideline: high IOP, structural and functional changes of glaucoma, which developed at the onset between 10 and 35 years of age [7]. Patients with secondary glaucoma and congenital glaucoma were excluded. Those who underwent glaucoma filtration surgery between 1 January 2013 and 31 December 2019 were included in this study. Post-surgery, selected patients had to complete at least 1 year of follow-up between 1 January 2014 and 31 December 2020. Primary augmented trabeculectomy and GDD implantation were conducted under general or local anesthesia by glaucoma specialists in the respective hospitals.

Primary augmented trabeculectomy

A total of 20 eyes were subjected to primary augmented trabeculectomy. A fornix-based conjunctival flap was adopted in all cases. The partial thickness rectangular

scleral flap was between 3–4 mm in size. Mitomycin-C 0.4 mg/l was applied to a small sponge and placed posteriorly to the scleral flap for 2 to 3 minutes. Copious irrigation with 60ml of balance salt solution (BSS) was performed. Paracentesis was then performed and followed by sclerotomy, using a Kelly Descemet punch. Peripheral iridectomy was then performed. The scleral flap was then sutured with 10/0 nylon sutures with or without releasable suture. The fornix-based conjunctival flap was then anchored to the limbus with nylon 10/0 sutures.

Glaucoma drainage device implantation

The Ahmed glaucoma valve (AGV) model FP7 (New World Medical Inc, country) and Baerveldt glaucoma implant (BGI) model (Advanced Medical Optics, Santa Ana, California, USA) were used in this study. A superotemporal 4–5 clock-hour conjunctival peritomy was created and the space between Tenon's capsule and the sclera carefully dissected. A small sponge soaked with MMC 0.4 mg/l was placed at the proposed body implant site 8–10 mm from the limbus for 2–3 minutes, followed by copious irrigation with BSS. After priming the implant with BSS, a 7/0 polyglactin suture was used to ligate the silicon tube of BGI approximately 2 mm proximally to the plate. Lateral and superior rectus muscles were isolated with muscle hooks; the wings of the plate were placed under the muscles and the central part of the plate was sutured to the underlying sclera with a 9–0 nylon suture. After dissection of the tenon, the body of the implant was positioned 8–10 mm from the limbus, outside the limbal healing space. The plate (AGV and BGI) was then sutured to the sclera with a 10/0 nylon suture. The drainage tube was trimmed to permit a 2–3 mm insertion in the anterior chamber (AC) and was bevel-cut to an angle of 30° to facilitate AC entry. Prior to insertion, a paracentesis was created. The AC was then entered 1–3 mm posteriorly to the corneoscleral limbus with a 23G needle forming a needle track. The tube was inserted into the AC through the needle tract and placed well, without any contact with the iris or corneal endothelium. The tube was anchored to the sclera through a criss-cross suture using 10/0 nylon suture. The drainage tube (either AGV or BGI) was covered with a piece of preserved, donor sclera, which was sutured to the host sclera, using 10/0 nylon suture. Subconjunctival antibiotic and steroid were then injected at the 6 o'clock position.

Postoperative management

All topical pressure-lowering drugs were discontinued postoperatively for both primary augmented trabeculectomy and GDD implantation. Topical moxifloxacin and prednisolone acetate 1% were given at 2-hourly intervals for 24 hours. If there was no contraindication, such as hypotony, topical moxifloxacin was then continued in tapering frequency until 2 months postoperatively, while topical prednisolone acetate 1% was then tapered in frequency until 4–6 months postoperatively. They were followed up at 1 week then at 1, 3, 6 and 12 months postoperatively, but with more frequent visits for patients who developed

complications. During each follow-up, bleb configuration was assessed using the Indiana bleb appearance grading scale [8]. Bleb leak is defined as the presence of a positive Siedel test at any area adjacent to the bleb. Anterior segment assessment includes anterior depth, reaction and hyphaema. Hypotony is defined as IOP less than 6 mmHg [9]. Hypertony is defined as IOP more than 21 mmHg [9]. Other complications, such as choroidal effusion, cataract, rectus muscle entrapment and endophthalmitis were also documented. At the end of 12 months' follow-up, the success of these surgical interventions was divided into complete success: IOP < 21 mmHg without any medication; qualified success: those who had 2 medications added to achieve IOP < 21 mmHg; and failure: IOP > 21 mmHg with maximum medical treatment. The number of pressure-lowering agents was also compared at 12 months postoperatively to preoperatively.

Statistical analysis

Demographic, ocular parameters, surgical and postoperative data were entered into SPSS 22.0. All data were checked, and missing data were retrieved. The independent t test was adopted for numerical data with normal distribution, chi-square and Fischer-exact tests were used to analyse categorical data. Repetitive measure analysis of variance (RM ANOVA) was used to compare mean IOP during preoperative and postoperative follow-up between the two groups. Further analysis with Bonferroni correction was conducted. $P < 0.05$ is deemed to be a statistically significant difference.

RESULTS

Primary augmented trabeculectomy was conducted on 20 eyes and GDD was implanted in 10 eyes of patients

with JOAG (Table 1). There was a statistically significant higher number of primary augmented trabeculectomy (90.1%) conducted on women with JOAG, compared to GDD implantation (9.1%) ($p = 0.049$). GDD was implanted in those who were older [27.8 (6.3) years old] and diagnosed longer [112(172) weeks], but without significant difference, compared to those who had primary augmented trabeculectomy (Table 1).

There was no significant difference in mean preoperative IOP between primary augmented trabeculectomy and GDD implantation (Table 2). Based on RM ANOVA, there was a statistically significant difference of mean IOP between primary augmented trabeculectomy and GDD implantation preoperatively, and at 1 month, 3 months, 6 months and 12 months postoperatively ($p = 0.037$) (Graph 1). In general, lower IOP was observed in patients with primary augmented trabeculectomy (Table 2 and Graph 1). Patients who had primary augmented trabeculectomy showed significant lower IOP at 1, 3, 6 and 12 months postoperatively, compared to GDD implantation (Table 2). At 1 month postoperatively, mean IOP of eyes with GDD implantation is almost double than those in the group with primary augmented trabeculectomy. On further analysis using RM ANOVA with Bonferroni correction, the significant difference of mean IOP ($p < 0.001$) was seen between preoperative and postoperative at 1, 3, 6, and 12 months, but not with other pairing (Table 3).

Complete success was achieved in all patients who had primary augmented trabeculectomy (20 eyes), but only in 7 patients with GDD implantation (67%) at 12 months in the postoperative period. Primary augmented trabeculectomy achieved a significant higher percentage of complete success compared to GDD implantation in this cohort of patients with JOAG ($p = 0.010$) (Table 2). Both surgical interventions showed a significant reduction of mean number of topical pressure-lowering agents.

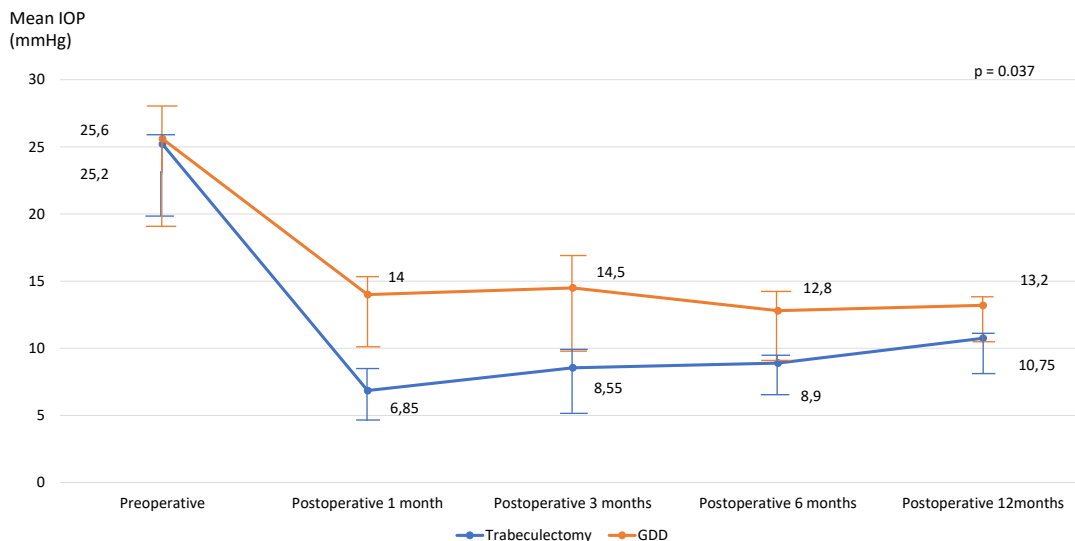
Table 1. Comparison of demographic data of patients with JOAG between primary augmented trabeculectomy and GDD implantation

Variables	Type of surgical intervention		p-value
	Trabeculectomy N=20	GDD implantation N=10	
Age (year) Mean (SD)	26.8 (6.0)	27.8 (6.3)	0.675 ^a
Sex (n, %)			
Male	10 (52.6%)	9 (47.4%)	0.049 ^b
Female	10 (90.9%)	1 (9.1%)	
Race (n, %)			
Malay	20 (100%)	8 (80.0%)	0.103 ^b
Others	0 (0.0%)	2 (20.0%)	
Mean Duration of diagnosis (weeks)	32 (46)	112 (172)	0.057 ^a
Laterality			
Right eye	12 (75.0%)	4 (25.0%)	0.442 ^b
Left eye	8 (57.1%)	6 (42.9%)	

^a $p < 0.05$ is considered statistically significant based on Independent T-Test

^b $p < 0.05$ is considered statistically significant based on Fisher's Exact Test

JOAG – Juvenile Open Angle Glaucoma, GDD – Glaucoma Drainage Device



Graph 1. Mean IOP changes pre and postoperatively between trabeculectomy and GDD implantation $p < 0.05$ is considered statistically significant based on RM ANOVA
 GDD – Glaucoma Drainage Device, IOP – Intraocular pressure, RM ANOVA – Repeated measure Analysis of Variance

Table 2. Comparison of mean IOP, number of IOP lowering agents, complications, and success rate between primary augmented trabeculectomy and GDD implantation in patients with JOAG

	Type of surgical intervention		p-value
Variables	Trabeculectomy N=20	GDD implantation N=10	
Mean Preoperative IOP (mmHg)	25.2 (4.6)	25.6 (10.9)	0.888 ^a
Mean Postoperative IOP (mmHg)			
1 month	6.85 (2.47)	14.0 (5.84)	<0.001 ^a
3 months	8.55 (3.76)	14.5 (8.16)	0.010 ^a
6 months	8.90 (3.07)	12.8 (6.17)	0.027 ^a
12 months	10.75 (3.02)	13.2 (2.48)	0.035 ^a
Mean number IOP lowering agents			
Preoperative	4.00 (0.00)	3.90 (0.00)	0.161 ^a
Postoperative	0.00 (0.00)	0.80 (1.39)	0.015 ^a
Postoperative complications (n, %)			
Hypotony	6 (30%)	1 (10.0%)	0.162 ^b
Cataract	-	1 (10.0%)	
Rectus muscle entrapment	-	1 (10.0%)	
Postoperative complications according to follow-up (n, %)			
1 month	Hypotony (3, 15.0%)	Muscle entrapment (1, 10.0%)	
3 months	Hypotony (2, 10.0%)	-	
6 months	Hypotony (1, 5.0%)	Hypotony (1, 10.0%)	
12 months	-	Cataract (1, 10.0%)	
Success rates (n, %)			
Complete success	20, 100%	7, 67%	0.010 ^b
Qualified success	0, 0%	3, 43%	
Failure	0, 0%	0, 0%	

^a $p < 0.05$ is considered statistically significant based on Independent T-Test

^b $p < 0.05$ is considered statistically significant based on Chi-Square Test

JOAG – Juvenile Open Angle Glaucoma, GDD – Glaucoma Drainage Device, IOP – Intraocular pressure

Table 3. Pairwise comparison of pre and postoperative IOP changes between primary augmented trabeculectomy and GDD implantation in patients with JOAG

IOP comparison	Mean difference	Standard error	95% CI		p-value
			Lower border	Upper border	
Baseline-1 month	14.97	1.493	10.42	19.52	<0.001
Baseline-3 months	13.87	1.329	9.82	17.92	<0.001
Baseline-6 months	14.55	1.349	10.44	18.65	<0.001
Baseline-12 months	13.42	1.424	9.08	17.76	<0.001
1 month-3 months	-1.10	1.285	-5.01	2.81	1.000
1 month-6 months	-0.42	1.165	-3.97	3.12	1.000
1 month-12 months	-1.55	0.861	-4.17	1.07	0.826
3 months-6 months	0.675	0.883	-2.01	3.367	1.000
3 months-12 months	-0.450	1.090	-3.77	2.87	1.000
6 months-12months	-1.12	0.856	-3.73	1.48	1.000

p < 0.05 is considered statistically significant based on RM ANOVA with Bonferroni correction

JOAG – Juvenile Open Angle Glaucoma; GDD – Glaucoma Drainage Device

IOP – Intraocular pressure, RM ANOVA – Repeated measure Analysis of Variance

Primary augmented trabeculectomy is associated with a significant reduction of lowering agents compared to GDD implantation ($p = 0.015$) (Table 2). However, primary augmented trabeculectomy is associated with a higher incidence of hypotony, especially at 1 month postoperatively. Rectus muscle entrapment and cataract are observed in eyes with GDD implantation (Table 2). Cataract is detected at 6 months post-GDD implantation, while none is detected in primary augmented trabeculectomy.

DISCUSSION

Ideally IOP management in patients with JOAG requires a lifelong sustainable reduction. Topical pressure-lowering drugs are usually prescribed as temporary treatment prior to surgical intervention in this group of patients [1]. Since medical therapy is often not effective, JOAG is regarded as refractory glaucoma, and GDD implantation is considered as the definitive treatment [10]. Traditionally, primary augmented trabeculectomy is the surgical intervention of choice for patients with JOAG [1]. The question is which of these interventions is effective as primary surgical intervention for patients with JOAG.

In the present study, both GDD implantation and trabeculectomy showed a reduction of IOP after 12 months post-intervention. Primary augmented trabeculectomy showed significant lower IOP reduction compared to GDD implantation, especially at 1 month postoperatively. Trabeculectomy provided better sustainable IOP reduction over 12 months of follow-up and achieved complete success in all patients with JOAG. In the previous study, GDD implants succeeded in 90.7% of cases for lowering the IOP less than 21 mm Hg at 1 year [11]. Primary trabeculectomy in patients with JOAG showed a success

rate of 73–83% at 1 year. [4] Based on 10 min primary augmented trabeculectomy surgery with a 10-year follow-up period and target IOP of 10 mmHg (trabeculectomy 10-10-10 challenge), 65% of patients with JOAG achieved ≤ 12 mmHg IOP at the last follow-up [12]. It was reported even without augmentation that trabeculectomy showed good long-term success in patients with JOAG [12].

Higher IOP is recommended post-operatively for functionality of the valve in AGV and the hypertensive phase is a common occurrence in BGI [9,13]. It is possible that this is responsible for a slight increase in IOP at 1 month post-GDD implantation. Sudden elevation of IOP may cause a detrimental effect on advanced glaucoma [14]. Unfortunately, we did not include the severity of visual field defect in the present study. In addition, GDD implantation was conducted on patients who had been detected and treated for a longer period. The longer duration of treatment with topical pressure-lowering drugs may increase the risk of fibrosis and failure of surgical intervention [15]. This may also play a role in the long-term success of surgical intervention in patients with JOAG.

On the other hand, a higher frequency of hypotony in trabeculectomy may be responsible for the lower IOP in this study. Hypotony maculopathy is reported to be higher in the younger age group, male gender, and myopic patients [16]. Hypotony maculopathy usually occurs after prolonged hypotony postoperatively. However, none of our patients in this series developed hypotony maculopathy. Poorer survival of the bleb in eyes that developed hypotony at 1 month postoperatively [17] has also been reported. The success rate of primary augmented trabeculectomy is reported as between 50–87% at 3 years [1,4,18]. The success rate is lower than in patients with primary open angle glaucoma, due to the exaggerated

healing process in the younger age group [19]. Nevertheless, in general, primary augmented trabeculectomy showed better IOP control (below 10 mmHg) compared to GDD implantation (above 12 mmHg) in this short 12-month observation.

The main limitation of this study was the small number of eyes with GDD implantation as primary intervention. GDD implantations were mostly reserved as secondary intervention when trabeculectomy had failed in patients with JOAG [20]. To the best of our knowledge, there has been no study that compares primary surgical interventions between trabeculectomy and GDD implantation in patients with JOAG. Both surgical interventions pro-

vide a reduction of IOP, but primary augmented trabeculectomy shows better and stable IOP control in patients with JOAG. A prospective study with a larger number of patients is required to determine the best surgical options for patients with JOAG.

CONCLUSIONS

Primary augmented trabeculectomy provides a better pressure-lowering effect as a primary surgical intervention, but with a higher incidence of hypotony compared to GDD implantation in patients with JOAG.

REFERENCES

1. Pathania D, Senthil S, Rao H, Mandal AK, Garudari CS. Outcomes of trabeculectomy in juvenile open angle glaucoma. *Indian J Ophthalmol.* 2014;62(2):224-228.
2. Wiggs JL, Del Bono EA, Schuman JS, Hutchinson BT, Walton DS. Clinical Features of Five Pedigrees Genetically Linked to the Juvenile Glaucoma Locus on Chromosome 1q21-q31. *Ophthalmology.* 1995;102(12):1782-1789.
3. Ciociola, Elizabeth C., Klifto, Meredith R. Juvenile open angle glaucoma: current diagnosis and management. *Curr Opin Ophthalmol.* 2022 Mar 1;33(2):97-102.
4. Tsai JC, Chang HW, Kao CN, Lai IC, Teng MC. Trabeculectomy with mitomycin C versus trabeculectomy alone for juvenile primary open-angle glaucoma. *Ophthalmologica.* 2003;217(1):24-30.
5. Ishida K, Mandal AK, Netland PA. Glaucoma drainage implants in pediatric patients. *Ophthalmol Clin North Am.* 2005;18(3):431-442.
6. Djodeyre MR, Peralta Calvo J, Abelairas Gomez J. Clinical evaluation and risk factors of time to failure of Ahmed Glaucoma Valve implant in pediatric patients. *Ophthalmology.* 2001;108(3):614-620.
7. European Glaucoma Society Terminology and Guidelines for Glaucoma, 4th Edition - Chapter 2: Classification and terminology supported by the EGS Foundation: Part 1: Foreword; Introduction; Glossary; Chapter 2 Classification and Terminology. *Br J Ophthalmol.* 2017;101(5):73-127.
8. Cantor LB, Mantravadi A, WuDunn D, Swamynathan K, Cortes A. Morphologic classification of filtering blebs after glaucoma filtration surgery: The Indiana Bleb Appearance Grading Scale. *J Glaucoma.* 2003;12(3):266-271.
9. Islamaj E, Wubbels RJ, de Waard PWT. Primary Baerveldt versus trabeculectomy study after one-year follow-up. *Acta Ophthalmol.* 2018;96(6):e740-746.
10. Das JC, Chaudhuri Z, Sharma P, Bhomaj S. The Ahmed Glaucoma Valve in refractory glaucoma: Experiences in Indian eyes. *Eye.* 2005;19(2):183-190.
11. Le, P. H., Nguyen, M., Humphrey, K. A., & Klifto, M. R. Ahmed and Baerveldt Drainage Implants in the Treatment of Juvenile Open-angle Glaucoma. *Journal of glaucoma.* 2021;30(3), 276-280.
12. Sihota R, Shakrawal J, Sidhu T et al. Does TRABECULECTOMY meet the 10-10-10 challenge in PACG, POAG, JOAG and Secondary glaucomas? *Int Ophthalmol.* 2020;40(5):1233-1243.
13. Riva I, Roberti G, Oddone F, Konstas AG, Quaranta L. Ahmed glaucoma valve implant: Surgical technique and complications. *Clin Ophthalmol.* 2017;11:357-367.
14. Kastner A, King AJ. Advanced glaucoma at diagnosis: current perspectives. *Eye.* 2020;34(1):116-128.
15. Broadway DC, Chang LP. Trabeculectomy, Risk Factors for Failure and the Preoperative State of the Conjunctiva. *J Glaucoma* 2001; 10:237-249
16. Fannin LA, Schiffman JC, Budenz DL. Risk factors for hypotony maculopathy. *Ophthalmology* 2003;110:1185-1191
17. Benson SE, Mandal K, Bunce CV, Fraser SG. Is post-trabeculectomy hypotony a risk factor for subsequent failure? A case control study. *BMC Ophthalmology* 2005; 5:7.
18. Koraszewska-Matuszewka B, Samochowiec-Donocik E, Filipek E. Prognosis in juvenile glaucoma after trabeculectomy. *Klin Oczna* 2002;104:115-118.
19. Stürmer J, Broadway DC, Hitchings RA. Young Patient Trabeculectomy: Assessment of Risk Factors for Failure. *Ophthalmology* 1993; 100: 928-939.
20. Wilson MR, Mendis U, Smith SD, Paliwai A. Ahmed glaucoma valve implant vs trabeculectomy in the surgical treatment of glaucoma: A randomized clinical trial. *Am J Ophthalmol.* 2000;130(3):267-273.