

# BILATERAL EYE INJURY WITH BILATERAL BLOWOUT FRACTURE CAUSED BY HIGH-PRESSURE WATER JET IN 16-YEAR-OLD FEMALE FIREFIGHTER. CASE REPORT

Štěpánková J.<sup>1</sup>, Cendelín J.<sup>1,2</sup>, Arendáč J.<sup>1</sup>, Mixová D.<sup>3</sup>, Šimsová M.<sup>4</sup>, Hubáček M.<sup>5</sup>, Dotřelová D.<sup>1</sup>, Hložánek M.<sup>1</sup>

<sup>1</sup>Department of Ophthalmology, 2<sup>nd</sup> Faculty of Medicine, Charles University in Prague and Motol University Hospital

<sup>2</sup>Microsurgery Centre OFTA, Plzeň

<sup>3</sup>Department of Anaesthesiology and ICM, 2<sup>nd</sup> Faculty of Medicine, Charles University in Prague and Motol University Hospital

<sup>4</sup>Department of Paediatric Surgery, 2<sup>nd</sup> Faculty of Medicine, Charles University in Prague and Motol University Hospital

<sup>5</sup>Department of Stomatology, 2<sup>nd</sup> Faculty of Medicine, Charles University in Prague and Motol University Hospital

*The authors of the study declare that no conflict of interests exists in the compilation, theme and subsequent publication of this professional communication, and that it is not supported by any pharmaceuticals company. The study has not been submitted to any other journal or printed elsewhere, with the exception of the stated congress abstracts.*

#### Thanks

*The authors thank the patient and her family for providing portrait photographs before and after the injury.*

*Supported by project (Ministry of Health) for conceptual development of research organisation 00064203 (FN MOTOL) and CZ.2.16/3.1.00/24022.*

*Presented at the 28<sup>th</sup> annual congress of the Czech Ophthalmology Society of J. E. Purkyně, and simultaneously at the first annual congress of the Czech Ophthalmology Society of J. E. Purkyně held in "hybrid" form online, 17-19 September 2020.*

Received: 5 November 2020

Accepted: 12 January 2021

Available on-line: 1 May 2021



MUDr. Jana Štěpánková  
Oční klinika dětí a dospělých  
2. LF UK a FNM  
V Úvalu 84  
Praha 5 - Motol, 150 08  
E-mail: jana.stepankova@lfmotol.  
cuni.cz

## SUMMARY

**Purpose:** The aim is a report of a case of bilateral eye injury with bilateral blowout fracture caused by a high-pressure water jet from a fire hose in 16-years old girl during a competition for young fire fighters.

**Methods:** We present a case report of a 16-years old female patient presenting with bilateral extensive eyelid contusion, oedema and lacerations of upper eyelids, lacerations of bulbar conjunctiva, contusion of both eyes, left optic nerve and bilateral blow out fractures of orbits.

**Results:** The initial ocular examination revealed "hand motion" in the right eye and no sensation of light on the left eye. Intraocular pressure was low on both eyes. Motility of both eyes was reduced, especially on the left eye. Lacerations of eyelids and conjunctiva required surgical approach. No repair of the upper canaliculus of the left eye was attempted. Paralytic mydriasis and loss of lens accommodation in both eyes did not change throughout follow-up period. Surgical approach required left blowout fracture, ocular motility of the right eye improved spontaneously. Traumatic cataract developed on the left eye within 1 year after injury and required cataract surgery and posterior capsule lens implantation, the right lens remain clear. A massive scarring of retina and choroid in inferior parts of eyes and in a macula reduced the best-corrected visual acuity on the right eye to 0.15 and on the left eye to 0.08. Intraocular pressure is within normal limits without any glaucoma therapy. Follow up period is three years.

**Conclusion:** This is the first reported case of child with eye injury caused by a high-pressure water jet and during a sport activity.

**Key words:** high-pressure water jet, contusion of eye, children, blowout fracture, traumatic cataract

Čes. a slov. Oftal., 77, 2021, No. 2, p. 88–93

## INTRODUCTION

A high-pressure water jet may be a source of injury to the eyelids, lacrimal drainage system, eyes and orbits. Various different industrial [1,2] and agricultural implements [3,4], as well as pressurised cleaners [5] have been described as the source of this injury, especially in the case of malfunction or handling without protective aids. In addition, a mobile police water cannon [6], and in a number of cases fire hoses [7,8,9] have been the cause. The scope and severity of the injury depends on the pressure of the water, the length of impact of the water jet on the affected area, the diameter of the jet (whether this concerns the place of malfunction of a device or the usual area to where the water is to be directed), on the distance of the injured person from the source of the water jet and on the direction of the water jet, which is mostly upwards. The water jet may also be a source of both infectious agents [5], and agents causing granulomas.

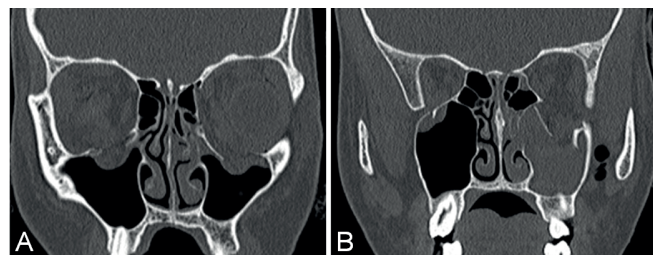
The injuries commonly described include oedema of the eyelids, laceration of the upper eyelid in the medial region, sometimes with laceration of the posterior limb of medial canthal tendon and lacrimal drainage system, and complete rupture of the medial part of the upper eyelid [4]. In some cases, circular lacerations of the conjunctiva and episclera have been described, sometimes with subconjunctival hemorrhage, with a several millimetres interval from the corneal limbus [4]. This laceration of the bulbar conjunctiva and episclera may be deepened along the sclera nasally, where it may breach the orbital septum in the upper nasal quadrant and cause a prolapse of orbital fat [4]. A water jet from beneath may rupture and destroy both oculomotor muscles and the optic nerve and may even cause avulsion of the optic nerve. The most destructive injuries described to date [2] are autoenucleation and a finding of an eyeball with part of the optic nerve 45 metres from the place of the injury. The pressure of the water may cause a hydraulic fracture of the orbit. If the water jet is targeted directly at the eye, it may cause contusion of the eye and rupture of the eyeball [10]. In the case of contusion, conditions described include rupture of the Descemet's membrane [11], hyphema [6,7,8,11], pupil dilation [6,7,11], paralysis of accommodation [6,7], subluxation of the lens and prolapse of the vitreous body [8], vitreous hemorrhage [8], retinal and subretinal hemorrhage, necrosis of the retina, avulsion of the vitreous base and generation of a giant retinal tear [1], traumatic macular hole with incipient retinal detachment [8] and subsequent onset of traumatic cataract [11]. The eventual severity of the injury depends on mono or bilateral affliction, the scope of affliction of the retina and optic nerve, and any applicable infection by pathogens from the water source [5], or infiltration of particles capable of causing granulomas [3].

## CASE REPORT

The described patient is a 16-year-old girl, who before the injury was a secondary school student in a good con-

dition of health. The injury occurred during a firefighting competition in July 2017. The competition task was to run with an empty fire hose to a designated base. From here she was to aim the jet of water at a target. The pressurised water was discharged into the fire hose by the attendance staff at the pump from the fire engine. All was intended to take place as quickly as possible. However, the girl did not hold the nozzle of the fire hose firmly in her hands in the required direction, and at the moment the fire hose was filled with water, the mouth of the nozzle twisted upwards towards her face. The jet of water hit her at force in the face and the upper part of the chest. The distance between the mouth of the fire hose and her head could therefore have been even shorter than 0.5 metre.

On the day of the injury, the patient manifested oedema of the eyelids, laceration of both upper eyelids in the medial region, mostly superficial, on the left upper eyelid medially with upper canalicular laceration, but the eyelid was not further lacerated in its full thickness. Sanguinolent secretion from both the conjunctival sacs was linked to semicircular laceration of the pale bulbar conjunctiva and episclera, with a several millimetres (approx. 4–6 mm) interval from the corneal limbus, while only the upper section between no. 11.5–1.5 in both eyes remained intact. We did not clinically observe a lesion of the orbital septum in either of the eyes. The corneas were intact, the irises were haemorrhaged on the surface in several places, and both pupils were in dilated paralytic mydriasis. The lenses were transparent and without signs of laceration of the zonular fibers. The vitreous space was well transparent in the right eye, slightly blurred in the left eye. The upper intact part of the retina contrasted sharply with the lower part of both retinas, where the heavily white colour of the retina and choroid with retinal haemorrhages infringed horizontally as far as the upper temporal arcade inclusive. In the lower part of the left eye there was presence of partial vitreous hemorrhage and subretinal hemorrhage. Best corrected visual acuity in the right eye was hand motion, in the left eye no light perception. Visual acuity in the left eye attested to contusion of the left optic nerve. On a performed CT examination, a bilateral blowout fracture of the orbital floor was described, with dislocated broad fragments into the maxillary sinuses, in the left eye there was also an undislocated fracture of the medial wall. In addition to air bubbles in both orbits, presence of air was deter-



**Fig. 1.** Initial CT examination (A) Bilateral fracture of orbital floor (B) Presence of air in the left pterygopalatine fossa (right).

mined in the left fossa pterygopalatina (Fig. 1). With the exception of an incomplete fracture of the left clavicle, which was treated conservatively, no further traumatic changes were demonstrated. Motility of the eyeballs was restricted in all directions, in the right eye slightly, in the left eye very pronouncedly.

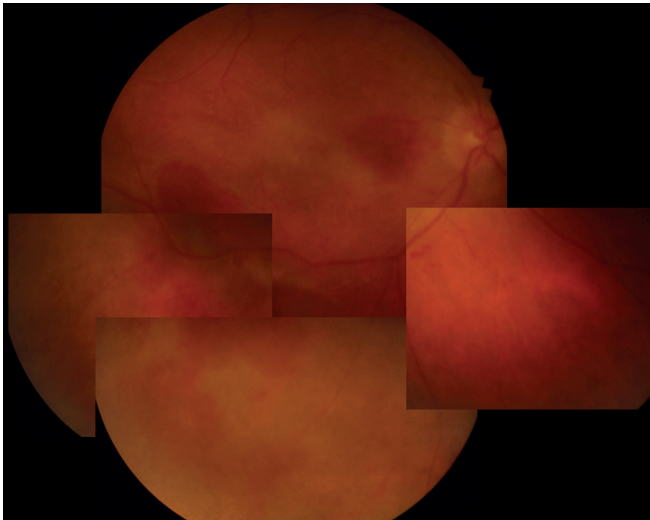
On the day of the accident, a review of the injuries was performed under general anaesthesia, with suture of both upper eyelids and suture of the bulbar conjunctiva of both eyes. We did not perform repair of the upper canaliculus of the left eye, the lower canaliculus was not damaged, the upper canaliculus was ruptured 1 mm from the lacrimal punctum. A forced duction test was also performed during the treatment. It was possible to perform this test in the right eye, in the left eye this was impossible due to extreme hypotony.

Due to the severity of the damage to both eyes, as well as the need to monitor the general condition with reference to the unclear extent of the internal injuries upon concussion of the chest and the age of the patient, a regimen of maximum rest was ordered in the first week after the injury, with two days inpatient care at the department of paediatric anaesthesiology and resuscitation, with sedation of the patient and bandaging of both eyes, followed by acute inpatient care at the department of paediatric surgery.

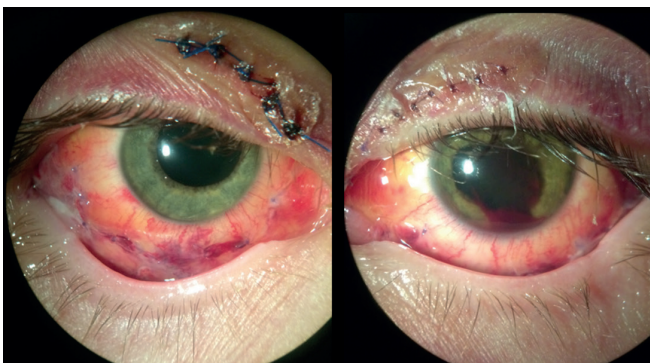
General steroid therapy incorporated ten-day ad-

ministration of treatment to the patient with a body weight of 55 kg, initially intravenous dexamethasone dihydrogen phosphate 24 mg/day (corresponding to dexamethasone 20 mg/day) divided into three daily doses, up to the fourth postoperative day, preparation Dexamed 8 mg every 8 hours. From the fifth postoperative day the patient was transferred to prednisone, specifically Prednison 20 Léčiva tablet in a dose of 60 mg/day in three daily doses, on the sixth to eighth postoperative day 40 mg/day and on the ninth to eleventh postoperative day 20 mg/day, from the twelfth day general steroid treatment was discontinued. Concurrently with the reduction of general administration, after the seventh postoperative day, following prior application of cream beneath the bandage, local administration of dexamethasone and antibiotic drops was increased, one drop every two hours and cream for the night.

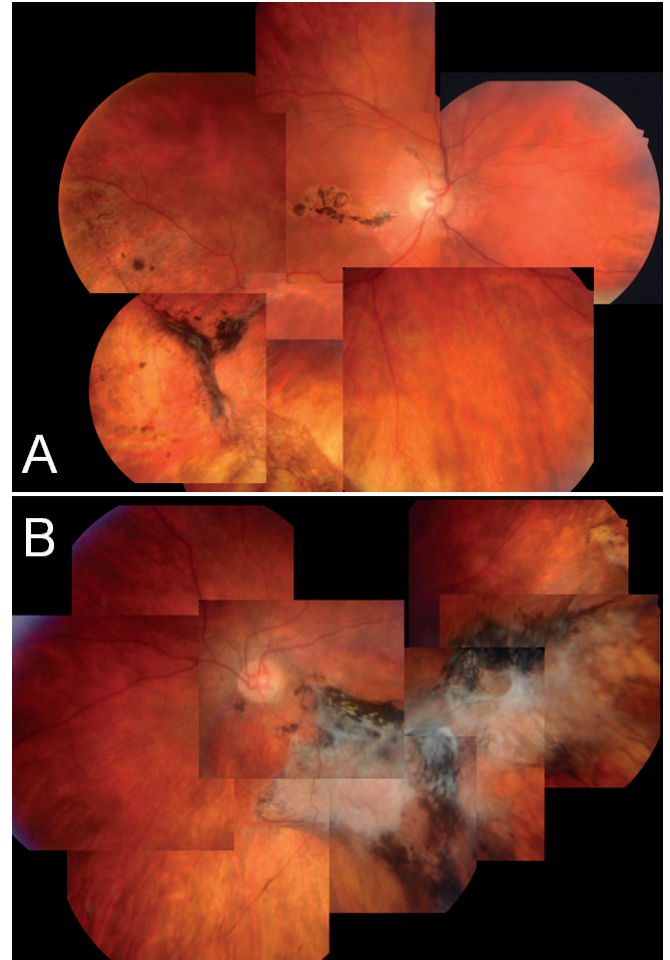
General prophylactic antibiotic therapy was administered for 12 days, ampicillin with clavulanic acid (Amok-siklav) up to the fourth day parenterally, subsequently orally. Other adjuvant symptomatic treatment incorporated analgetics (paracetamol, ibuprofen, morphine), haemostatic etamsylate (Dicynone), anti-ulcerous treatment with omeprazole (Helicid), the anti-depressant fluoxetine and medication used for panic disorder clonazepam (Deprex, Rivotril), antihistamine with sedative effects pro-



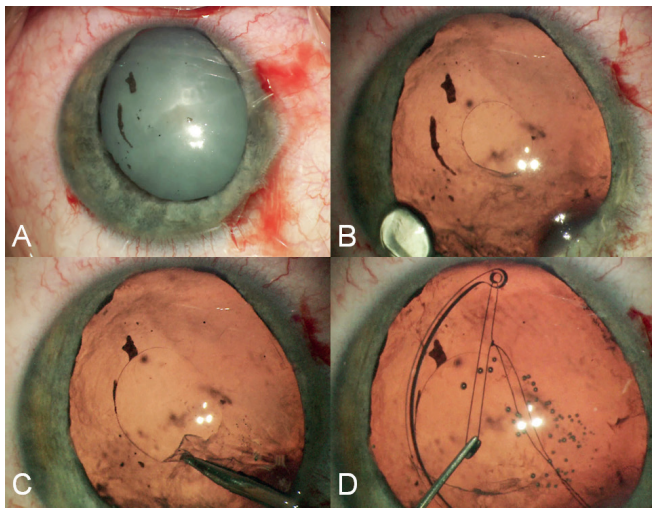
**Fig. 2.** Retina of right eye one week after injury.



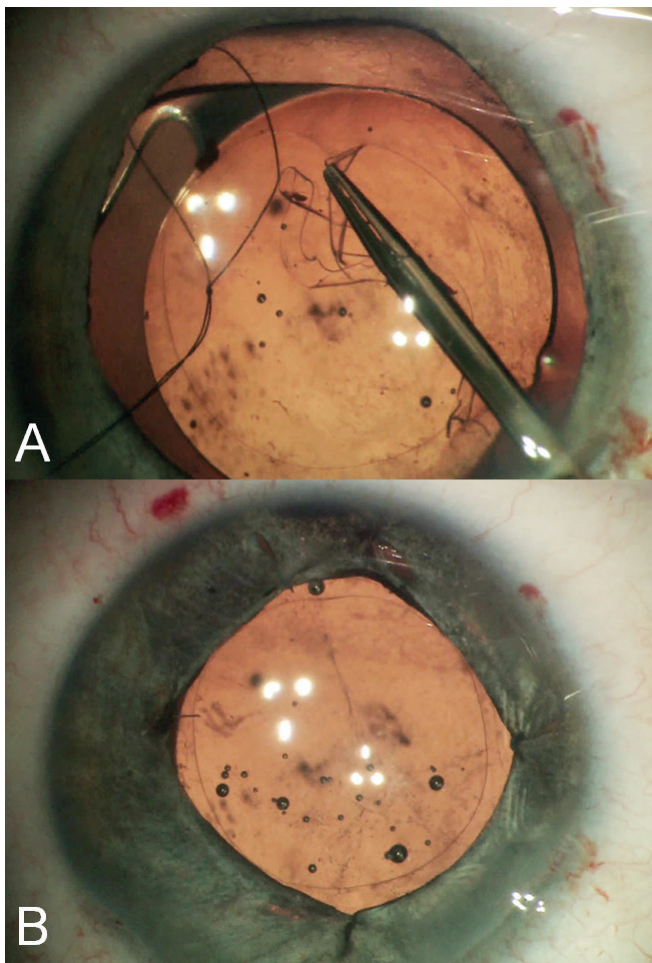
**Fig. 3.** Both eyes one week after injury.



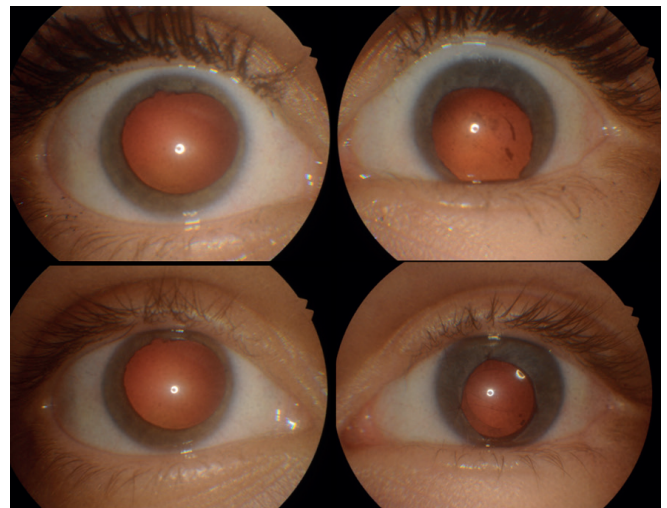
**Fig. 4.** Ocular fundus of the right (A) and left (B) eye after healing.



**Fig. 5.** (A) Intumescent cataract and iridoplegia at the beginning of cataract surgery (B) Primary small capsulorhexis, reducing risk of radial tear. (C) Enlargement of capsulorhexis (D) Implantation of capsular tension ring using a fibre loop attached to a Kuglen hook. Loop-on-suture-guided insertion of the ring minimises zonular stress. Leaving the fibre allows removal of the tension ring at any time during surgery.



**Fig. 6.** (A) Adjustment of anterior capsulorhexis according to optic part of intraocular lens. (B) Iridoplasty using four sutures. The size of reconstructed pupil respected the patient's wishes to have both pupils of similar size, together with the need to cover the peripheral parts of artificial lens in order to minimise side effects of peripheral light.



**Fig. 7.** Anterior segment of both eyes after healing of trauma (top), and after surgery for left traumatic cataract (bottom).

methazine (Prothazin) and B vitamins (Milgamma).

After the third postoperative day, central visual acuity began to improve very gradually. Spontaneous occurrence of vitreous hemorrhage in the left eye after the second postoperative day did not have a significant influence on visual acuity: light perception in the left eye persisted from the third to the eleventh postoperative day, when the left eye then additionally began to perceive hand motion eccentrically. The right eye, in which there was light projection from the outset, could count fingers at 20 cm from the third postoperative day, and fingers at 1 m on the eleventh postoperative day (Fig. 2 and 3). Six weeks after the injury, visual acuity in the right eye had improved to 6/36 (0.16) excentrically, and in the left eye to 1/24 (0.04) excentrically (Fig. 4).

Bilateral paralytic mydriasis and paralysis of accommodation persisted bilaterally throughout the entire observation period. Six months after the injury, traumatic cataract began to develop in the left eye. In October 2018, surgery was performed on traumatic cataract in the left eye, with implantation of a capsular distension ring, a posterior chamber intraocular lens and iridoplasty (Fig. 5 and 6). Upon the patient's wishes, the width of the iridoplastically altered pupil was adjusted to the width of the pupil of the other eye. Best corrected visual acuity had in the left eye returned to its original level (1/12–1/9 (0.08–0.1)) before the onset of cataract (Fig. 7).

As against the baseline finding, which affected the entire lower half of the retina bilaterally, up to the upper temporal arcade, the injury was shown to be only commotion retinae in the paracentral parts of both maculas, in which oedema subsided and the functional parts of the retina, which enable simultaneous eccentric visual acuity, were revitalised. Partial vitreous hemorrhage of the left eye was spontaneously reabsorbed. Extensive contusion injury of both retinas led bilaterally to area necrosis, with subsequent scarring of the retina and choroid in the lower half, in the left eye with extensive pigmentation and subretinal scarring in the region of



**Fig. 8.** Detail of patient's face before trauma (top), and post-traumatic situation (bottom): visible posttraumatic side-symmetrical enophthalmos.

the original subretinal haemorrhage. The posterior pole of both eyes was affected by bilateral scarring of the centre of the macula and the maculo-papillary bundle.

With the subsidence of the swelling in the area of the eyelids and orbits, enophthalmos was manifested bilaterally, motility of the right eye spontaneously corrected itself, with only a slight improvement of motility of the left eye. The patient perceived diplopia in the primary position of the eyes. The bilateral blowout fracture of the orbital floor was treated conservatively in the right eye, surgically in the left eye. The surgical procedure, which incorporated a review, release of the orbital floor and its reconstruction with a MEDPOR implant was deferred for three weeks due to contusion of the left optic nerve and pronounced hypotony in the left eye and was eventually performed in the middle of August 2017. Postoperatively, motility of the left eye was markedly improved. Subjectively perceived diplopia persisted only in extreme gaze positions, especially upper right, throughout the entire follow-up period (Fig. 8).

## METHOD

The patient's finding was monitored continuously by means of regular clinical examination with the use of indirect ophthalmoscopy (Sigma 150, Heine Optotechnik, Germany) with a +28 Dpt lens (Ocular Instruments, Washington, USA), examination on a slit lamp (Nidek SL-250, Japan), biomicroscopic examination (noncontact VOLK Super Field NC lens, VOLK Optical, Ohio, USA), contact measurement of intraocular pressure (Tonopen Avia) and photographically (retinal camera Kowa VX-10a, Japan), biometric data Tomey (Tomey Corporation OA-2000 IOL cal. OPT).

We searched the key words in the PubMed database, with references to studies on the relevant issue published in journals indexed in MEDLINE: high-pressure water jet, eye; high-pressure water, eye; hydraulic injury, eye.

## DISCUSSION

The great majority of the found and described case reports referring to an injury by a high-pressure water jet relate to working activities in connection with attendance to or repair of devices which can create a jet of water. The described cases were of adults, mostly men in middle age. The description related to other activity only exceptionally. Landau et al. [6] described three adult patients injured in one location, two men and one woman who were hit with a mobile police water cannon during a police attempt to break up a demonstration. Acheson et al. [7] described two university students, thus probably adults, though age and sex were not stated, who were struck in the face with water from a fire hose from a distance of less than 5 metres during a university rag week.

Membership of voluntary firefighting associations, similarly to social and sports activity in connection therewith, are very widespread and popular in the Czech Republic. Although nobody expects that girls, unlike boys, will become professional firefighters in adulthood, from childhood, members of firefighting hobby groups include both boys and girls. Our patient was injured before reaching the age of 18 years, during an activity considered a sporting event, in which she was participating voluntarily. In both respects (age less than 18 years, voluntary sporting activity), according to our information this represents the first description of such an injury.

This type of injury is characterised by a predominance of the affliction in the lower halves of the eyes. Due to the Bell's phenomenon, in an attempt to close the eyes, the lower halves of the retinas are most likely to be affected, which we confirm in accordance with Landau [6]. In addition, a role is played by the upward direction of the water jet.

The initial regimen of rest helped prevent more serious further retinal complications, in particular retinal detachment, which it was feared and could have occurred on the basis of any applicable retinal defects within the terrain of retinal necroses.

The high-pressure fluid need not necessarily be water. For example, Holds et al. [3] described four case reports of patients following impact of a high-pressure jet of fluid to the area of the orbit, none of which consisted predominantly of water. The described industrial injuries contain fluid with fungicide, hydraulic fluid, and two injuries with oil-based fluid when extracting crude oil. The article contains a description of the treatment of patients, including a range of references to subsequent chronic damage to the orbits (granulomas, lipogranulomas) if the high-pressure fluid is not water but another liquid, especially crude oil.

A serious case from Australia was reported by Fairley [5], concerning the occurrence of life-threatening mucormycosis in an immunocompetent patient, beginning in the orbit, which was struck by a jet of pressurised water when cleaning an air conditioning unit.

With reference to the fact that water is mostly pumped into the tanks of fire engines from surface sources of water (firefighting tanks, ponds, rivers), and biological contamination may therefore be substantial, there were no serious infections in the affected area, either in our patient or in any other of the patients with a described injury from a fire hose. In addition, in our patient no granulomas appeared in the affected area.

A combination of an orbital blowout fracture with severe affliction of the eye, which is furthermore bilateral, as we observed in our patient, is neither frequent nor typical. In our experience, blowout fracture of the orbital

floor mostly has a protective effect on the eyeball itself. Manifestations of contusion of the eye where no fracture occurs are usually worse.

## CONCLUSION

The injury to both eyes by a high-pressure water jet in our patient led to a pronounced mutilating injury. This is the first described case in a patient aged less than 18 years. It is also the first described case in an activity that was not occupational or in connection with a police intervention; it was caused during a fully voluntary, sporting activity

## LITERATURE

1. Bowman RJ, Hodgkins PR, Liu CS, Antcliff RJ, Scot JD. Giant Retinal Tear Caused by Hydraulic Injury. *Eye (Lond)*. 1994;(Pt 4):478-479.
2. DeAngelis DD, Oestreicher JH. Traumatic enucleation from a high-pressure water jet. *Arch Ophthalmol*. 1999;117(1):127-128.
3. Holds JB, Patrinely JR, Zimmerman PL, Anderson RL. Hydraulic orbital injection injuries. *Ophthalmology*. 1993;100(10):1475-1482.
4. Salminen L, Ranta A. Orbital laceration caused by a blast of water: report of 2 cases. *Br J Ophthalmol*. 1983;67:840-841.
5. Fairley C, Sullivan TJ, Bartley P, Allworth T, Lewandowski R. Survival after rhino-orbital-cerebral mucormycosis in an immunocompetent patient. *Ophthalmology*. 2000;107(3):555-558.
6. Landau D, Berson D. High-pressure directed water jets as a cause of severe bilateral intraocular injuries. *Am J Ophthalmol*. 1995;120(4):542-543.
7. Acheson JF, Wong D, Chignell AH. Eye injuries caused by directed jets of water from a fire hose. *Br Med J (Clin Res Ed)*. 1987;294(6570):481-482.
8. Georgalas I, Ladas I, Taliantzis S, Rouvas A, Koutsandrea C. Severe intraocular trauma in a fireman caused by a high-pressure water jet. *Clin Exp Ophthalmol*. 2011;39(4):370-371.
9. Gracner B, Pahor D. Bilateral eye injury caused by a high-pressure water jet from a fire hose. *Wien Klin Wochenschr*. 2001;113 Suppl 3:62-64.
10. Oosuka S, Sato T, Tajiri K et al. A Case of Ruptured Eyeball Caused by High-Pressure Water Jets. *Ophthalmic Surg Lasers Imaging Retina*. 2018;49(6):451-455.
11. Kwong TQ, Khandwala M. Corneal Descemet's membrane rupture in a patient sustaining high-pressure water jet injury. *Can J Ophthalmol*. 2015;50(3):35-36.