

BILATERAL CONGENITAL MULTIPLE PIGMENTED VITREOUS CYSTS IN A THREE-YEAR-OLD GIRL: TEN YEAR OBSERVATION

¹Štěpánková J., ²Hósová M., ¹Dotřelová D.

¹Department of Ophthalmology, 2nd Faculty of Medicine, Charles University Prague and Motol University Hospital
Head: prof. MUDr. Dagmar Dotřelová, CSc., FEBO

²Ophthalmology Clinic, Pohraniční 1288/1, 405 02, Děčín

Presented at the 16th congress of the Czech Vitreoretinal Society with international attendance in Mikulov, 24-26 November 2016

The authors of the study declare that no conflict of interest exists in the compilation, theme and subsequent publication of this professional communication, and that it is not supported by any pharmaceuticals company.



MUDr. Jana Štěpánková
Oční klinika dětí a dospělých UK 2. LF a FNM
V Úvalu 84
150 08 Praha 5 – Motol
e-mail: jana.stepankova@lfmotol.cuni.cz

SUMMARY

The authors present a case report of a three-year-old female patient with bilateral multiple anterior vitreous cysts. During examination for intermittent esotropia of the right eye was diagnosed not only hypermetropia, astigmatism and anisometropia, but also pigmented changes in peripheral retrolental space of both eyes. Clinical examination under general anaesthesia revealed bilateral multiple pigmented immobile vitreous cysts. There were five almost spherical, translucent, but slightly pigmented cysts on its cover on the right eye and four similar on the left, but visible only with dilated pupils. A dilating of pupils was slow and required more mydriatics than in similar aged children. Follow up period is ten years now. Occlusion therapy of amblyopia was performed to nine years of age. Treatment of refractive error and esotropia with correction for hypermetropia, astigmatism and anisometropia continues. Best corrected visual acuity in thirteen-year-old girl is 1,0 in both eyes without any visual disturbances described by patient. Corrected visual acuity in each eye is 1,0, right eye with +3,5 D sph., -3,5D cyl., axis 175°, left eye with +7,5 D sph., -3,0 D cyl., axis 35°. Patient is otherwise healthy and without any mental deficit. Position of all cysts remains unchanged and stable during the follow up period (with recommendation to avoid hits to the head for all time, mainly in sports). Formation and slow progression of partial cortical cataract in the area of contact of the lens and one cyst in inferonasal quadrant of the lens on the right eye is monitored. A lamellar retinal extrafoveal defect of posterior pole of the right eye was found by OCT imaging.

Key words: vitreous cyst, idiopathic, congenital, bilateral, multiple, pigmented, immobile, hypermetropia, astigmatism, anisometropia, esotropia, cortical cataract, retinal lamellar extrafoveal defect, OCT

Čes. a slov. Oftal., 73, 2017, No. 1, p. 25–29

INTRODUCTION

Bilateral congenital vitreous cysts rank among rare findings. In the literature we usually encounter a description of a single cyst in one eye, which is exposed during the course of life upon its release into the posterior sections of the vitreous body, when the patient notices the cyst upon its movements within the visual field, although it does not also permanently impair physiological central visual acuity. It is most frequently described as an optically translucent, spherical structure, freely mobile in the central lacuna of the vitreous body, with a fine pigmented mesh on the surface, which only slightly conceals the structures of the retinal capillaries located beneath it, by which it becomes visible both for the patient and for the observer. In general the remaining morphological ocular finding is described as physiological. Even a smaller impulse, not considered to be a trauma by the patient, is probably sufficient to trigger the release of the cyst. Such a vitreous cyst was first described in 1899 by the New York ophthalmologist J.O. Tansley [27] in a right hypermetropic and blunt-sighted eye of the seventeen-year-old son of his general practitioner colleague.

CASE REPORT

During the course of an examination for intermittent esotropia in the right eye on a three-year-old girl in November

2006, in addition to hypermetropia, astigmatism and anisometropia, pigment changes were also diagnosed in the peripheral sections of the anterior vitreous body in both eyes. A clinical examination under general anaesthesia revealed bilateral multiple pigmented and immobile vitreous cysts. Five almost spherical, translucent, but slightly pigmented cysts were located on the anterior vitreous body on the right eye and four similar on the left, visible only with dilated pupils (fig. 1). No other pathologies of the anterior segment or fundus were found. Anisometropia and hypermetropia with astigmatism were confirmed. The inducement of mydriasis was always slower in the patient and required more mydriatics than in children of the same age. We have now been observing the patient continuously for ten years. Treatment of refractive error and esotropia by means of correction of hypermetropia, astigmatism and anisometropia is continuing, occlusion therapy of amblyopia was performed up to nine years of age. Best corrected visual acuity in the thirteen-year-old girl (with no general pathologies or mental deficiency) is currently (in 2016) 1.0 in both eyes, without any disturbances of vision perceived by the patient (Vision RE: 1.0 s +3.5 = -3.5/175, Vision LE: 1.0 s +7.5 = -3.0/35). The position of all the vitreous cysts has remained the same throughout the entire course of the observation (with a recommendation from the beginning of the observation period to avoid blows to the head throughout life, mainly during

sports). We recorded the formation and slow progression of a localised minor cortical cataract in the area of the contact of one cyst with the posterior surface of the lens in the inferonasal quadrant on the right eye, which does not infringe upon the optical axis; we are merely monitoring the condition (fig. 2). OCT imaging detected a minor lamellar retinal extrafoveal defect in the posterior pole of the right eye, with contiguous vitreous changes, which we are also monitoring (fig. 3), and which correlates with the photographic finding from the previous time (fig. 4).

METHODOLOGY

We have been monitoring the finding in the patient continuously by means of regular clinical examination, using examination on a slit lamp (Nidek SL-250, Japan), biomicroscopic examination (noncontact VOLK Super Field

NC lens, VOLK Optical, Ohio, USA), examination by indirect ophthalmoscopy (Sigma 150, Heine Optotechnik, Germany) with a +28 D lens (Ocular Instruments, Washington, USA) and photographically (fundus camera Kowa VX-10α, Japan), monitoring of refraction natively and in cycloplegia (combination of cyclopentolate (Cyclogyl® 1% gtt, Alcon, Novartis, Switzerland) and tropicamide (Unitropic© 1% gtt, Unimed Pharma, Slovakia) use of an autorefractometer (Nidek, Tonoref II, Japan). Due to the patient's young age, at the beginning of observation examination under general anaesthesia was used because of the necessity of examining also the full periphery of the retina. Examination by ultrasound was performed only at the beginning of observation in 2007. Optical coherency tomography (OCT) (RTVue-100, Optovue, California, USA) was used for examination of the retina of the posterior pole of both eyes.

In the PubMed database we used the key words vitreous

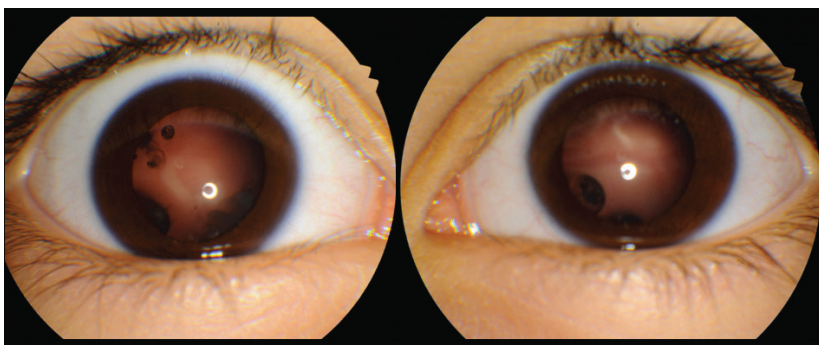


Fig. 1

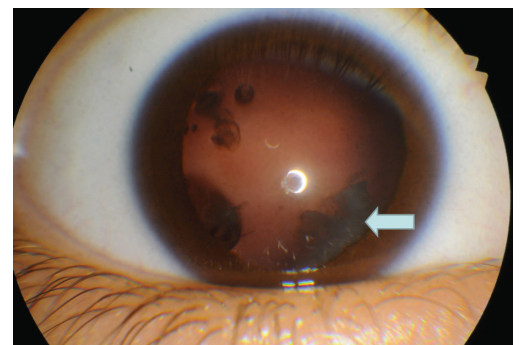


Fig. 2

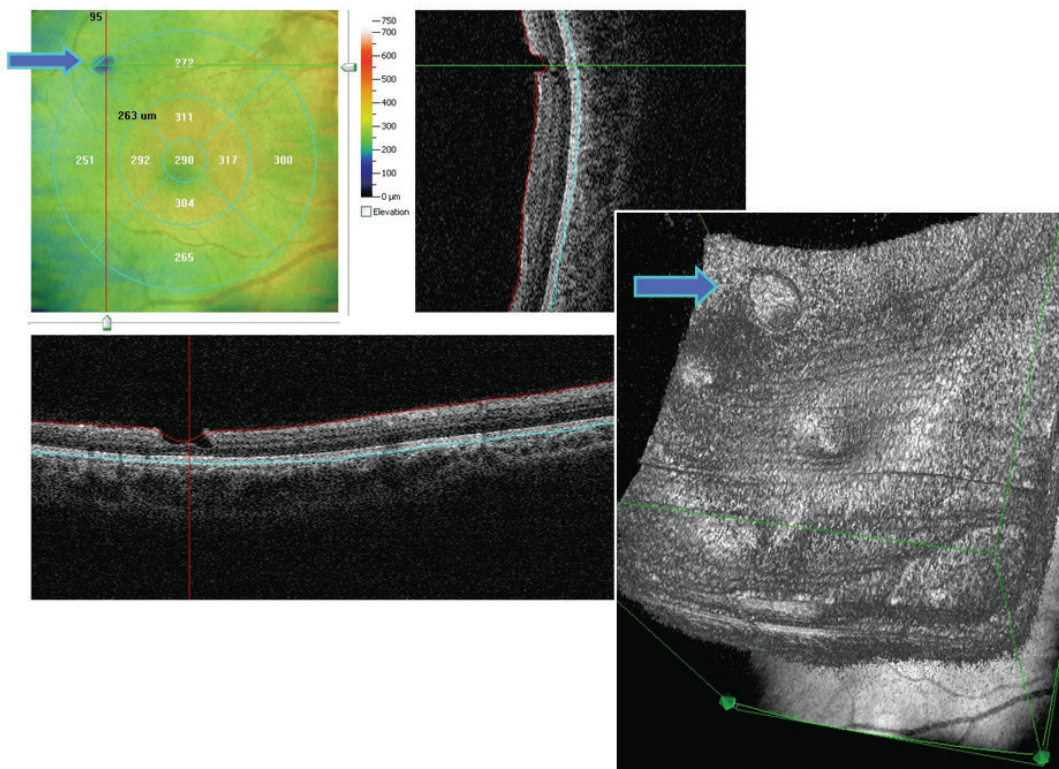


Fig. 3

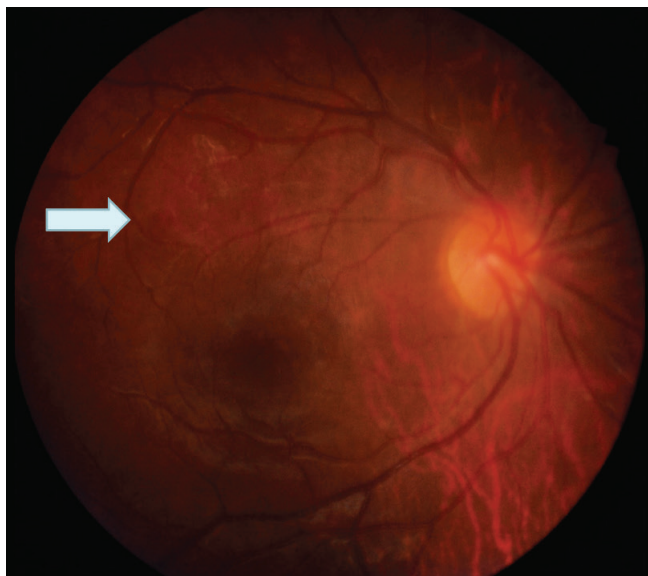

Fig. 4

cyst to search for references to studies on the theme in question, published in journals indexed in MEDLINE.

DISCUSSION

117 years have passed since 1899, when Tansley [27] published the first description of a vitreous cyst. By the method described above it is possible to obtain annotations of articles or an abstract thereof, documenting 108 patients described to date, in which we presume that this number is somewhat higher as a result of the expected incompleteness of the database before 1950. Including the information from the article by Adamczewska and Janukowicz [1] from 1973, specifically that only 25 patients were described up to 1949, it is possible to raise this number by 19 (6 case studies presented in PubMed deducted) to 127 patients described to date. Even so, this concerns rather rare findings and case reports of one or maximally two patients. An exception is the cohort of 28 patients presented by the authors Yoshida et al. [32].

Vitreous cysts of non-parasitic origin are described with regard to their frequency and laterality, age and the circumstances of their finding in the patient, mobility and depositing in the vitreous body, appearance (size, colour, shape), origin (congenital/acquired) and treatment.

From the perspective of frequency, the following four possibilities exist – individual and unilateral cysts (most frequent), individual and bilateral (e.g. Němec, Adamczewska and Janukowicz, Santos [20, 1, 25]), multiple and unilateral (e.g. Basdekidou [4]) and multiple and bilateral. Our patient belongs to the last, least frequent group.

The age spectrum of the patients described to date is broad, from 1.5 years of age (Chang [6]) up to 80 years (Santos [25]), and includes both chance findings such as ours and also much more frequently patients in whom quality of vision has deteriorated during the course of life. Patients usually describe this change as temporary blurred vision,

depending on when the newly mobile cyst in the vitreous body comes into the optical axis. Changes in vision are described also in paediatric patients, who drew attention to the problem (e.g. Tansley (17 years), Bruè (14 years) [27, 5]), or were observed during the course of examination for strabismus (Rathore (9 years), Taranath (6 years), Amer (11 and 3 years) [23, 28, 2]). A range of further patients are aged up to 40 years, but a relatively significant proportion of the described patients are within the age group above 50 years, and have a described ablation of the posterior surface of the vitreous body. Our long-term observed patient does not now describe any subjective complaints. The temporarily observed headaches of a number of years ago subsided with an adjustment of correction by eyeglasses.

A range of described cysts were detected upon their movement within the patient's visual field and upon examination through their observable movement within the vitreous body. This movement has probably never been entirely unlimited, even though a number of authors have not recorded this. It was Tansley [27] who described that a pigmented cyst may move forward and backward on the surface, inside the liquefied part of the vitreous body, and could rotate around its axis, but that one part of the cyst nevertheless remained below because it was heavier. Movement limited to the central lacuna of the vitreous body has been described by Asiyo-Vogel et al., Lira et al., [3, 16], and movement bound to the central region of the hyaloid canal by Nork and Millecchia [21]. Only very low mobility above the papilla of the optic nerve or close to the retina in the posterior and peripheral vitreous body is manifested by cysts described in patients with retinitis pigmentosa (e.g. Yoshida, Němec, Frasson [32, 20, 10]). The cysts we describe in the anterior vitreous body are immobile throughout the entire observation period.

Patients are sporadically described who have suffered a blow to the head in the past on the same side as the eye in which the cyst appears, as well as an ocular trauma or surgical procedure. A blow to the head during sport, after which a floating turbidity corresponding to a pigmented cyst was recorded for example by Bruè et al. [5]. External plombage for retinal detachment with insufflation of expansive gas and successful reattachment of the retina in the patient's anamnesis, with newly manifesting turbidity in the optical axis and a translucent cyst with grey spot in the centre was described by Asiyo-Vogel [3]. However, in the majority of cases the patients had not undergone any ocular procedure in their anamnesis and were not aware of any connection with a head trauma.

The appearance of the cyst is described according to size, colour and shape. Size ranges from very small, immeasurable by ultrasound, to several millimetres in diameter. Yoshida [32] states sizes ranging from 0.15 - 12 mm. As regards colour, we encounter several possibilities. Cysts may be entirely translucent, visible only due to the fact that they slightly conceal the vascular meshwork of the retina (e.g. Basdekidou, Toklu, Morreno-Arrones [4, 29, 19]), semi-translucent with a mesh of pigmentation on the surface (e.g. Tansley, Cruciani, Lira, Gupta, Lavric, Dragnev, Gulkilik, Amer, Ratho-

re, Taranath, Kennely, Ludwig, Bruè, Elkington, Yonekawa, Hasegawa, Santos, Adamczewska, Nork [1-2, 5, 7-9, 11-17, 21, 23, 27-28, 31]), opaque, greyish-white, non-translucent, the cystic character of which may be necessary to verify by ultrasound (e.g. Yoshida, Němec, Lavric, Frasson, Chang [32, 20, 15, 10, 6]), as well as others, which differ slightly from the usual description, e.g. partially translucent and partially grey (Asiyo-Vogel, Tranos [3, 30]). Greyish-white and non-translucent cysts are described in eyes with retinitis pigmentosa (Yoshida, Němec, Frasson [32, 20, 10]), but the incidence of a greyish-white cyst does not necessarily mean a simultaneous finding of retinitis pigmentosa. Pigmented cysts often appear in eyes without any other detected pathology (e.g. Gupta, Dragnev, Hasegawa [12, 8,13]), but various refractive deviations have been recorded relatively frequently as a secondary finding, as well as in rare cases retinoschisis (Lavric [15]) or posterior embryotoxon (Rathore [23]). The incidence of cortical opacity of the lens in the proximity of a retrolental cyst in the anterior vitreous body, similarly as in the case of our patient, is described by Amer [2]. The shape of the eye is most often described as virtually spherical, rounded, oval, but also slightly multilobular, or "somewhat resembling a potato" (Tansley [27]). The mildly pigmented anterior vitreous cysts in our patient are rounded and virtually spherical, of various sizes but no more than 3 mm.

Idiopathic vitreous cysts probably do not have a uniform origin. The majority of authors concur that it is necessary to differentiate parasitic cysts from idiopathic cysts by means of negative tests for cysticercosis, onchocercosis, toxocariasis, toxoplasmosis and eosinophilia, especially if the vitreous cysts have a greyish-white colour. The majority of authors also assume that some idiopathic vitreous cysts are congenital whilst others are acquired. Good visual acuity and only mild complaints often lead only to monitoring of the condition, without the risks that may be posed by surgical intervention. The origin of greyish-white vitreous cysts in patients with retinitis pigmentosa demonstrated by Yoshida [32] in 6.4% of patients (in 28 patients from a cohort of 435 patients with retinitis pigmentosa) still remains unclear, and they may be both congenital or acquired during the course of life. Aspiration of a pigmented cyst by means of pars plana vitrectomy and its histopathological examination was described by Orellana [22] in 1985. A pigmented, semi-translucent cyst, following unsatisfactory reduction of the size by argon laser photocystotomy, was subsequently removed by means of pars plana vitrectomy (PPV) and histopathologically and histochemically analysed by Nork and Millecchia [21] in 1997. Although Orellana inclined rather toward a traumatic explanation of the origin of vitreous cysts, Nork and Millecchia, with a similar finding with the presence of mature and immature melanosomes and also newly detected premelanosomes, argued in favour of a hypothesis concerning a residue of the primary hyaloid system, specifically a choristoma of the primary hyaloid system, thus indicating the congenital origin of this type of vitreous cyst. Congenital origin is attested to by a description of pigmented cysts in two siblings

by Amer (2004) [2]. A semi-translucent non-pigmented vitreous cyst attached to the retina was described in the case of intermediate uveitis in 2009 by Tranos [30], who presumed their acquired origin. A semi-translucent non-pigmented cyst in the eye following a previous successful cryosurgical operation for primary retinal detachment, its removal by means of PPV and histopathological examination was described by Asiyo-Vogel (1996) [3], with documenting of retinal layers in one of two obtained samples. In this case the unequivocally acquired origin of the vitreous cyst is attested to by both the histopathological analysis and the numerous clinical examinations on the previously operated patient, which would have detected a congenital cyst at the beginning of treatment. In our patient with pigmented vitreous cysts we assume a congenital origin, not only due to the typical pigmented appearance, but also with regard to the fact that this concerns a bilateral finding, at a low age and without general pathology.

Idiopathic vitreous cysts can only be monitored throughout the entire course of life. If the patient is disturbed by movement in the optical axis and blurred vision, in some patients a method of reducing cysts has been described by means of laser photocystotomy, or also complete removal by means of PPV (Nork and Millecchia) [21]. Reduction of pigmented cysts has been described by argon laser (Nork [21]), diode laser (Gulkilik [11]) and Nd-YAG laser (Ruby [24]).

A secondary finding in our patient, which we are the first to present in connection with vitreous cysts, is a minor retinal lamellar extrafoveal defect on the posterior pole of the right eye, demonstrated by OCT imaging, with adjacent vitreous changes also in the posterior pole of the eye, which are also perceptible in OCT imaging (see fig. 3, 4).

In the literature available to us we have not found any case of a patient with bilateral incidence of multiple pigmented vitreous cysts. If no other patient with a similar finding was published in the period previous to 1950, then our patient may be the first to manifest such a condition.

CONCLUSION

Idiopathic vitreous cysts are a heterogeneous group of rare pathologies, only a part of which is congenital. Semi-translucent vitreous cysts which are finely pigmented on their surface are probably congenital. If these cysts are initially deposited in the anterior vitreous body outside of the optical axis, they may easily be overlooked without the induction of artificial mydriasis, and do not trouble the patient. However, even a relatively small impulse may suffice, for example a blow to the head during sport which may seem insignificant to the patient at the time, but which may alter the situation and trigger the cyst into motion, especially if a lacuna has already been formed in the central region of the retina during the course of life. For this reason it is suitable to recommend all as yet asymptomatic patients to avoid risks sports that may involve blows to the head or falls, a factor about which we continuously remind our patient.

LITERATURE

1. **Adamczewska I., Janukowiczowa H.:** Case of free cysts in vitreous body. *Klin Oczna*, 1973; 43(12):1365–7.
2. **Amer R., Anteby I.:** Familial intraocular cysts in association with anisometropia. *Br J Ophthalmol*, 2004; 88(10): 1349–1350.
3. **Asiyo-Vogel MN., el-Hifnawi el-S, Laqua H.:** Ultrastructural features of a solitary vitreous cyst. *Retina*, 1996; 16(3) 250–4.
4. **Basdekidou C., Wolfensberger TJ.:** Six-year dynamic growth pattern of two concentric congenital vitreous cysts. *Eye (Lond)*, 2010; 24 (7), 1301–1303.
5. **Bruè C., Mariotti C., De Franco E., De Franco N., Giovannini A.:** Pigmented free-floating posterior vitreous cyst. *Case Rep. Ophthalmol Med*, 2012; 470289: 3.
6. **Chang B., Brosnahan D.:** Vitreous cyst and a cataract in a toddler. *Eye (Lond)*, 2003, 17(9) 1034–1036.
7. **Cruciani F., Santino G., Salandri AG.:** Monolateral idiopathic cyst of the vitreous. *Acta Ophthalmol Scand*, 1999; 77(5): 601–3.
8. **Dragnev D., Shanmugalingam A.:** Optical coherence tomography in a patient with congenital vitreous cyst. *BMJ Case Rep*, 2014; doi:10.1136/bcr-2014-204474.
9. **Elkington AR., Watson DM.:** Mobile vitreous cysts. *Br J Ophthalmol*, 1974; 58(2) 103–4.
10. **Frasson M, de Queiros ACC, Lino BT, Nehemy MB.:** Cisto vítreo e retinose pigmentária: relato de caso (Vitreous cyst and retinitis pigmentosa: case report). *Arq Bras Oftalmol*, 2010; 73(2) 179–181.
11. **Gulkilik G., Odabasi M., Erdur SK., Ozsutcu M., Eliacik M., Demirci G., Kocabora MS.:** A case of pigmented, free-floating vitreous cyst treated with micropulse diode laser. *Clin Exp. Optom*, 2016; 99(1): 90–2.
12. **Gupta SR., Gupta N., Anand R., Dhanwan S.:** Idiopathic pigmented vitreous cyst. *Arch Ophthalmol* 2012, 130(11): 1496–6.
13. **Hasegawa N., Kimura T., Mizota A, Sano N, Adachi-Usami E.:** Floating vitreous cyst. *Retina*, 1996; 16(6): 540–542.
14. **Kennelly KP, Morgan JP, Keegan DJ, Connell PP.:** Objective assesment of symptomatic vitreous floaters using optical coherence tomography: a case report. *BMC Ophthalmol*, 2015; 15(1): 22. doi: 10.1186/s12886-015-0003-5.
15. **Lavric A., Urbancic M.:** Floating vitreous cyst: two clinical cases. *Case Rep. Ophthalmol*, 2013; 4(3) 243–247.
16. **Lira RPC, Jungmann P., de Moraes LFL, Silveira APT.:** Clinical features, histopathological analysis and surgical treatment of a free floating vitreous cyst: a case report. *Arq Bras Oftalmol*, 2006; 69 (5): 753–755.
17. **Ludvig CA, Leng T.:** Idiopathic pigmented vitreous cyst. *Acta Ophthalmol*, 2016; 94(1) e83–4.
18. **Manyś-Kubacka K., Kociecki J.:** Bilateral cysts of the vitreous body. *Klin Oczna*, 1991; 93(10–11): 319.
19. **Morreno-Arrones JP, Jiménez-Parras R.:** Vitreous cyst: A case presentation. *Arch Soc Esp Oftalmol*, 2012 87(1): 20–22.
20. **Němec J.:** A case of bilateral cysts of the vitreous body. *Čs Oftalmol*, 1959; 15: 393–4.
21. **Nork TM., Millecchia LL.:** Treatment and histopathology of a congenital vitreous cyst. *Ophthalmology*, 1998; 105 (5): 825–830.
22. **Orellana J., O'Malley RE, McPherson AR, Font RL.:** Pigmented free-floating vitreous cyst in two young adults. Electron microscopic observations. *Ophthalmology*, 1985; 92(2): 297–302.
23. **Rathore YS., Radhakrishnan OK., Chougale N., Lune A., Magdum R., Gogate P.:** Bilateral free floating vitreous cysts with posterior embryotoxon. *Korean J Ophthalmol*, 2014; 28(6): 499–500.
24. **Ruby AJ., Jampol LM.:** Nd:YAG treatment of a posterior vitreous cyst. *Am J Ophthalmol*, 1990, 110: 428–429.
25. **Santos L., Gonzales F, Capeans C., Suarez A., Sanchez-Salorio M.:** Bilateral vitreous cysts in an 80-year-old man. *Br J Ophthalmol*, 1995, 79(9): 865–866.
26. **Steinmetz RL., Straatsma BR, Rubin ML.:** Posterior vitreous cyst. *Am J Ophthalmol*, 1990; 109: 295–7.
27. **Tansley JO.:** Cyst of the vitreous. *Trans Am Ophthalmol Soc*, 1899; 8: 507–9.
28. **Taranath DA., Flaherty MP.:** Free-floating unilateral pigmented vitreous cyst in a child. *J Pediatr Ophthalmol Strabismus*, 2007; 44(4): 243–244.
29. **Toklu Y, Raza S, Cakmak HB, Cagil N.:** Free-floating vitreous cyst in an adult male. *Korean J Ophthalmol*, 2013; 27(6): 463–465.
30. **Tranos PG., Ferrante P, Pavesio C.:** Posterior vitreous cyst and intermediate uveitis. *Eye (Lond)*, 2010; 24(6): 1115–1116.
31. **Yonekawa Y, Todorich B., Randhawa S.:** Free-Floating Pigmented Vitreous Cyst: Optical Coherence Tomography Findings. *Ophthalmology*, 2016; 123(9):2041, doi: 10.1016/j.ophtha.201605.032.
32. **Yoshida N., Ikeda Y., Murakami Y., Nakatake S., Tachibana T., Notomi S., Hisatomi T, Ishibashi T.:** Vitreous cysts in patients with retinitis pigmentosa. *Jpn J Ophthalmol*, 2015; 59: 373–377.