

Traumatic bilateral capitellar fracture in the setting of corticosteroid therapy: a case report

Traumatická bilaterálna kapitelárna zlomenina na pozadí liečby kortikosteroidmi: kazuistika

Christopher Witkowski¹, Filip Cosic², Owen Mattern³

¹Radiology Department, Wagga Wagga Health Service, Wagga Wagga, New South Wales, Australia

²Orthopaedic Department, Alfred Hospital, Melbourne, Victoria, Australia

³Orthopaedic Department, Sandringham Hospital, Sandringham, Victoria, Australia

✉ **Christopher Witkowski, MD** | cjwit1@gmail.com | www.mlhd.health.nsw.gov.au/our-facilities/wagga-wagga-health-service

Received | Doručené do redakcie | Doručeno do redakce 8. 2. 2021

Accepted | Prijaté po recenzii | Přijato po recenzii 11. 3. 2021

Abstract

Capitellar fractures are a rare entity, with only several cases of bilateral injury previously described. Corticosteroid-induced avascular necrosis (AVN) is the most common cause of non-traumatic AVN, however disease affecting the capitellum is particularly uncommon. We describe a case of bilateral capitellar fracture in a woman aged in her mid-thirties receiving high dose corticosteroid therapy for suspected uveitis. Within several weeks the patient suffered near identical coronally oriented shear fractures of both capitella, which were managed with intraosseous screw fixation and early active mobilization. This case report is the first to describe bilateral capitellar fracture in the setting of corticosteroid use. While this patient had a favorable clinical outcome, this case nevertheless emphasizes that judicious prescribing of corticosteroid therapy is paramount to potentially preventing injuries such as these.

Key words: avascular necrosis – capitellum – corticosteroid – fracture – osteonecrosis

Abstrakt

Prípady kapitelárných zlomenín sú vzácné a doposiaľ bolo písaných len niekoľko prípadov bilaterálneho zranenia. Kortikosteroidmi indukovaná avaskulárna nekróza (AVN) je najčastejšou príčinou netraumatickej AVN, no ochorenie postihujúce capitulum humeri je veľmi nezvyklé. Opisujeme prípad bilaterálnej kapitelárnej fraktúry u ženy vo veku približne 35 rokov liečenej vysokými dávkami kortikosteroidov pre podozrenie na uveitídu. V priebehu niekoľkých týždňov utrpela takmer identické koronálne orientované šmykové zlomeniny oboch hlavičiek, ktoré boli liečené intraoseálnou skrutkovou fixáciou a skorou aktívnou mobilizáciou. Prezentovaná kazuistika je prvá kazuistika, ktorá opisuje bilaterálnu kapitelárnu zlomeninu na pozadí užívania kortikosteroidov. Aj keď mala priaznivé klinické výsledky, napriek tomu tento prípad zdôrazňuje, že pre prevenciu potencionálnych zranení tohto typu je zásadné uvážlivé predpisovanie kortikosteroidov.

Klíčovú slová: avaskulárna nekróza – kapitulum – kortikosteroid – osteonekróza – zlomenina

Introduction

Capitellar fractures are an uncommon phenomenon, constituting only 1–1.6 % of elbow fractures [1]. They are frequently described according to their subtype using the Bryan-Morrey classification. The most common are

type I (Hahn-Steinthal) coronal shear fractures, which are comprised of a large osseous fragment of capitellum, while type II (Kocher-Lorenz or Mouchet) fractures are composed of a thin curved portion of cartilage and underlying subchondral bone [1,2]. Type III fractures en-

compass comminuted capitellar fractures, while type IV fractures are similar to type I, however require concomitant fracture of the trochlea and are the second most common subtype [1,2].

The mechanism of injury has classically been described as a fall from standing height onto an outstretched hand with the elbow in a partially flexed or extended position [3,4]. An axial shear stress is subsequently transmitted to the capitellum via the radial head, thus resulting in the typical coronally oriented fracture line [1,3,5]. Other mechanisms implicated in capitellar fracture include direct blow to the elbow during a fall, fall from height and road traffic accidents, with the latter two frequently associated with additional elbow injuries rather than being isolated to the capitellum [1,2,5,6,7]. Females are more commonly affected by capitellar fractures, with a series reported by Watt and colleagues documenting a female preponderance of 70 % (55 of 79), most commonly affecting women aged over 80, and to a lesser degree aged less than 20 [2]. Females were most likely to sustain a capitellar fracture following fall from standing height, the mechanism in 91 % (48 of 53) of cases [2].

Given the infrequency of capitellar fractures, reports of bilateral capitellar fractures are exceedingly uncommon. This article describes a case of metachronous bilateral capitellar fracture in a female aged in her mid-thirties.

Case report

A female aged in her mid-thirties was admitted to the Emergency Department with right elbow pain following a fall onto both outstretched hands while roller skating. Notably, the patient had been intermittently treated

with high dose oral steroids for suspected uveitis over a period of approximately four months preceding this presentation. This included doses of up to 50 milligrams (mg) of Prednisolone daily. The patient was otherwise well, took no other regular medications, and did not have a history of fracture. She was previously a light smoker, which she had only recently ceased, while her alcohol intake was not elicited.

Digital radiographs demonstrated a right capitellar fracture. Computed tomography (CT) was undertaken to further characterize the injury and for operative planning, which confirmed a displaced coronally oriented shear fracture of the capitellum (figure 1). Surgical fixation of the capitellum via a Kaplan approach was subsequently performed using two Acumed Acutrak Mini screws (Acumed, Hillsboro, Oregon, USA). Post-operative radiographs demonstrated satisfactory fracture reduction and metalware position (figure 2). The patient was encouraged to commence mobilization of the elbow immediately, however was restricted to only light weight-bearing with her right upper limb for six weeks. At the two week wound review, the patient was progressing well with minimal pain, active elbow extension to 20 degrees, flexion to 150 degrees, and unrestricted pronation and supination.

The patient then re-presented to the Emergency Department several weeks after her initial injury following a mechanical fall onto her outstretched left hand. Digital radiography demonstrated a capitellar fracture, with CT again utilized for operative planning by further characterizing the fracture. CT demonstrated a near identical fracture to that of the previously injured right side (figure 3). Surgical fixation was undertaken with

Figure 1 | Sagittal CT image of the right elbow demonstrating a type I capitellar fracture

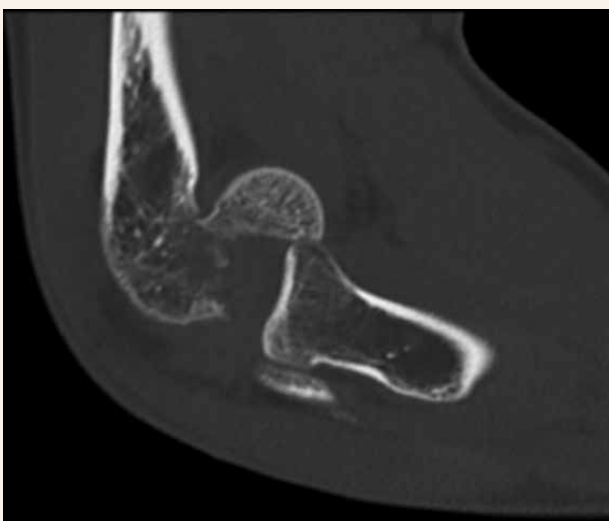
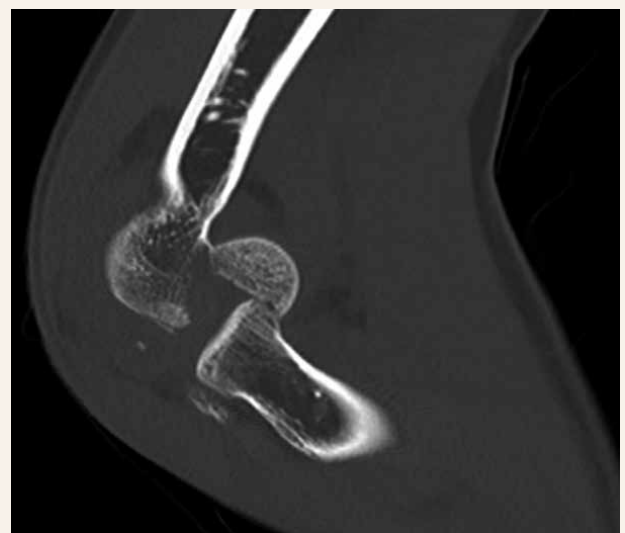

Figure 2 | Sagittal CT image of the left elbow demonstrating a near identical type I capitellar fracture to that of the right elbow



the use of two Medartis SpeedTip screws (Medartis, Basel, Switzerland) via a modified Kaplan approach (figure 4). It was noted intra-operatively that the fracture fragment was sclerotic and avascular in appearance, concerning for avascular necrosis (AVN). Identical post-operative orders were given regarding range of motion and weight-bearing status. The patient was reviewed two weeks post-operatively, demonstrating active left elbow extension to 20 degrees and flexion to 90 degrees. Regular physiotherapy resulted in excellent functional recovery, with full range of motion regained in both elbows six months postsurgical fixation of the left capitellum. The patient reported no ongoing pain. Radiographs taken prior to clinic review demonstrated good anatomical alignment with union bilaterally, with no overt features to suggest the presence of AVN. The patient was subsequently discharged from the Orthopedic Clinic.

Discussion

While cases of bilateral capitellar fracture and cases of bilateral capitellar AVN in the setting of steroid use have rarely been reported [5,6,8–11], to the author's knowledge, this is the first published case report of bilateral capitellar fracture in the setting of corticosteroid therapy.

Corticosteroid use has long been associated with AVN, however there is limited literature reporting on steroid-induced AVN of the capitellum. Le and colleagues performed a single center review of AVN of the elbow, with the capitellum affected in six out of 1,241 patients [12]. While the capitellum was the most common site for AVN in the elbow, it remains an exceedingly rare

entity, representing only 0.48 % of all AVN cases [12]. Significantly, all six patients had a history of corticosteroid use, however there was no relationship found between steroid dose and duration and the extent of AVN [12].

Although traumatic fracture has extensively been implicated as a precursor for the development of AVN [13], a reciprocal association between AVN and predisposition to traumatic fracture is not readily recognized, save for a single case report and equine studies [14,15]. This is despite extensive literature describing subchondral fracture and bone collapse in the setting of AVN, particularly with regards to the femoral head [13,16,17]. Although areas of AVN undergo a reparative phase, trabecular resorption exceeds bone formation, thus precipitating a reduction in structural integrity [18]. Given that the pathogenesis of bony collapse secondary to AVN has been proposed to occur via cumulative fatigue-induced microfractures, trabecular weakness from osteoclast activity, and stress within the trabeculae [19], it is somewhat surprising that a link between non-traumatic AVN and predisposition to traumatic fracture has only seldom been reported. Given the uniqueness of the injury described in this case, it is felt that corticosteroids were potentially a contributing factor through a reduction in capitellar structural integrity prior to the patient's falls, which then predisposed to traumatic fracture through this region. This was supported by the intraoperative appearance of the capitellum, and the absence of other obvious risk factors. Although imaging did not reveal any evidence of AVN in the case we have described, plain radiographs and CT are insensitive to detecting changes early in the disease process [13]. Furthermore, it is underpinned by the fact that, unlike the majority of other case reports of bilateral capitellar fracture which occurred in the setting of

Figure 3 | Post-operative radiograph of the right elbow (lateral view) illustrating satisfactory reduction of the capitellar fragment with two intraosseous screws

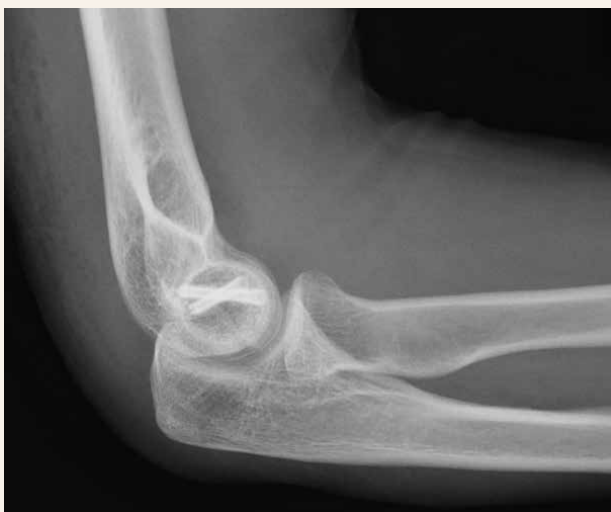
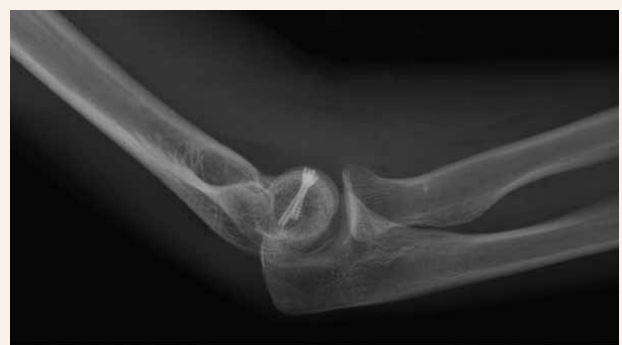
Figure 4 | Post-operative radiograph of the left elbow (lateral view) demonstrating two intraosseous screws providing reduction of the capitellar fragment



higher energy trauma [5,6,8], both fractures occurred following a fall from standing height.

Conclusion

This report describes a case of traumatic bilateral capitellar fracture in a patient taking corticosteroids. Given the inherent limitations of a case report, there is insufficient evidence to definitively determine a causal relationship between corticosteroid administration and these injuries. However, it is highly conceivable that corticosteroid therapy was a predisposing factor through loss of capitellar structural integrity given the fact that steroid-induced capitellar AVN is a previously described entity, the intraoperative appearance of the capitellum in this case, the extreme rarity of bilateral capitellar fracture, and the use of high dose corticosteroid therapy with no history of fracture prior to its commencement. Regardless this case reinforces the need for judicious prescribing of these medications to prevent common, but also rare and potentially devastating injuries such as those described. In keeping with previous literature, this case demonstrates the utility and favorable outcomes of operative fixation with intraosseous screws, combined with early mobilization.

References

1. Suenghwan J, Morrey B. Distal humerus fractures: isolated fracture of the capitellum. In: Morrey B, Sanchez-Sotelo J, Morrey M (ed). *Morrey's the elbow and its disorders*. 5th ed. Elsevier: Philadelphia 2017: 458–465. ISBN 978–0323341691.
2. Watts A, Morris A, Robinson C. Fractures of the distal humeral articular surface. *J Bone Joint Surg Br* 2007; 89(4): 510–515. Available on DOI: <<http://dx.doi.org/10.1302/0301-620X.89B4.18284>>.
3. Cheung E. Fractures of the capitellum. *Hand Clin* 2007; 23(4): 481–486. Available on DOI: <<http://dx.doi.org/10.1016/j.hcl.2007.08.001>>.
4. McKee M, Jupiter J, Bamberger H. Coronal shear fractures of the distal end of the humerus. *J Bone Joint Surg Am* 1996; 78(1): 49–54. Available on DOI: <<http://dx.doi.org/10.2106/00004623-199601000-00007>>.
5. Polat O, Arikan M, Gungor S et al. Bilateral capitellum humeri fracture: a case report. *Acta Chir Belg* 2009; 109(5): 647–650. Available on DOI: <<http://dx.doi.org/10.1080/00015458.2009.11680508>>.
6. Are A, Tornatore I, Theodorakis E. Operative management of a shear fracture of the bilateral capitellum: a case report and review of the literature. *Chin J Traumatol* 2016; 19(4): 231–234. Available on DOI: <<http://dx.doi.org/10.1016/j.cjtee.2015.11.017>>.
7. Rausch V, Konigshausen M, Schildhauer T et al. Fractures of the capitellum humeri and their associated injuries. *Obere Extrem* 2018; 13(1): 33–37. Available on DOI: <<http://dx.doi.org/10.1007/s11678-018-0441-9>>.
8. Corominas L, Sanpera J, Rodriguez De La Rubia E. An atypical case of elbow fracture: bilateral capitellum humeri fracture in a teenager. *Acta Orthop Belg* 2016; 82(4): 930–935.
9. Sturridge S, Corbett S. Bilateral type 1 capitellar fracture: a case report. *Ann R Coll Surg Engl* 2010; 92(7): 28–29. Available on DOI: <<http://dx.doi.org/10.1308/147870810X12699662981717>>.
10. Schindler O. Bilateral capitellum humeri fracture: a case report and review of the literature. *J Orthop Surg (Hong Kong)* 2003; 11(2): 207–212. Available on DOI: <<http://dx.doi.org/10.1177/230949900301100218>>.
11. Beyer C, Beckenbaugh R. Bilateral capitellar steroid-induced avascular necrosis. *Orthopedics* 1993; 16(4): 480–483.
12. Le T, Mont M, Jones L, et al. Atraumatic osteonecrosis of the elbow. *Clin Orthop Relat Res* 2000; (373): 141–145. Available on DOI: <<http://dx.doi.org/10.1097/00003086-200004000-00017>>.
13. Steinberg M, Steinberg D. Osteonecrosis: historical perspective. In: Koo K-H, Mont M, Jones L (ed). *Osteonecrosis*. 1st ed. Springer: Berlin 2014: 3–15. ISBN 978–3642357664.
14. Vaidyanathan S, Murugan Y, Paulraj K. An unusual complication in osteonecrosis of femoral head: a case report. *Case Rep Orthop* 2013. 2013: 313289. Available on DOI: <<http://dx.doi.org/10.1155/2013/313289>>.
15. Kaneko M, Oikawa M, Yoshihara T. Pathological analysis of bone fractures in race horses. *J Vet Med Sci* 1993; 55(1): 181–183. Available on DOI: <<http://dx.doi.org/10.1292/jvms.55.181>>.
16. Koo K-H, Lee Y-K, Lee Y. Pathophysiology of ischemic diseases of the hip: osteonecrosis, borderline necrosis, and bone marrow edema syndrome. In: Koo KH, Mont M, Jones L (ed). *Osteonecrosis*. 1st ed. Springer: Berlin 2014: 143–149. ISBN 978–3642357664.
17. Banerjee S, Kapadia B, Jauregui J et al. Natural history of osteonecrosis. In: Koo K-H, Mont M, Jones L (ed). *Osteonecrosis*. 1st ed. Springer: Berlin 2014: 161–164. ISBN 978–3642357664.
18. Aaron R, Voisin A, Racine J et al. Corticosteroid-associated avascular necrosis: dose relationships and early diagnosis. *Ann N Y Acad Sci* 2011; 1240: 38–46. Available on DOI: <<http://dx.doi.org/10.1111/j.1749-6632.2011.06218.x>>.
19. Bullough P, DiCarlo E. Subchondral avascular necrosis: a common cause of arthritis. *Ann Rheum Dis* 1990; 49(6): 412–420. Available on DOI: <<http://dx.doi.org/10.1136/ard.49.6.412>>.