

Multiple Metachronous Malignant Fibrous Histiocytomas of the Upper Limbs – a Case Report

Mnohopočetný metachrónny malígny fibrózny histiocytóm na horných končatinách – kazuistika

Scepanovic D., Masarykova A., Pobijakova M., Hanicova A., Fekete M.

Department of Radiation Oncology, National Cancer Institute, Bratislava, Slovak Republic

Summary

Background: Soft-tissue sarcomas are rare tumors with the incidence of multiple metachronous or synchronous lesions in the extremities being even more uncommon. In effort to preserve the function of upper extremities, limb-salvage surgery became the treatment of choice for soft-tissue sarcomas. Subsequent adjuvant chemotherapy, as well as radiotherapy, is believed to decrease local recurrence rates, however, their effect on overall survival remains unclear.

Case: We report herein a case of symmetrical bilateral metachronous malignant fibrous histiocytomas of the shoulder. A 19-year-old patient presented with stiffness and pain in the right shoulder. The same symptoms developed 1.5 years later in the other shoulder. The culprit tumors are reported metachronous with regard to the succession in the onset of symptoms. Wide tumor resection was performed in both shoulders, and postoperative radiotherapy was then conducted. Chemotherapy was not indicated after the first surgery; whereas, in the second case it was the patient who refused the recommended adjuvant chemotherapy. **Conclusion:** The phenomenon of either metachronous or synchronous incidence of multiple soft tissue sarcomas is very rare and systematic reporting of every new case in the literature could contribute to further knowledge of tumor's unique behavior.

Key words

malignant fibrous histiocytoma – radiotherapy – upper extremity – neoplasms – multiple primary

Súhrn

Úvod: Sarkómy mäkkých tkanív sú zriedkavé nádory. Medzi nimi mnohopočetné metachrónne alebo synchronne sarkómy mäkkých tkanív končatín sú obzvlášť vzácne. Končatinu zachováajúca chirurgia je terapia voľby u sarkómov mäkkých tkanív, aby sa zachovala funkčnosť horných končatín. Po rozsiahlej resekcii tumoru môže adjuvantná terapia, teda chemoterapia a rádioterapia, znížiť počet lokálnych recidív, ale jej vplyv na celkové prežívanie pacientov zostáva nejasný. **Kazuistika:** V tejto kazuistike sme ukázali prípad mnohopočetných symetrických, metachronných malígnych fibróznych histiocytómov lokalizovaných na oboch ramenách. Prezentovaná je 19-ročná pacientka, ktorá pociťovala napätie a bolesť v pravom ramene. Rovnaké príznaky sa vyvinuli aj v ľavom ramene asi 1,5 roka neskôr. Nádory v ramenách u pacientky boli definované ako metachronné z dôvodu rôznych časových intervalov stanovenia diagnózy. Široká resekcia tumoru bolo vykonaná v oboch ramenách, následne bola aplikovaná pooperačná rádioterapia. Chemoterapia nebola doporučená po prvej operácii; avšak, pacientka odmietla adjuvantnú chemoterapiu po druhej operácii. **Záver:** Fenomén mnohopočetných sarkómov mäkkých tkanív, buď metachronných, alebo synchronných je veľmi zriedkavý. Preto sa domnievame, že každý nový prípad by mal byť opísaný.

Klíúčové slová

malígny fibrózny histiocytóm – rádioterapia – horná končatina – mnohopočetné primárne nádory

The authors declare they have no potential conflicts of interest concerning drugs, products, or services used in the study.

Autoři deklarují, že v souvislosti s předmětem studie nemají žádné komerční zájmy.

The Editorial Board declares that the manuscript met the ICMJE "uniform requirements" for biomedical papers.

Redakční rada potvrzuje, že rukopis práce splnil ICMJE kritéria pro publikace zasílané do biomedicínských časopisů.



Danijela Scepanovic, MD, PhD
Department of Radiation Oncology
National Cancer Institute
Hlavacikova 26
841 05 Bratislava
Slovak Republic
e-mail: danijelascepanovic@hotmail.com

Submitted/Obdrženo: 14. 7. 2014

Accepted/Prijato: 28. 9. 2014

<http://dx.doi.org/10.14735/amko2014438>

Backgrounds

Soft-tissue sarcoma (STS) is a rare tumor with estimated incidence around 3.0–4.5 per 100,000 individuals [1]. STS accounts for only 1% of all malignancies in adult patients with 60% of STS tumors being located in the extremities. STS constitutes a heterogeneous group of neoplasms of mesenchymal origin, often with a distinct age distribution, site of presentation, natural biological behavior and prognosis [2,3]. The most common types of STS of the upper extremities are epithelioid sarcoma, synovial cell sarcoma, and malignant fibrous histiocytoma (MFH). MFH is a common histologic subtype of this uncommon clinical entity. The origin of the term “malignant fibrous histiocytoma” dates back to the early 1960s. Murray [4] observed that STS cell cultures were characterized by a storiform (i.e. cartwheel-like) growth pattern with pleomorphic and giant tumor cells that displayed amoeba-like movement and phagocytosis. These features were reminiscent of his-

tiocytes (i.e. macrophages of local resident tissue) and gave rise to the term “malignant fibrous histiocytoma” that soon became established in the literature. MFH was further subdivided into five types: 1. storiform-pleomorphic, 2. myxoid (myxofibrosarcoma), 3. giant cell (malignant giant cell tumor of soft parts), 4. inflammatory, and 5. angiomatoid MFH. The inflammatory subtype is the rarest variant constituting 5% of all cases. This tumor presents with a distinctive inflammatory infiltrate comprising neutrophils, lymphocytes, and foamy histiocytes. In 2002 World Health Organization reclassified the inflammatory MFH as “undifferentiated pleomorphic sarcoma with prominent inflammation” [4].

As for the association of STS with other malignancies, this was recorded in patients with genetic disorders such as neurofibromatosis, familial adenomatous polyposis, retinoblastoma, and Li-Fraumeni syndrome. Moreover, several studies have suggested that patients with STS are at an increased

risk of developing a second malignancy, notably breast and kidney cancer, regardless of any underlying genetic disorder present [5–7]. Most cases of STS in adult patients (94%) are not significantly related to common risk factors such as radiation, genetic disease, and chronic lymphedema [1]. Multiple metachronous and synchronous STS of the extremities are very rare. In the study of Murray et al [7], only 4 of 1,201 patients presented with symmetrical bilateral STS of the extremities. The authors encourage physicians in awareness of these sarcomas and their characteristics in order to avoid neglect, since these tumors are typically misdiagnosed and treatment is delayed [7]. Magnetic resonance imaging (MRI) is the imaging modality of choice for the initial staging, as well as further follow-up of sarcomas. Although imaging itself usually cannot reliably predict the histopathological diagnosis or distinguish benign from malignant processes, in combination with clinical history and epidemiologic features of various tumors, it can help to narrow the list of differential diagnoses. In patients with STS, MRI plays a crucial role in outlining the lesion and its relationship to adjacent anatomic structures [8].

The goal of treatment of musculoskeletal sarcomas is to optimize the oncologic outcome without impeding limb's functional status. Surgical resection remains the mainstay of therapy. In patients with musculoskeletal sarcomas of the extremities, limb-sparing resection was proved significantly superior to amputation. Furthermore, wide local excision of the tumor encompassing the muscular compartment, followed by adjuvant chemotherapy and radiation therapy was not associated with an increased risk of recurrence in these patients. Yet, the influence of this treatment on overall survival remains unclear [7,9].

Case

In October 2011, a 19-year-old female patient was referred to the Orthopaedic and Traumatology Clinic of Medical School, Comenius University and Slovak Medical University in Bratislava for

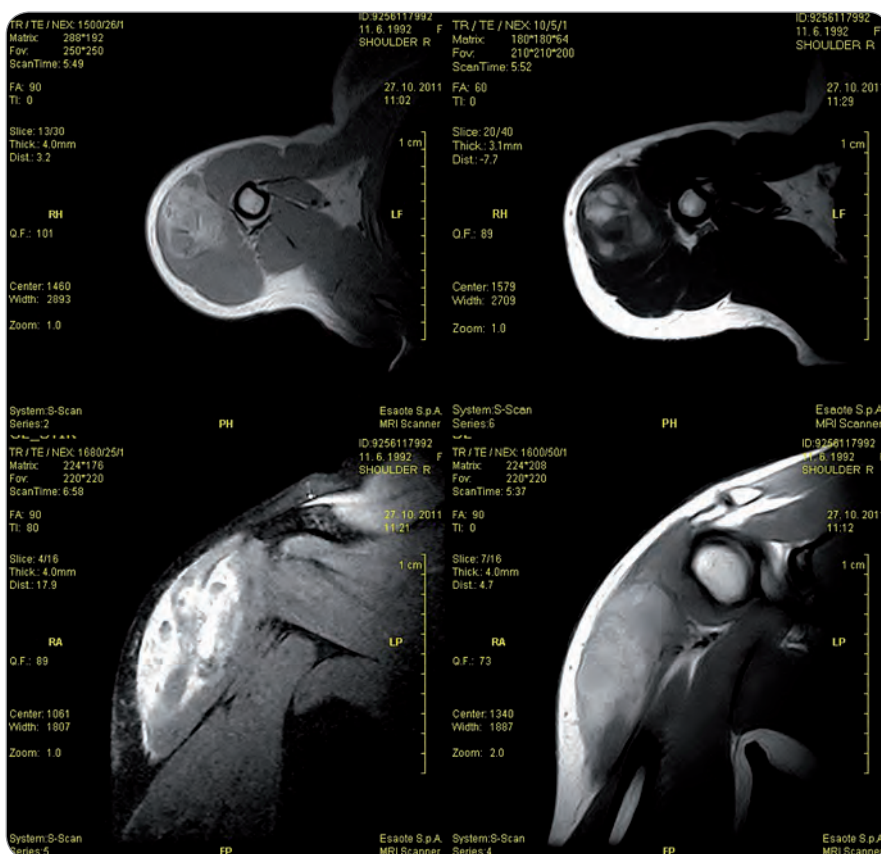


Fig. 1. Magnetic resonance image of right upper limb.

Again, we used a multileaf collimator (80 leaves, 40 × 40) and 6-MV X-ray energy on a linear accelerator (Elekta Synergy; Elekta AB) and planned the radiotherapy by co-registration of the preoperative MRI and postoperative planning CT. The patient refused to undergo adjuvant chemotherapy. She finished radiotherapy on 2 July 2013, and to date, she has exhibited neither signs of local recurrence, nor any distant metastases.

STS is a rare malignancy with an annual incidence of 3 per 100,000 individuals. Although the risk for patients with STS to develop a second malignancy is 12.5 times higher than in individuals with no history of the sarcoma, the occurrence of multiple primary STS in one patient is still uncommon [5,10]. There are many possible explanations for the appearance of multiple primary tumors in the same individual. It was proposed that these patients may have a genetic predisposition to malignant disease, or they may have been exposed to carcinogens [5]. Reports of multiple primary sarcomas unassociated with a predisposing syndrome (e.g. neurofibromatosis, familial adenomatous polyposis, retinoblastoma, or Li-Fraumeni syndrome) are rather anecdotal, particularly those referring to tumors localized in soft tissues of the extremities [6,11,12]. Daigeler et al [6] presented an interesting notion of the subsequent occurrence of a STS being an atypical manifestation of metastatic disease. With respect to the differentiation between a true synchronous, independently developed soft tissue sarcoma and its metastases, this might seem plausible,

especially if soft-tissue metastasis of a primary STS is quite a usual phenomenon (e.g. in cases of myxoid or round-cell liposarcoma) [7,13].

As a matter of fact, according to the new WHO classification from 2013, malignant fibrous histiocytoma was not accepted as a distinct histopathological unit and many of these tumors have now been reclassified into specific sarcoma subtypes. For a long time, malignant fibrous histiocytomas accounted for approximately 50% of sarcoma diagnoses. It took several years to discover that besides several subtypes of pleomorphic sarcomas (leiomyosarcomas, rhabdomyosarcomas, dedifferentiated liposarcoma etc.), this label included unrelated diagnoses such as lymphomas, malignant melanomas and sarcomatoid variants of carcinomas [14].

In this paper, we report a case of multiple metachronous MFH localized symmetrically in both shoulders. The tumors were defined as metachronous because their diagnosis and treatment occurred within a timespan of 1.5 years. This case is also unique because of the symmetrical development of STS bilaterally in the upper limbs. It is noteworthy that our patient had no familial disposition, no history of previous exposure to carcinogenic substances or irradiation.

Conclusion

The phenomenon of either metachronous or synchronous incidence of multiple soft tissue sarcomas is very rare and systematic reporting of every new case in the literature could contribute to further knowledge of tumor's unique behavior.

References

1. Penel N, Grosjean J, Robin YM et al (eds). Frequency of certain established risk factors in soft tissue sarcomas in adults: a prospective descriptive study of 658 cases [monograph on the Internet]. Hindawi Publishing Corporation Sarcoma 2008. Available from: <http://www.hindawi.com/journals/sarcoma/2008/459386/>.
2. Grimer R, Judson I, Peake D et al (eds). Guidelines for the management of soft tissue sarcomas [monograph on the Internet]. Hindawi Publishing Corporation Sarcoma 2010. Available from: <http://www.hindawi.com/journals/sarcoma/2010/506182/>.
3. Salo JC, Lewis JJ, Woodruff JM et al. Malignant fibrous histiocytoma of the extremity. *Cancer* 1999; 85(8): 1765–1772.
4. Matushansky I, Charytonowicz E, Mills J et al. MFH classification: differentiating undifferentiated pleomorphic sarcoma in the 21st century. *Expert Rev Anticancer Ther* 2009; 9(8): 1135–1144. doi: 10.1586/era.09.76.
5. Grobmyer SR, Luther N, Antonescu CR et al. Multiple primary soft tissue sarcomas. *Cancer* 2004; 101(11): 2633–2635.
6. Daigeler A, Lehnhardt M, Sebastian A et al. Metachronous bilateral soft tissue sarcoma of the extremities. *Langenbecks Arch Surg* 2008; 393(2): 207–212.
7. Murray PM. Soft tissue sarcoma of the upper extremity. *Hand Clin* 2004; 20(3): 325–333.
8. Singh AK, Shirkhoda A, Gupta T et al (eds). MR imaging of upper extremity sarcomas [monograph on the Internet]. The Free Library 2006 Anderson Publishing Ltd. Available from: <http://www.thefreelibrary.com/MR+imaging+of+upper+extremity+sarcomas.-a0209239079>.
9. Moreira-Gonzalez A, Djohan R, Lohman R. Considerations surrounding reconstruction after resection of musculoskeletal sarcomas. *Cleve Clin J Med* 2010; 77 (Suppl 1): S18–S22.
10. Jemal A, Tiwari RC, Murray T et al. Cancer statistics, 2004. *CA Cancer J Clin* 2004; 54(1): 8–29.
11. Merimsky O, Kollender Y, Issakov J et al. Multiple primary malignancies in association with soft tissue sarcomas. *Cancer* 2001; 91(7): 1363–1371.
12. Bridge JA, Sandberg AA. Cytogenetic and molecular genetic techniques as adjunctive approaches in the diagnosis of bone and soft tissue tumors. *Skeletal Radiol* 2000; 29(5): 249–258.
13. Antonescu CR, Elahi A, Healey JH et al. Monoclonality of multifocal myxoid liposarcoma: confirmation by analysis of TLS-CHOP or EWS-CHOP rearrangements. *Clin Cancer* 2000; 6(7): 2788–2793.
14. Doyle LA. Sarcoma classification: an update based on the 2013 World Health Organization Classification of Tumors of Soft Tissue and Bone. *Cancer* 2014; 120(12): 1763–1774. doi: 10.1002/cncr.28657.