

# Current Two EGFR Mutations in Lung Adenocarcinoma – Case Report

## Současné dvě EGFR mutace u plicního adenokarcinomu – kazuistika

Svaton M.<sup>1</sup>, Pesek M.<sup>1</sup>, Chudacek Z.<sup>2</sup>, Vosmiková H.<sup>3</sup>

<sup>1</sup> Department of Pneumology, Charles University in Prague, Faculty of Medicine in Pilsen, University Hospital Pilsen, Czech Republic

<sup>2</sup> Department of Radiology, Charles University in Prague, Faculty of Medicine in Pilsen, University Hospital Pilsen, Czech Republic

<sup>3</sup> Department of Pathology, Charles University in Prague, Faculty of Medicine in Hradec Kralove, University Hospital Hradec Kralove, Czech Republic

### Summary

Nowadays, EGFR-TKIs (epidermal growth factor receptor-tyrosine kinase inhibitors) targeted therapy is well established treatment for patients with the so-called EGFR common mutations with advanced or metastatic non-small cell lung cancer. The efficacy for the so-called rare and especially for the very rare complex EGFR mutations is not clear. We describe a case of a 63-year-old female with metastatic non-small cell lung cancer with complex EGFR mutation (G719X + S768I) who had been treated by gefitinib. She achieved progression free survival within eight months. Then, we discuss our case with other literature case reports. Together, it seems that described complex EGFR mutation has a relatively good sensitivity for EGFR-TKIs treatment.

### Key words

non-small cell lung cancer – EGFR gene – EGFR protein – complex mutations – rare EGFR mutations – EGFR-TKIs

### Souhrn

Cílená terapie pomocí EGFR-TKIs (epidermal growth factor receptor-tyrosine kinase inhibitors) je v současné době dobře zavedenou léčbou pro pacienty s tzv. častými EGFR mutacemi s pokročilým nebo metastatickým nemalobuněčným karcinomem plic. Účinnost této léčby pro tzv. vzácné a obzvláště pak pro tzv. komplexní EGFR mutace není zcela jasná. V naší kazuistice popisujeme případ 63leté ženy s metastatickým nemalobuněčným karcinomem plic s komplexní EGFR mutací (G719X + S768I), která byla léčena gefitinibem. Doba do progresu dosáhla osm měsíců. Následně diskutujeme naši kazuistiku s literárně zveřejněnými obdobnými případy. Celkově se zdá, že popisovaná komplexní mutace má relativně dobrou citlivost pro léčbu pomocí EGFR-TKIs.

### Klíčová slova

nemalobuněčný karcinom plic – EGFR gen – EGFR protein – complex mutations – rare EGFR mutations – EGFR-TKIs

The authors declare they have no potential conflicts of interest concerning drugs, products, or services used in the study.

Autoři deklarují, že v souvislosti s předmětem studie nemají žádné komerční zájmy.

The Editorial Board declares that the manuscript met the ICMJE "uniform requirements" for biomedical papers.

Redakční rada potvrzuje, že rukopis práce splnil ICMJE kritéria pro publikace zasílané do biomedicínských časopisů.



**Martin Svaton, MD, Ph.D.**

Department of Pneumology  
Charles University in Prague  
Faculty of Medicine in Pilsen  
University Hospital Pilsen  
dr. Edvarda Beneše 13  
305 99 Pilsen  
Czech Republic  
e-mail: svatonm@gmail.com

Submitted/Obdrženo: 24. 11. 2014

Accepted/Přijato: 4. 2. 2015

<http://dx.doi.org/10.14735/amko2015134>

## Introduction

Lung cancer is the leading and main cause of death associated with malignancies worldwide [1]. However, the prognosis of a patient differs greatly according to the type and stage of the tumor [2]. Mutations in the gene for *epidermoid growth factor receptor (EGFR)* were detected as strong predictive and prognostic markers in NSCLC [2,3]. *EGFR* mutations were found approximately in 10% to 20% of the Caucasian population and from 30% to 60% of the Asian population with NSCLC [4]. Their frequent occurrence was demonstrated in adenocarcinoma, women and non-smokers [5,6]. Exon 19 deletions and point mutations in exon 21 constitute 80–90% of *EGFR* mutations [7,8]. These mutations are known as common mutations. Other remaining mutations are known as rare mutations. Their predictive value is often not clear. *EGFR* mutations may also occur in combination, either as two common, common and rare or two rare mutations together [5]. We present a case report of a patient with two rare mutations treated with gefitinib.

## Case report

A patient, 63-year-old woman, smoker (40 pack for years) without any severe comorbidities, diagnosis – adenocarci-

noma of the lower lobe of left lung with multiple bilateral lung metastasis, mediastinal lymphadenopathy and solid metastasis to liver and to thoracic vertebra (Th7) was established. Adenocarcinoma was verified histologically in the regional hospital. The diagnosis was staged as T1N2M1b, stage IV (Fig. 1). Genetic testing from obtained histological sample was performed in an accredited laboratory of university hospital by Cobas (using RT-PCR technology) and confirmed by direct PCR sequencing. These methods revealed an activating double *EGFR* mutation (S768I on exon 20 plus G719X on exon 18). The patient was treated with gefitinib in a standard dose of 250 mg per day from October 2013. We observed regression of tumor through X-ray and also milder symptoms of the patient (dyspnoe, cough, loss of weight) a month later.

Regression of the primary tumor was confirmed using CT scans (Fig. 2) in February 2014, at the same time obviously fewer lung metastases were detected, mediastinal lymphadenopathy disappeared as well as liver metastases.

The next controls established disease stabilization until June 2014. In June, progression of lung metastases and especially novel multiple brain metastasis (Fig. 3, 4) were described on CT

scans. Therefore, the treatment with gefitinib (which was very well tolerated) was finished after eight months. The patient was transferred back to the regional hospital with proposal of palliative radiation of cranial metastases and proposal of initiation of the 2<sup>nd</sup> line treatment.

## Discussion

Sensitive mutation of *EGFR* (*EGFR* M+) represents a significant predictive factor for treatment of *EGFR*-TKI [9]. In *EGFR* M+ patients, gefitinib and erlotinib demonstrated improvement in objective response rate (ORR) and time to disease progression (PFS) compared with established chemotherapy [10]. Therefore, *EGFR*-TKIs is considered as the standard treatment for these patients in the 1<sup>st</sup> line. In a lot of large studies, deletion of exon 19 and the L858R point mutation in exon 21 were confirmed as sensitive mutations [8]. However, there is a number of other, so-called rare mutations in exons 18 to 21 of the *EGFR* gene [7,8]. Response to treatment has not been clearly determined yet because of small number of patients [8], but literature for the special mutation can show at least a trend in response to treatment with *EGFR*-TKI.

Rare mutations are described in the literature, approximately in 10%

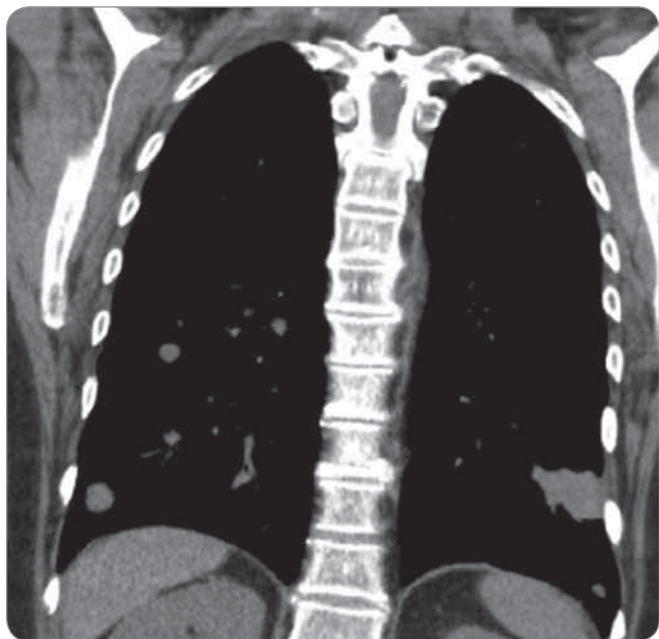


Fig. 1. Input CT of lung and mediastinum (8/2013).

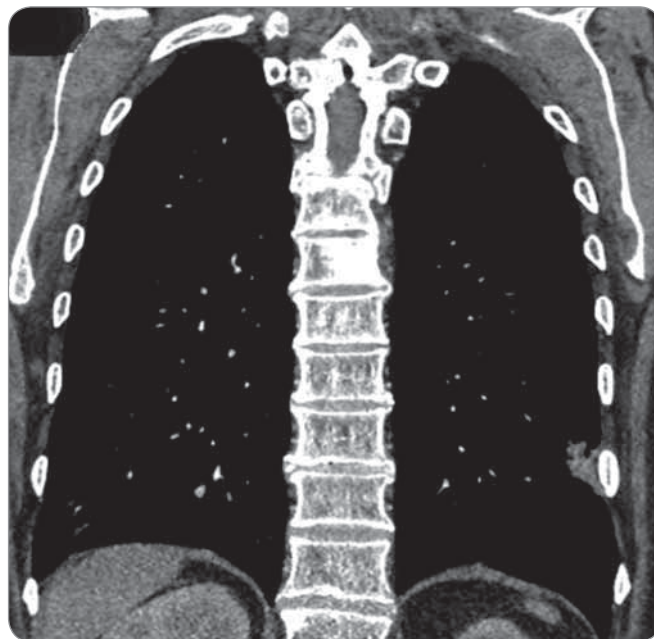


Fig. 2. Control CT of lung and mediastinum – regression of tumor (2/2014).

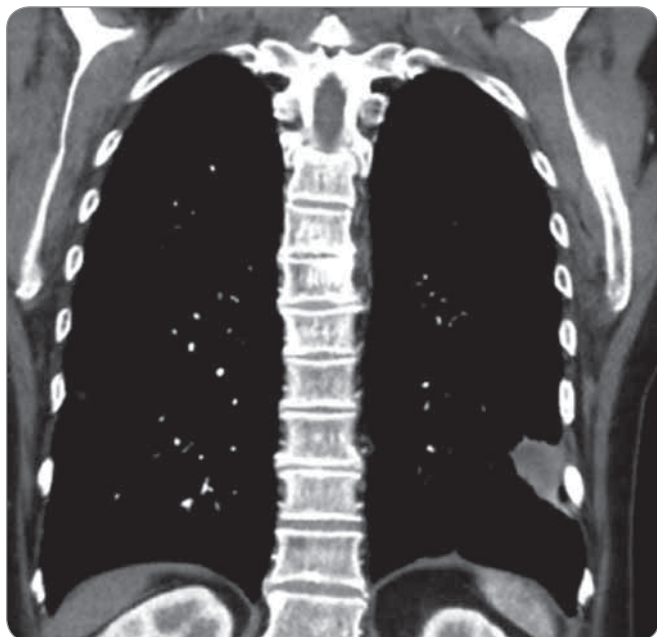


Fig. 3. Control CT of lung and mediastinum – progression of tumor (6/2014).

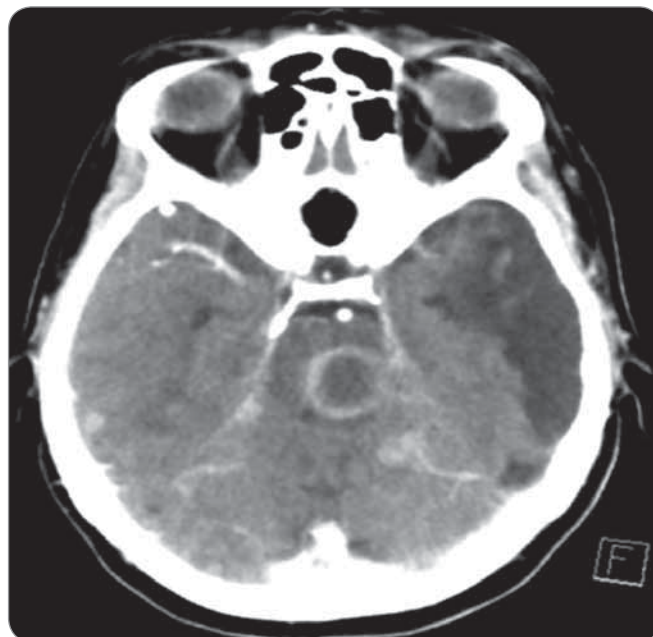


Fig. 4. CT of brain with metastatic proces (6/2014).

of cases [11,12]. G719X and L861X, described in our patient, are among the more frequent of them [8,13–15]. G719X mutation occurs in approximately 3% of EGFR M+ patients and several patients treated with EGFR-TKIs have been described [4,8,12,13,16]. Response to treatment is published from approximately one third to approximately 55% [4,8,12,13]. PFS of these patients is also described as a very heterogenous – from less than three months to eight months [4,12].

Compared with classical mutations, a decreased sensitivity of this mutation to EGFR-TKIs was proven *in vitro* [16,17]. Higher sensitivity has been described for EGFR of higher generations [10,12]. Difference in PFS can be caused by different subtypes of G719X mutation, but clear evidence is lacking [1,12,17]. S678X mutation has ORR about 50–60% [4,8]. PFS is usually also shorter than in patients with classical mutations [4,12]. Higher concentrations of EGFR-TKIs to induce a response are necessary *in vitro* [12]. Generally, mutations G719X and L861X are considered as moderately sensitive to EGFR-TKIs, both *in vitro* [4,17] and *in vivo* [9].

G179X and L861Q quite often appeared as a complex mutation – G719X up to 50% and L861X to 25% [13]. Together

with classical EGFR mutations (especially L858R), they belong to the most common ‘components’ of complex mutations [13]. Apparently, the above mentioned fact can show that the composition of these mutations will result in complex mutations partially sensitive to the EGFR-TKI. However, as evidenced in the literature, complex mutations should be considered separately as independent units and not as ‘composition’ of two individual mutations [6,18]. It is due to resulting changes in the spatial distribution of EGFR molecule in complex mutations [18]. Generally, two frequent mutations together have the same or better response to EGFR-TKI, frequent mutation with rare (non-resistant) mutation usually shows equal sensitivity and two rare (non-resistant) mutations show slightly lower sensitivity to EGFR-TKI [8]. Relatively common complex mutation G719X + L861X was described by several authors [2,4,8,19–21], where EGFR-TKI was administered in some of these cases. Keam et al treated one patient with this mutation with gefitinib, PFS reached 7.9 months and OS time was not reached after 26 months of patient’s observation [8]. Lund-Iversen et al then achieved even a better result when the patient was treated for 14 months until progression of the

disease [2]. Wu et al then described low efficacy when one patient experienced partial response (PR), but the second soon progressed [4]. In the publication, Kobayashi et al showed PR response in two patients treated with erlotinib, but PFS did not exceed 8 months [19]. Our case study points at a moderate response of mutation G179X + L861X to EGFR-TKIs treatment, what is in accordance with a few published cases. Together, it seems that the described complex EGFR mutation has relatively good sensitivity for EGFR-TKIs treatment.

## References

1. Hsieh MH, Fang YF, Chang WC et al. Complex mutation patterns of epidermal growth factor receptor gene associated with variable responses to gefitinib treatment in patients with non-small cell lung cancer. *Lung Cancer* 2006; 53(3): 311–322.
2. Lund-Iversen M, Kleinberg L, Fjellbirkeland L et al. Clinicopathological characteristics of 11 NSCLC patients with EGFR-exon 20 mutations. *J Thorac Oncol* 2012; 7(9): 1471–1473. doi: 10.1097/JTO.0b013e3182614a9d.
3. Fiala O, Pešek M, Finek J et al. EGFR mutations in patients with advanced NSCLC. *Klin Onkol* 2012; 25(4): 267–273. doi: 10.14735/amko2012267.
4. Wu JY, Yu CJ, Chang YC et al. Effectiveness of tyrosine kinase inhibitors on „uncommon” epidermal growth factor receptor mutations of unknown clinical significance in non-small cell lung cancer. *Clin Cancer Res* 2011; 17(11): 3812–3821. doi: 10.1158/1078-0432.CCR-10-3408.
5. Svoboda M, Fabian P, Slaby O et al. EGFR tyrosine kinase inhibitors as a targeted therapy for bronchioloalveolar carcinoma of the lung: a case report of a clinically prompt and intensive response and literature review. *Klin Onkol* 2010; 23(4): 224–230.

6. Tam IY, Leung EL, Tin VP et al. Double EGFR mutants containing rare EGFR mutant types show reduced in vitro response to gefitinib compared with common activating missense mutations. *Mol Cancer Ther* 2009; 8(8): 2142–2151. doi: 10.1158/1535-7163.MCT-08-1219.
7. Heneberg P. Indication of EGFR kinase inhibitors should be refined. *Klin Onkol* 2011; 24(2): 87–93.
8. Keam B, Kim DW, Park JH et al. Rare and complex mutations of epidermal growth factor receptor, and efficacy of tyrosine kinase inhibitor in patients with non-small cell lung cancer. *Int J Clin Oncol* 2014; 19(4): 594–600. doi: 10.1007/s10147-013-0602-1.
9. D'Arcangelo M, D'Incecco A, Cappuzzo F. Rare mutations in non-small-cell lung cancer. *Future Oncol* 2013; 9(5): 699–711. doi: 10.2217/fon.13.16.
10. Chen X, Zhu Q, Zhu L et al. Clinical perspective of afatinib in non-small cell lung cancer. *Lung Cancer* 2013; 81(2): 155–161. doi: 10.1016/j.lungcan.2013.02.021.
11. Sharma A, Tan TH, Cheetham G et al. Rare and novel epidermal growth factor receptor mutations in non-small-cell lung cancer and lack of clinical response to gefitinib in two cases. *J Thorac Oncol* 2012; 7(5): 941–942. doi: 10.1097/JTO.0b013e31825134ac.
12. Watanabe S, Minegishi Y, Yoshizawa H et al. Effectiveness of gefitinib against non-small-cell lung cancer with the uncommon EGFR mutations G719X and L861Q. *J Thorac Oncol* 2014; 9(2): 189–194. doi: 10.1097/JTO.0000000000000048.
13. Beau-Faller M, Prim N, Ruppert AM et al. Rare EGFR exon 18 and exon 20 mutations in non-small-cell lung cancer on 10 117 patients: a rarmulticentre observational study by the French HERMETIC-IFCT network. *Ann Oncol* 2014; 25(1): 126–131. doi: 10.1093/annonc/mdt418.
14. Zhang GC, Lin JY, Wang Z et al. Epidermal growth factor receptor double activating mutations involving both exons 19 and 21 exist in Chinese non-small cell lung cancer patients. *Clin Oncol (R Coll Radiol)* 2007; 19(7): 499–506.
15. De Pas T, Toffalorio F, Manzotti M et al. Activity of epidermal growth factor receptor-tyrosine kinase inhibitors in patients with non-small cell lung cancer-harboring rare epidermal growth factor receptor mutations. *J Thorac Oncol* 2011; 6(11): 1895–1901. doi: 10.1097/JTO.0b013e318227e8c6.
16. Tam IY, Leung EL, Tin VP et al. Double EGFR mutants containing rare EGFR mutant types show reduced in vitro response to gefitinib compared with common activating missense mutations. *Mol Cancer Ther* 2009; 8(8): 2142–2151. doi: 10.1158/1535-7163.MCT-08-1219.
17. Hata A, Yoshioka H, Fujita S et al. Complex mutations in the epidermal growth factor receptor gene in non-small cell lung cancer. *J Thorac Oncol* 2010; 5(10): 1524–1528. doi: 10.1097/JTO.0b013e3181e8b3c5.
18. Doss GP, Rajith B, Chakraborty C et al. Structural signature of the G719S-T790M double mutation in the EGFR kinase domain and its response to inhibitors. *Sci Rep* 2014; 4: 5868. doi: 10.1038/srep05868.
19. Kobayashi S, Canepa HM, Bailey AS et al. Compound EGFR mutations and response to EGFR tyrosine kinase inhibitors. *J Thorac Oncol* 2013; 8(1): 45–51. doi: 10.1097/JTO.0b013e3182781e35.
20. Yokoyama T, Kondo M, Goto Y et al. EGFR point mutation in non-small cell lung cancer is occasionally accompanied by a second mutation or amplification. *Cancer Sci* 2006; 97(8): 753–759.
21. Huang SF, Liu HP, Li LH et al. High frequency of epidermal growth factor receptor mutations with complex patterns in non-small cell lung cancers related to gefitinib responsiveness in Taiwan. *Clin Cancer Res* 2004; 10(24): 8195–8203.

Redakce časopisu *Klinická onkologie* a nakladatelství *Ambit Media, a.s.* vypisuje

## SOUTĚŽ NA PODPORU AUTORSKÝCH TÝMŮ PUBLIKUJÍCÍCH V ZAHRAŇIČNÍCH ODBORNÝCH TITULECH

Odměna pro vítěze: 10 000 Kč

### Cíl soutěže:

Podpořit renomé a prestiž časopisu *Klinická onkologie* – oficiálního časopisu ČOS ČLS JEP – u domácích i zahraničních autorů, lékařů a akademických pracovníků.

### Podmínky soutěže:

- Soutěž je určena autorským týmům, které publikují v zahraničních odborných titulech.
- Do soutěže budou zařazeny práce publikované v zahraničních titulech od června 2014 do června 2015.
- Ve svých článcích zaslanych k publikaci do zahraničního periodika budou autoři citovat práci, která byla otištěna v časopise *Klinická onkologie* (k vyhledání lze použít databáze [www.pubmed.org](http://www.pubmed.org) nebo [www.linkos.cz](http://www.linkos.cz)).
- Do soutěže nebudou zařazeny autocitace.
- Ze všech prací, které splní podmínky soutěže, bude redakční radou vylosována jedna, jejíž autorský tým bude oceněn částkou 10 000 Kč.

**KLINICKÁ  
ONKOLOGIE**

  
ambit media®