

Squamous Cell Carcinoma Arising in Long Lasting Leg Ulceration

Reich A., Cisło M., Szepletowski J. C.

Department of Dermatology, Venereology and Allergology, Wrocław Medical University, Poland

Souhrn

Spinocelulární karcinom vzniklý v terénu chronického bércevého vředu

Práce popisuje případ 69letého pacienta s maligní transformací chronického bércevého vředu, který byl následkem pracovního úrazu v 17 letech. Přibližně po 50 letech došlo v místě této ulcerace ke vzniku spinocelulárního karcinomu. Tento případ prezentujeme s cílem připomenout klinikům možnost maligní transformace jakékoliv chronické rány. Protože časná diagnóza dává nejlepší šanci na vyléčení, doporučujeme provést biopsii u každého pacienta s klinicky atypickou chronickou ránou.

Klíčová slova: chronická rána – maligní transformace – Marjolinův vřed – spinocelulární karcinom

Summary

Squamous Cell Carcinoma Arising in Long Lasting Leg Ulceration

A 69-year-old man with a malignant transformation within the long lasting ulceration of the lower leg is presented. The chronic ulceration was a result of an accident at work in the age of 17 years. About 50 years later the patient developed squamous cell carcinoma within the chronic ulcer.

The patient is demonstrated in order to alert the clinicians about the possibility of malignant transformation in any long-lasting wound. As early recognition offers the best chance to cure, we do postulate to perform a biopsy in every patient with long-lasting and clinically atypical ulceration.

Key words: chronic wound – malignant transformation – Marjolin's ulcer – squamous cell carcinoma

INTRODUCTION

Chronic ulcers are very common condition in dermatological practice. However, during the treatment of patients with chronic ulcers it must be remembered, that every chronic wound could be considered also as a pre-malignant lesion (11). Malignant tumours arising in chronic wounds are named "Marjolin's ulcers", as Marjolin was the first, who already in 1827 documented such a cancer development (3, 7, 11). The most common type of Marjolin's ulcers is squamous cell carcinoma (SCC), although basal cell carcinomas, adenocarcinomas, melanomas, lymphomas, sarcomas and plasmocytomas were also documented (7, 8, 11). The hypothesis that chronic ulceration is a precancerous state was also confirmed in animal studies (6). Here, we documented a patient with a very long duration of posttraumatic ulceration, who developed SCC nearly 50 years after trauma.

CASE REPORT

A 69-year-old man was admitted to our department due to chronic ulceration of the left lower leg. In the age of 17 years the patient had severe accident at work which resulted in crush of the left foot and multiple fractures of both lower legs and left upper extremity. The healing process of injuries lasted several months and was complicated by the development of an ulceration with a diameter of about 5 cm on the dorsum of the left foot, in the place of the tractor fixation. During the period of nearly 50 years the ulceration was treated with many topical agents but never completely healed. About 3 years before current admission the patient noted that the ulceration started to enlarge slowly and in the center of the lesion proliferation of granulation was observed. Three years later the patient was admitted for consultation to our department. In the last 10 years the patient lost about

10 kg of his weight. In the past the patient underwent appendectomy due to acute appendicitis and cholecystectomy because of cholelithiasis. No other significant disorders including also any medical condition, which might be responsible for poor wound healing or could promote the development of malignancy were stated in the anamnesis of the patient or in his family members. The patient also never smoked.

On admission a huge ulceration on the left lower leg and foot was noted (Fig. 1). The edge of the ulceration was slightly elevated and in the central area of the lesion proliferation of the tissue was seen (Fig. 1). The surrounding skin showed slight erythema and maceration of epidermis. The peripheral lymph nodes were not enlarged. Additionally, a small nodule (about 0,5 cm in diameter) with a dilatated vessels on the surface was stated on the right lower lid.

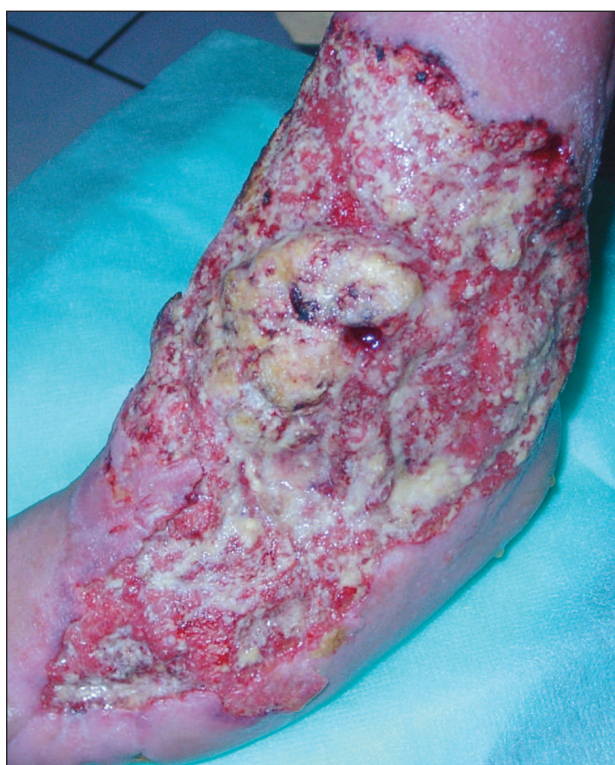

Fig. 1. A large ulceration on the left lower leg and foot with a slightly elevated edge and the malignant proliferation in the central area of the lesion.

The routine laboratory examination revealed only slight elevation of CRP serum level (23.9 mg%; normal <7 mg%) and slight acceleration of erythrocyte sedimentation reaction (26 mm/1h). Other parameters (erythrocyte and blood platelet count, blood smear, urine examination, serum level of glucose, total proteins, albumins, and electrolytes, as well as biochemical markers of liver and kidney function) were within the normal range or negative. X-ray examination of the thorax showed no significant

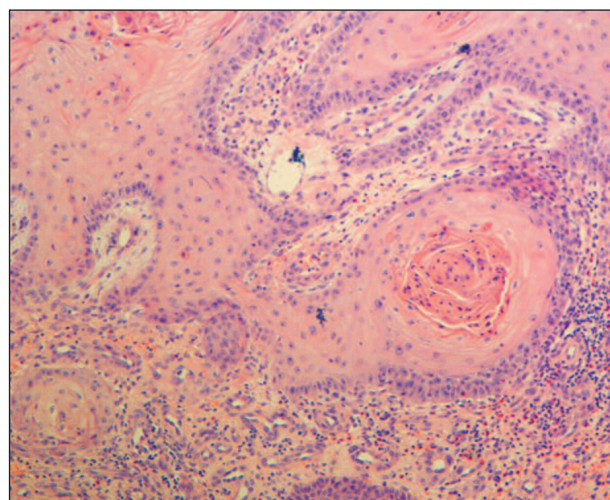
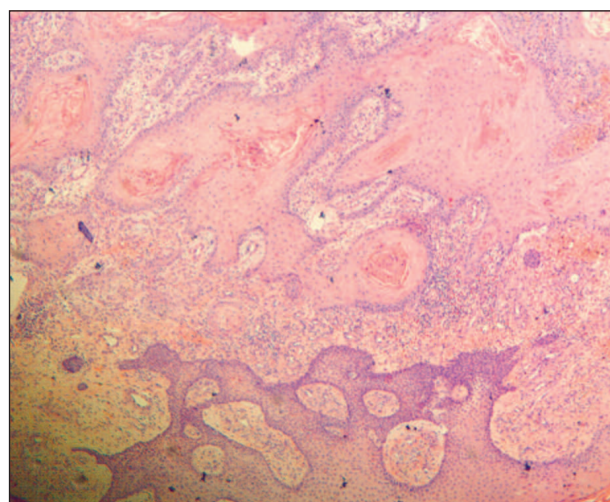


Fig. 2a. Histology of the leg ulcer demonstrating characteristic features of squamous cell carcinoma (H&E, original magnification x 40).

Fig. 2b. Larger magnification of the tumour (H&E, original magnification x 200).

abnormalities. The X-ray examination of the left lower leg revealed multiple calcifications in the soft tissues surrounding the ulceration, and bone and joint changes, which were the result of the accident in the age of 17 years. However, no malignant destruction of bones was seen. Unfortunately, the patient did not give the consent to perform a detailed imaging of the left lower leg with a help of computed tomography or magnetic resonance. Because of suspicion of the malignant transformation within the ulceration biopsies were taken from the edge and from the center of the lesion. The histological examination of both tissue samples revealed well differentiated squamous cell carcinoma (carcinoma spinocellulare keratodes) (Fig. 2a and 2b). Additionally, the small tumour of the right lower lid was surgically removed, and the histological examination showed nodular basal cell carcinoma. After the diagnosis of SCC the patient was transferred to the oncological department for further treatment.

DISCUSSION

Our patient is demonstrated in order to alert the clinicians about the possibility of malignant transformation in any long-lasting wound. The mean latency time between ulcer formation and the development of malignancy is about 25–50 years (1, 3, 10, 11), but there is also a report of malignant degeneration of a chronic wound as early as 5 months after the formation of wound (4). The development of SCC has been reported in chronic wounds secondary to burns, trauma, chronic pressure, snake bites, radiotherapy, diabetes, venous insufficiency and even hidradenitis suppurativa (2, 5, 9–11). In a study on 10,913 patients with chronic venous leg ulcers by Baldursson et al. (1) the relative risk of SCC development was 5.8 (95% confidence interval = 3.08–9.29), although the absolute risk seems to be quite small. However, SCC resulting from Marjolin's ulcers have much greater tendency to metastasize than SCC arising from other precancerous lesions (7). In a small study of 6 patients with a Marjolin's ulcer, 4 subjects demonstrated lymph nodes metastases and all of them, despite oncologic treatment, died due to systemic disease (3).

As early recognition offers the best chance to cure, we suggest to perform a biopsy in every patient with long-lasting and atypical ulceration. It is worth to mention, that presented by our group patient, despite a long-lasting ulcer, was not biopsied for over 50 years. Many carcinomas in chronic wounds do not show typical features of malignancy (8). Features such as translucent or shiny granulation tissue affecting the margin of the ulcer should alert the clinician (8). Additionally, Schwartze et al. (8) postulated to take a biopsy from every ulcer, which fails to respond to treatment within 3 months and which fails to show re-epithelialization.

REFERENCES

- BALDURSSON, B., SIGURGEIRSSON, B., LINDELOF, B. Venous leg ulcers and squamous cell carcinoma: A large-scale epidemiological study. *Br J Dermatol*, 1995, 133(4), p. 571–574.
- CHRAIBI, H., DEREURE, O., TEOT, L., GUILLOT, B. The diagnosis and treatment of carcinomas occurring at the sites of chronic pressure ulcers. *J Wound Care*, 2004, 13(10), p. 447–448.
- ESTHER, RJ., LAMPS, L., SCHWARTZ, HS. Marjolin ulcers: secondary carcinomas in chronic wounds. *J South Orthop Assoc*, 1999, 8(3), p. 181–187.
- KOZŁOWSKI, P. Surprisingly quick development of squamous cell carcinoma in chronic skin ulcer. *Chir Narzadow Ruchu Ortop Pol*, 2004, 69(1), p. 45–48.
- LEE, MY., SHIN, JC., PARK, CI., RHA, DW., SASTRY, TK. Verrucous carcinoma of the foot from chronic pressure ulcer. *Spinal Cord*, 2004, 42(7), p. 431–434.
- PEREZ, MA., RAIMONDI, AR., ITOIZ, ME. An experimental model to demonstrate the carcinogenic action of oral chronic traumatic ulcer. *J Oral Pathol Med*, 2005, 34(1), p. 17–22.
- RATLIFF, CR. Two case studies of Marjolin's ulcers in patients referred for management chronic pressure ulcers. *J Wound Ostomy Continence Nurs*, 2002, 29(5), p. 266–268.
- SCHWARTZE, HP., LOCHE, F., GORGUET, MC., KUČHTA, J., BAZEX, J. Basal cell carcinoma associated with chronic venous leg ulcer. *Int J Dermatol*, 2000, 39(1), 78–79.
- SHORT, KA., KALU, G., MORTIMER, PS., HIGGINS, EM. Vulval squamous cell carcinoma arising in chronic hidradenitis suppurative. *Clin Exp Dermatol*, 2005, 30(5), p. 481–483.
- SMITH, J., MELLO, LF., NOGUEIRA NETO, NC., MEOHAS, W., PINTO, LW., CAMPOS, VA., BARCELLOS, MG., FIOD, NJ., REZENDE, JF., CABRAL, CE. Malignancy in chronic ulcers and scars of the leg (Marjolin's ulcer): a study of 21 patients. *Skeletal Radiol*, 2001, 30(6), p. 331–337.
- TRENT, JT., KISNER RS. Wounds and malignancy. *Adv Skin Wound Care*, 2003, 16(1), p. 31–34.

Došlo do redakce: 2. 1. 2006

Address for correspondence:

Prof. Jacek C Szepietowski, MD, PhD
 Department of Dermatology, Venereology
 and Allergology
 University of Medicine
 Ul. Chalubinskiego 1
 50-368 Wrocław, Poland
 E-mail: jszepiet@derm.am.wroc.pl