

SEVERE NEAR REFLEX SPASM IN A HEALTHY TEENAGER. A CASE REPORT

Mejía G.^{1,2}, Guevara S.², Salgado Y.², Tello A.^{3,4,5}

¹Neuroscience Research Group (NEUROS). Neurovitae Research Center. School of Medicine and Health Sciences. Rosario University, Bogotá, Colombia

²Ophthalmology Interest Group Universidad del Rosario. (OIG UR). School of Medicine and Health Sciences. Rosario University, Bogotá, Colombia

³Virgilio Galvis Eye Center, Floridablanca, Colombia

⁴Ophthalmology Foundation of Santander - Carlos Ardila Lulle (FOSCAL), Floridablanca, Colombia

⁵Ophthalmology Foundation of Santander, Industrial University of Santander (UIS), Bucaramanga, Colombia

The authors of the study declare that no conflict of interest exists in the compilation, theme and subsequent publication of this professional communication, and that it is not supported by any pharmaceutical company.

Received: November 22, 2022

Accepted: December 19, 2022



Germán Alberto Mejía Salgado
School of Medicine and Health Sciences. Rosario University
Carrera 24 # 63 C 69
Bogotá
Colombia
E-mail:
germanmejiainvest@gmail.com

SUMMARY

Introduction: Spasm of the near reflex usually includes accommodative spasm, esophoria/tropia, and different degrees of miosis. Patients usually refer to distance blurred and fluctuating vision, ocular discomfort, and headaches. The diagnosis is established with refraction with and without cycloplegia; most of the cases have a functional etiology. However, some cases require neurological conditions to be ruled out; cycloplegics have an important diagnostic and therapeutic role.

Purpose: To describe a case of bilateral severe accommodative spasm in a healthy 14-year-old teenager.

Case presentation: A 14-year-old boy with progressive diminished visual acuity attended for YSP consultation. The diagnosis of bilateral spasm of the near reflex was made, based on a gap refraction of 9.75 D between retinoscopy with and without cycloplegia and esophoria with normal keratometry and axial length. The spasm was eliminated with 2 drops of cycloplegic in each eye separated by 15 days; no clear etiology was found other than the start of school.

Conclusion: Clinicians should be aware of pseudomyopia, especially in children with acute changes in visual acuity, who are usually exposed to myopigenic environmental factors that induce overstimulation of the parasympathetic third cranial nerve's innervation.

Key words: ophthalmology, pseudomyopia, spasm of near reflex, accommodation spasm, esotropia, atropinization, cycloplegia

Čes. a slov. Oftal., 79, 2023, No. 2, p. 97–100

BACKGROUND

Due to shared parasympathetic innervation of the third cranial nerve between the ciliary muscle, the iris sphincter, and the medial rectus, spasm of the near reflex encompasses a spectrum of anomalies in varying degrees, including accommodative spasm [AS], convergence spasm [with variable esophoria/tropia], and miosis during a spasm. These three components can manifest simultaneously, or be isolated. AS results from an involuntary and prolonged contraction of the ciliary muscle, leading to a myopic shift [pseudomyopia]. It can be uni-

lateral or bilateral [1,2]. Its etiology is variable. Although most cases are associated with psychogenic or functional causes, they can rarely be explained by underlying organic conditions, mainly sequelae of head trauma; therefore, it is critical to perform an appropriate diagnostic workup in selected cases [1,3-6]. In the last decades, it seems that the prevalence of AS has increased in children; this may be attributed to higher exposure to myopigenic environmental factors at these ages, such as an intensification in near-vision activities, a higher educational level, and less outdoor time [6-8]. We present a case of severe bilateral AS accompanied with esophoria in a teenage boy.

CASE DESCRIPTION

A 14-year-old boy with progressive diminished visual acuity [VA] in the previous year was brought by his parents for a second opinion, because he had changed his eyeglasses seven months before, with no improvement in visual acuity, which had worsened in the last month. The parents denied any additional personal or familial history of eye disease, and the teenager was not using any topical or systemic medication. The patient's mother mentioned that the child had started to complain a few weeks after he began school.

In the primary position, no deviations were detected, but esophoria was found in both eyes; in scotopic-light conditions, the pupils were isochoric with a 3mm width and reactivity of 4+. Uncorrected distance visual acuity [UDVA] without cycloplegia was finger counting at 1 meter in both eyes, which improved only to 20/200 in both eyes with his glasses [-4.25 Diopters[D] for the right eye [RE], and -3.50 D for the left eye [LE]]. Manual

keratometry showed 44.00 / 45.00 D for RE and 44.00 / 45.50 D for the LE. Objective refraction according to static retinoscopy without cycloplegia was -9.50 -0.50 x180° in RE and -9.50 -0.75x20° in LE. Manifest refraction without cycloplegia was -8.25-1.00 x180° in RE and -8.00 -0.75x20° in LE, with corrected distance visual acuity [CDVA] of 20/30 and 20/25. 30 minutes after applying 2 drops of 1% atropine, UDVA improved to 20/50 in both eyes. Refraction was +0.50-1.00 x0° in RE and +0.50 -0.25 x10° in LE. The diagnosis of bilateral spasm of the near reflex manifesting as accommodative spasm and esophoria was made.

Two weeks later, UDVA was 20/30 in both eyes, and manifest refraction was -050 -1.25 x0° for RE and -0.50D -1.00D x13° for LE, with CDVA 20/25 in both eyes. 1% atropine eyedrops were applied to each eye. Axial length according to optical biometry [IOL Master 500®, Zeiss] was 22.99 and 22.88 mm for RE and LE, respectively [Figure 1]. Lens thickness determined with A-scan ultrasound was 3.75 mm for both eyes.

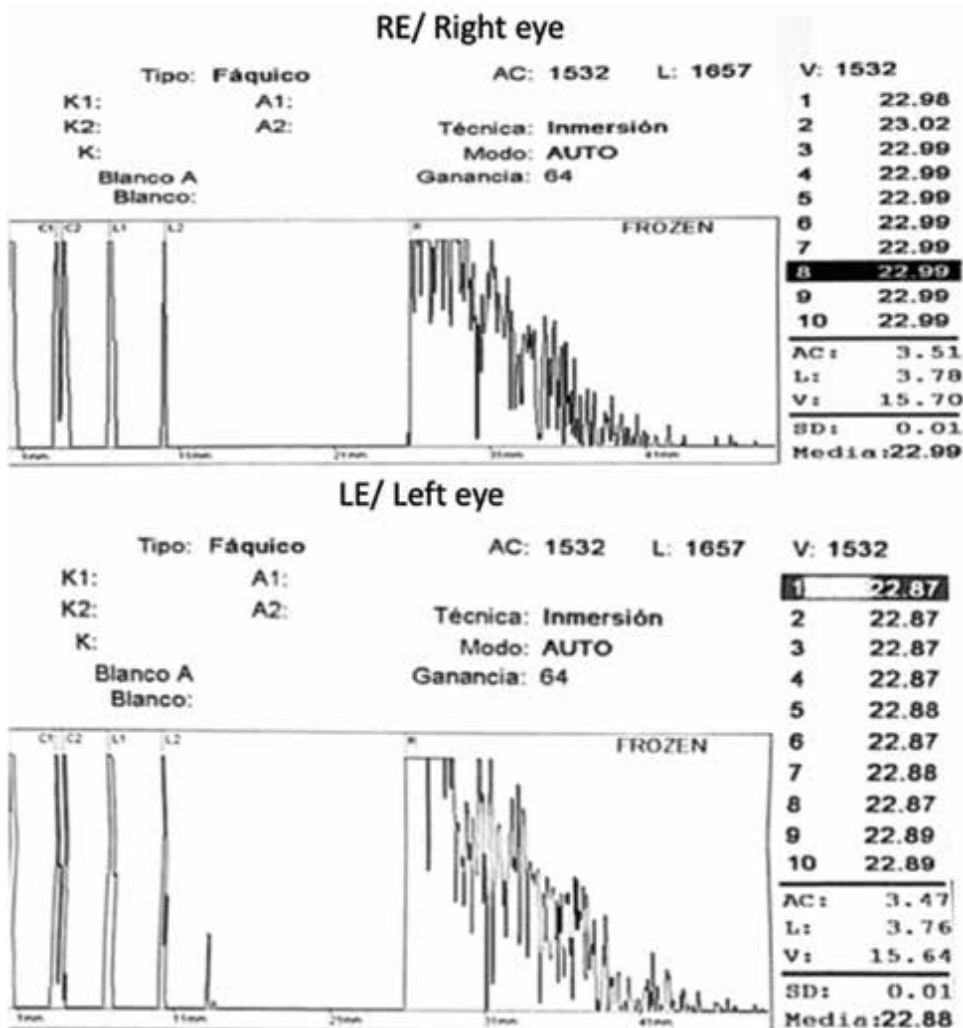


Figure 1. Normal axial length measured by IOL Master 500®, Zeiss. 22.99 mm and 22.88 mm for the right eye and left eye, respectively

In subsequent evaluations, the patient remained asymptomatic, with stable refractions. In the last visit [two months after the first examination], UDVA was 20/30 in both eyes, which corrected to 20/20 with a refraction of $-0.50 -1.25 \times 0^\circ$ in RE and $-0.50 -1.00 \times 13^\circ$ in LE. Uncorrected near visual acuity [UNVA] was 0.75 M in both eyes. The patient felt comfortable about his vision without glasses, so no optical prescription was given.

DISCUSSION

Spasm of the near reflex usually includes AS, also known as ciliary spasm. It was described by Donders more than 150 years ago [9,10]. AS can occur isolated or can be associated with esophoria/tropia and different degrees of miosis [1,5,11]. Patients usually refer to fluctuant diminished distant vision and headaches. This symptomatology is not constant and affects both eyes in most cases. However, unilateral presentation is also reported in the literature [12]. Symptoms and signs are explained by an inability to relax the contraction of the ciliary muscle, so the individual is unable to focus on distant objects [13]. Recently, Kang et al. reported that accommodative spasm [pseudomyopia], defined as a spherical equivalent refractive of -0.50 D or more negative before cycloplegia and less negative than -0.50 D after cycloplegia, in children aged under 6 years had a prevalence of 24%, and 18% in 13-year-old children [5,8].

Pathophysiology of AS is associated with overstimulation of the parasympathetic nervous system through pre-ganglionic fibers that come from the Edinger-Westphal nucleus and innervate the ciliary muscle, iris sphincter, and medial rectus [1,5,13]. The fact that certain neurological conditions, apart from head trauma, are the cause of some cases of spasms of the near reflex is a matter of discussion, since it has been difficult to establish the causal relationship [1,14]. On the other hand, since the symptoms of spasm of the near reflex overlap with those that characterize other serious neurological conditions [such as diplopia, esotropia, and blurred vision], patients with spasm of the near reflex, before having a clear diagnosis of their ophthalmological condition, may be subjected to various diagnostic studies by neurologists [most of them minimally invasive, such as neuroimaging, but some of them more invasive, such as lumbar punctures] to investigate possible unilateral or bilateral paralysis of the sixth nerve or optic neuritis [6].

Papageorgiou et al. recently suggested that the diagnosis of spasm of the near reflex is clinical and can be made quickly, based on ophthalmological findings in most cases. Patients with spasm of the isolated near reflex present visual symptoms [blurred and fluctuating vision secondary to variable myopization] and discomfort caused by the spasm of the ciliary muscle itself [as-

thenopia, ocular discomfort, lack of concentration, and headaches]. The ophthalmological examination, including refraction with and without cycloplegia, will establish the diagnosis, as more negative refraction is found in the non-cycloplegic retinoscopy compared to the cycloplegic evaluation [with a difference greater than 0.75 D and up to 10 D] [6]. It has been associated with excessive use of electronic devices, chronic stress, anxiety disorders, and other mental illnesses [3,6,15-17]. In this case, symptoms may be related to starting school, which involves higher levels of stress and increased use of near vision.

In the patient reported herein, the amount of pseudomyopia was one of the highest ever reported [around -9.75 D in each eye]. Cycloplegic refraction is, in fact, the gold standard technique to diagnose AS; this should be performed in all patients. However, it may be especially important in patients with fluctuations in retinoscopy findings and non-cycloplegic refractions, pupil reflexes, and variable distance visual acuity. We determined axial length to rule out the possibility of axial myopia.

Definitive treatment of AS may be problematic, as most cases have a functional etiology. The goal of treatment is to relax accommodation and eliminate pseudomyopia. If any specific etiology is found, treatment for the primary condition should resolve the AS. The literature suggests starting from less to more invasive treatment. Cycloplegic agents [cyclopentolate 1% or atropine 1%] are the most commonly used topical medications, which can be accompanied by near-addition lenses for near-vision activities during treatment. Nevertheless, a defined regime has not been established in clinical practice. Roy et al. recently proposed a consolidated management protocol for patients with spasms of near reflex, based on cycloplegics and optical interventions [18].

Although our patient had a severe bilateral spasm, it was resolved after only 2 applications of topical 1% atropine in both eyes, separated by 2 weeks, and the refraction reached a very low myopic error, so the teenage boy preferred not to wear glasses. It is essential to advise outdoor activities and a reduction of near-work activities, as well as reducing stressful situations that are related to the spasm, to avoid recurrent AS.

Ethics approval

This study adheres to the ethical principles for human research established by the Helsinki Declaration, the Belmont Report, and Colombian Resolution 008430 of 1993.

Acknowledgments

We would like to thank the patient for granting permission to publish this information. We would also like to thank Centro Oftalmológico Virgilio Galvis for financing the APC of this manuscript.

REFERENCES

1. Goldstein JH, Schneekloth BB. Spasm of the near reflex: A spectrum of anomalies. *Surv Ophthalmol*. 1996;40(4):269-278.
2. García-Montero M, Felipe-Márquez G, Arriola-Villalobos P, Garzón N. Pseudomyopia: A Review. *Vision*. 2022;6(1):17.
3. London R, Wick B, Kirschen D. Post-traumatic pseudomyopia. *Optom St Louis Mo*. 2003;74(2):111-220.
4. Kowal L. Ophthalmic manifestations of head injury. *Aust N Z J Ophthalmol*. 1992;20(1):35-40.
5. Hyndman J. Spasm of the Near Reflex: Literature Review and Proposed Management Strategy. *J Binocul Vis Ocul Motil*. 2018;68(3):78-86.
6. Papageorgiou E, Kardaras D, Kapsalaki E, Dardiotis E, Mataftsi A, Tsironi EE. Spasm of the near reflex: a common diagnostic dilemma? *Int J Ophthalmol*. 2021;14(4):541-546.
7. Galvis V, Tello A, Camacho PA, Parra MM, Merayo-Llodes J. Los factores bioambientales asociados a la miopía: una revisión actualizada. *Arch Soc Esp Oftalmol*. 2017;92(7):307-325.
8. Kang MT, Jan C, Li S, et al. Prevalence and risk factors of pseudomyopia in a Chinese children population: the Anyang Childhood Eye Study. *Br J Ophthalmol*. 2021;105(9):1216-1221.
9. Donders FC, Moore W. On the anomalies on accommodation and refraction of the eye: with a preliminary essay on physiological dioptrics [Internet]. London; 1864. Available from: https://dwc.knaw.nl/pub/bronnen/F.C._Donders-On_the_anomalies_of_accommodation_and_refraction_of_the_eye.pdf
10. Galvis V, Tello A, Parra MM. Topical Atropine in the Control of Myopia. *Med Hypothesis Discov Innov Ophthalmol J*. 2016;5(3):78-88.
11. Rhatigan M, Byrne C, Logan P. Spasm of the near reflex: A case report. *Am J Ophthalmol Case Rep*. junio de 2017;6:35-37.
12. Peinado GA, Merino Sanz P, del Cerro Pérez I, Gómez de Liaño Sánchez P. Espasmo de acomodación unilateral: descripción de un caso y revisión de la literatura. *Arch Soc Esp Oftalmol*. 2019;94(6):285-287.
13. Hughes FE, Treacy MP, Duignan ES, Mullaney PB. Persistent pseudomyopia following a whiplash injury in a previously emmetropic woman. *Am J Ophthalmol Case Rep*. 2017;8:28-30.
14. Dagi LR, Chrousos GA, Cogan DC. Spasm of the Near Reflex Associated with Organic Disease. *Am J Ophthalmol*. 1987;103(4):582-585.
15. Kara H, Yasar E, Gurlevik U. Is pseudomyopia associated with anxiety and related disorders? *Pak J Med Sci [Internet]*. 2021; 37[5]. Available from: <http://pjms.org.pk/index.php/pjms/article/view/3991>
16. Khalid K, Padda J, Pokhriyal S, et al. Pseudomyopia and Its Association With Anxiety. *Cureus [Internet]*. 202; Available from: <https://www.cureus.com/articles/68472-pseudomyopia-and-its-association-with-anxiety>
17. McMurray CJ, Burley CD, Elder MJ. Clear lens extraction for the treatment of persistent accommodative spasm after head trauma. *J Cataract Refract Surg*. 2004 Dec;30(12):2629-2631.
18. Roy S, Bharadwaj SR, Patil-Chhablani P, Satgunam PN. Spasm of near reflex: a comprehensive management protocol and treatment outcomes. *J Am Assoc Pediatr Ophthalmol Strabismus*. 2021 Jun;25(3):162.e1-162.e6.