

# CORNEAL NEUROTISATION IN PATIENT WITH SEVERE NEUROTROPHIC KERATOPATHY. CASE REPORT

Rusňák Š.<sup>1</sup>, Hecová L.<sup>1</sup>, Štěpánek D.<sup>2</sup>, Sobotová M.<sup>1</sup>

<sup>1</sup>Department of Ophthalmology, University Hospital, Plzeň, Czech Republic

<sup>2</sup>Department of Neurosurgery, University Hospital, Plzeň, Czech Republic

*The authors of the study declare that no conflict of interests exists in the compilation, theme and subsequent publication of this professional communication, and that it is not supported by any pharmaceuticals company. The study has not been submitted to or printed in any other journal.*

Received: 24 August 2020

Accepted: 2 February 2021

Available on-line: 15 June 2021



MUDr. Štěpán Rusňák, Ph.D.

Oční klinika

Fakultní nemocnice v Plzni

alej Svobody 80

30460 Plzeň

E-mail: rusnak@fnplzen.cz

## SUMMARY

**Purpose:** Neurotrophic keratopathy (NK) is a degenerative corneal disease caused by damage to the trigeminal innervation due to a decrease in corneal sensitivity or complete anaesthesia. Impaired corneal innervation leads to morphological and metabolic disorders of the epithelium. In addition, it also leads to the development of recurrent or persistent epithelial defects in corneal ulcers, which may progress to stromal lysis and corneal perforation. One possible solution for severe NK is reinnervation of the anaesthetic cornea (corneal neurotization) using the supraorbital nerve and an autologous sensory nerve graft (indirect neurotization).

This article presents the results of corneal neurotization in a young male patient with persistent epithelial defects and corneal ulcers due to corneal denervation.

**Results:** A 22-year-old man with a history of neurosurgery for astrocytoma of the cerebellum and trunk on the right side at the age of 2 years, was observed for postoperative paresis of the right facial nerve with lagophthalmos in his childhood. The presence of asymptomatic dysfunction of the right trigeminal nerve was also noted. At the age of 22 years, after right eyeball contusion, the vision of the right eye decreased and a persistent epithelial defect developed, followed by corneal ulceration. Due to the exhaustion of therapeutic options in a young patient with corneal anaesthesia, the cornea was reinnervated via the contralateral supraorbital nerve using an autologous sural nerve graft. Five months after the surgery, the sensitivity of the cornea of the right eye began to recover. After amniotic membrane transplantation, the extensive epithelial defect healed, and the opaque corneal stroma gradually cleared up.

**Conclusion:** The reinnervation of the anaesthetic cornea (corneal neurotization) using the supraorbital nerve and the autologous sensory nerve graft represents a new solution for severe NK treatment. The severe corneal condition in our patient healed after the surgery.

**Key words:** neurotrophic keratopathy, corneal anaesthesia/hypoesthesia, corneal neurotization, n. trigeminus, n. suralis

Čes. a slov. Oftal., 77, 2021, No.3, p. 146–152

## INTRODUCTION

The cornea is innervated by the first branch of the trigeminal nerve (ophthalmic nerve) and the autonomous nerves. Neurotrophic keratopathy (NK) is a rare degenerative disease of the cornea, with a prevalence of around 5 per 10 000 persons [1]. NK is caused by trauma or damage to the trigeminal nerve (n. trigeminus) or its first branch (n. ophthalmicus). The most common cause of NK is herpetic keratitis (27%), followed by systemic pathologies (e.g. diabetes mellitus, multiple sclerosis and vitamin A deficiency), chemical and thermal injuries to the ocular surface, long-term use of contact lenses, excessive use of local anaesthetics, central damage to the trigeminal nerve (acoustic neurinoma, neurological procedures etc.) or damage to the ciliary nerves in operations on the anterior and

posterior segment of the eye (anti-glaucoma procedures, refractive surgery etc.) [2]. Table 1.

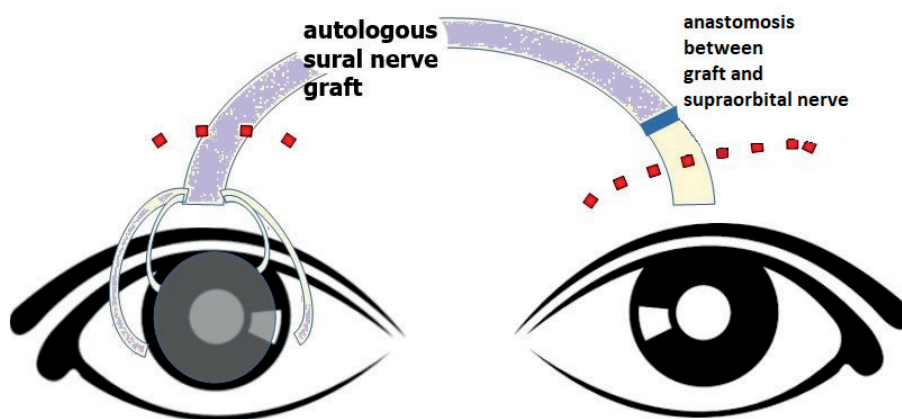
The nerve bundles enter the cornea in the region of the limbus, in the periphery of the cornea they are situated beneath the anterior third of the corneal stroma, they then penetrate through the Bowman's membrane and between it, and through the layer of the basal epithelial cells, where they form a dense network of nerve fibres, referred to as the subbasal nerve plexus [3]. Sensitive innervation of the cornea reacts to mechanical, chemical and thermal stimuli by two reflex arches: motoric stimulating blinking and autonomous stimulating tear secretion. Innervation plays a key role in maintaining a healthy ocular surface – in part by triggering protective reflexes upon trauma, and in part by providing trophic factors for the corneal cells. Reduction of corneal sensitivity indicates changes in the lacrimal film, influences the metabolism and

proliferation of the epithelial cells, and leads to their increased apoptosis. This results in the onset of intracellular edema, loss of microvilli, and abnormalities in the region of the basal lamina [4].

Anaesthesia or hypoesthesia present in NK can therefore lead to recurring or persistent defects of the corneal epithelium, ulcers, corneal opacity or perforation. Treatment of NK depends on the severity of the pathology. Ordinary local therapy consists primarily in the substitution of the lacrimal film – artificial tears without preservative agents, ocular lubrication gels, eye drops from autologous/allogeneic serum, eye drops from serum from umbilical blood. Other tested treatment methods include local application of NGF (nerve growth factor) and

other agents (ReGeneraTing Agents, i.e. RGTA, thymosin beta-4, substance P, nicergolin or citicoline) [4-7]. In the last decade, there has been increased use of the method of neurotisation, i.e. re-innervation of the cornea. Neurotisation, or nerve transfer, is a technique of using another healthy nerve or part thereof as a donor of healthy nerve fibres for the restoration of an irreversibly impaired sensory or motor pathway. Restoration of a nerve pathway may be direct, with local nerve transfer, or indirect, with the use of a nerve graft [8]. Fig. 1.

The aim of the case report is to present our experience with the use of indirect neurotisation of the cornea in a patient with severe form of NK and corneal ulceration occurring upon a background of a persisting epithelial defect.



**Fig. 1.** Diagram of indirect corneal neurotisation of affected right eye using nerve graft and contralateral supraorbital nerve.

**Table 1.** Causes of neurotrophic keratopathy

Ocular surface damage	Herpetic keratitis (HSV, HZV) Chemical or thermal injury Refractive surgery Other surgical procedures – antiglaucoma procedures (cyclocryocoagulation, cyclophotocoagulation), cataract surgery, pars plana vitrectomy, penetrating keratoplasty, DALK Panretinal laser photocoagulation Radiation Contact lens wear Medication – benzalkonium chloride, topical anaesthetics, timolol, betaxolol, diclofenac, sulphacetamide
Corneal dystrophy	Lattice corneal dystrophy Granular corneal dystrophy
Systemic pathologies	Diabetes mellitus Multiple sclerosis Vitamin A deficiency Leprosy
Genetic disorders	Moebius syndrome, familial dysautonomy (Riley-Day syndrome), Goldenhar-Gorlin syndrome
Central nervous system disorders	Acoustic neuroma Meningioma Aneurysm Stroke Degenerative CNS disorders: Alzheimer's disease, Parkinson's disease Neurosurgical procedures

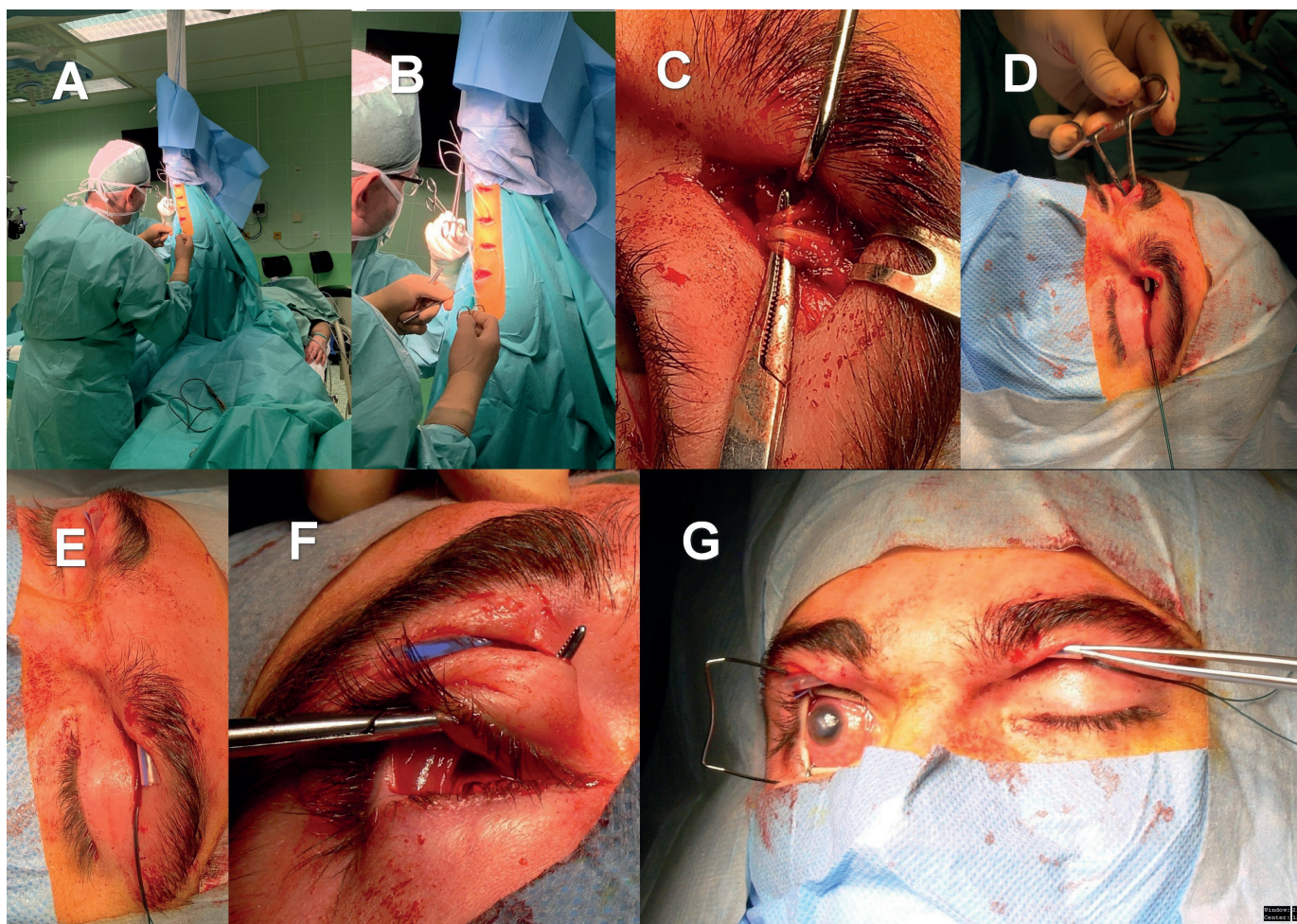
## CASE REPORT

A 22-year-old man with a medical history of neurosurgery for astrocytoma of the cerebellum and trunk on the right side at the age of two years was observed for postoperative paresis of the right facial nerve with lagophthalmos, and at the same time there was a present malfunction of the trigeminal nerve on the right side. During his adolescence he had been repeatedly treated at the district ophthalmology clinic for corneal infiltrates (in lagophthalmos and corneal hypoesthesia in the right eye), according to the available documentation opacities of the cornea in the temporal quadrant were healed. At the age of 22 years, the patient suffered from concussion and contusion of the right eyeball when punched with a fist during a physical attack. At our centre the patient was first presented and examined 3 weeks after the contusion of the right eyeball due to a persistent epithelial defect of the cornea and deterioration of vision in the right eye. The persistent epithelial defect was refractory to regular therapy (therapeutic soft contact lens, lubrication thera-

py, partial tarsorrhaphy, repeated transplantation of amniotic membrane), and corneal ulceration and opacity of the corneal stroma developed. Central visual acuity deteriorated to movement, certa. The finding corresponded to the third degree according to the Mackie classification system.

With regard to the exhaustion of therapeutic options for the young patients with corneal anaesthesia, re-innervation of the cornea was performed via the route of the contralateral supraorbital nerve, with use of an autologous sural nerve graft from the right leg. Before surgery, the patient was informed in detail of the course of the procedure and the potential complications and signed an informed consent form. Fig. 2 and 3.

The surgical procedure was performed in co-operation with a neurosurgeon specialising in surgery of the peripheral nerves. An approach was selected using anastomosis on the supraorbital nerve. The sural nerve was chosen as the source of the nerve graft. The safe and gentle extension of the nerve graft over the glabella was secured by a hollow polythene introducer. The procedure and the



**Fig. 2.** Indirect corneal neurotisation of right eye using sural nerve graft and contralateral supraorbital nerve. Preparation of sural nerve graft from right lower limb (A,B). Localisation of contralateral (i.e. left, healthy side) supraorbital nerve (C). Preparation of subcutaneous tunnel between upper lids of right and left eye (D), stretching tube for easier and safer manipulation of nerve graft (E). Preparation of tunnel from upper fornix of affected right eye to subcutaneous tissue of upper eyelid (F). Situation before application of nerve graft (G).

postoperative period were without complications. In the immediate postoperative period, repeated re-banding of the right eye was performed with antibiotic ointment (tobramycin), mydriatics (homatropine gtt. 5%) and epithelising gel. After the subsidence of chemosis of the bulbar conjunctiva the cornea was covered with a soft contact lens, the patient frequently (every hour) applied artificial tears in combination with mydriatics (homatropine gtt. 5% every 8 hours), local antibiotics (tobramycin every 8 hours) and a local corticosteroid (fluorometholone every 12 hours).

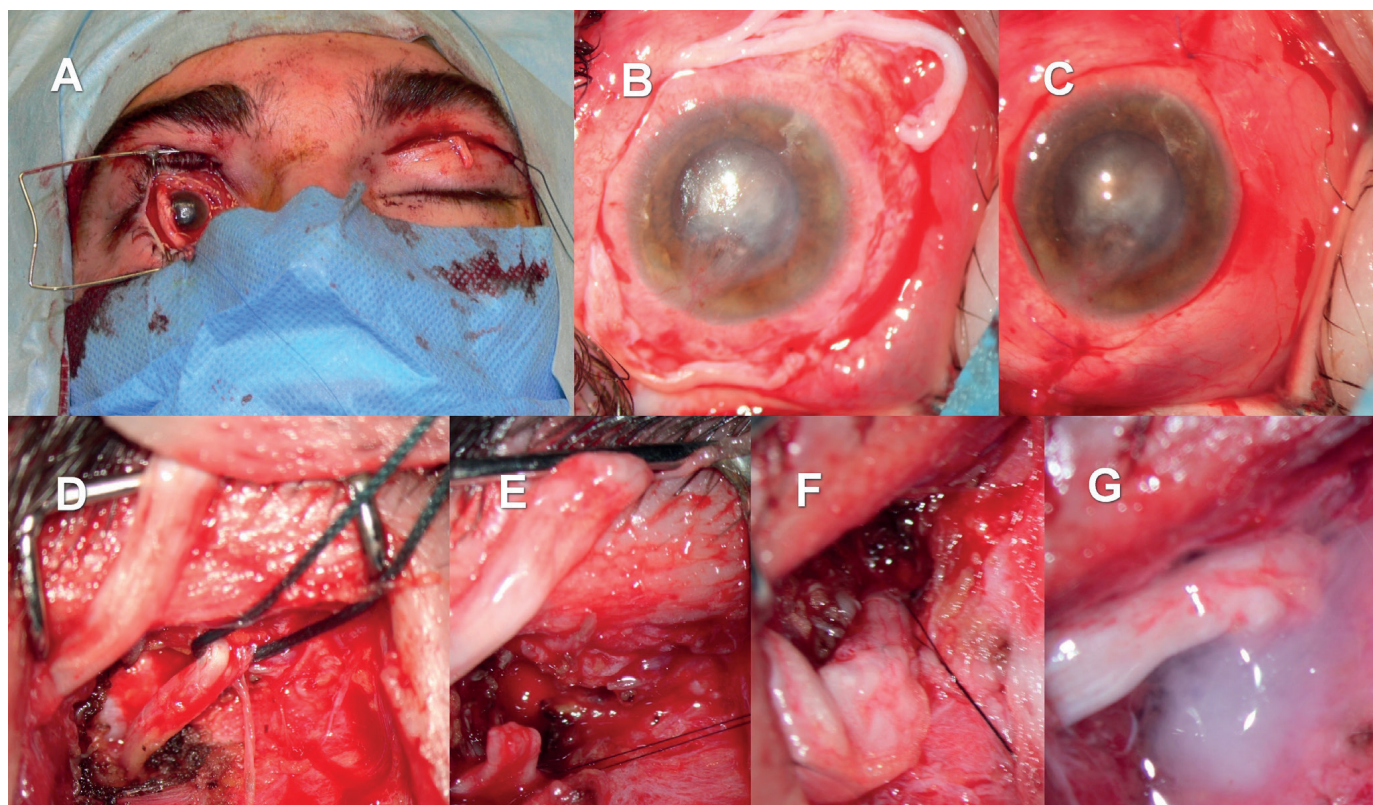
Five months after the performance of the procedure, corneal sensitivity first began to appear in the right eye, and progressively improved over the course of the following five months. At present, corneal sensitivity is fully restored (tested by cotton wool bud) in three quadrants, while one quadrant (lower nasal quadrant) has remained hypoesthetic. Despite the improving corneal sensitivity in the right eye, a non-healing ulcer persisted on the cornea, and as a result a repeat transplantation of the amniotic membrane into the defect (in two layers) was performed 6 months after indirect corneal neurotisation, with postoperative coverage with a soft contact lens. After the procedure progressive corneal epithelialisation took place, the corneal epithelium was re-healed, and

the sutures were extracted 8 weeks after the procedure. The continuing corneal epithelialisation was accompanied by the beginning of clarification of the opaque corneal stroma. A vascularised corneal macula persists 11 months after indirect corneal neurotisation, otherwise the corneal stroma is entirely transparent. Best corrected visual acuity in the right eye of 0.1 was attained 7 months after corneal neurotisation, but due to the progression of complicated intumescent cataracts there was a gradual deterioration to 1/50, certa. We plan to perform cataract surgery following the long-term stabilisation of the corneal finding. Fig. 4.

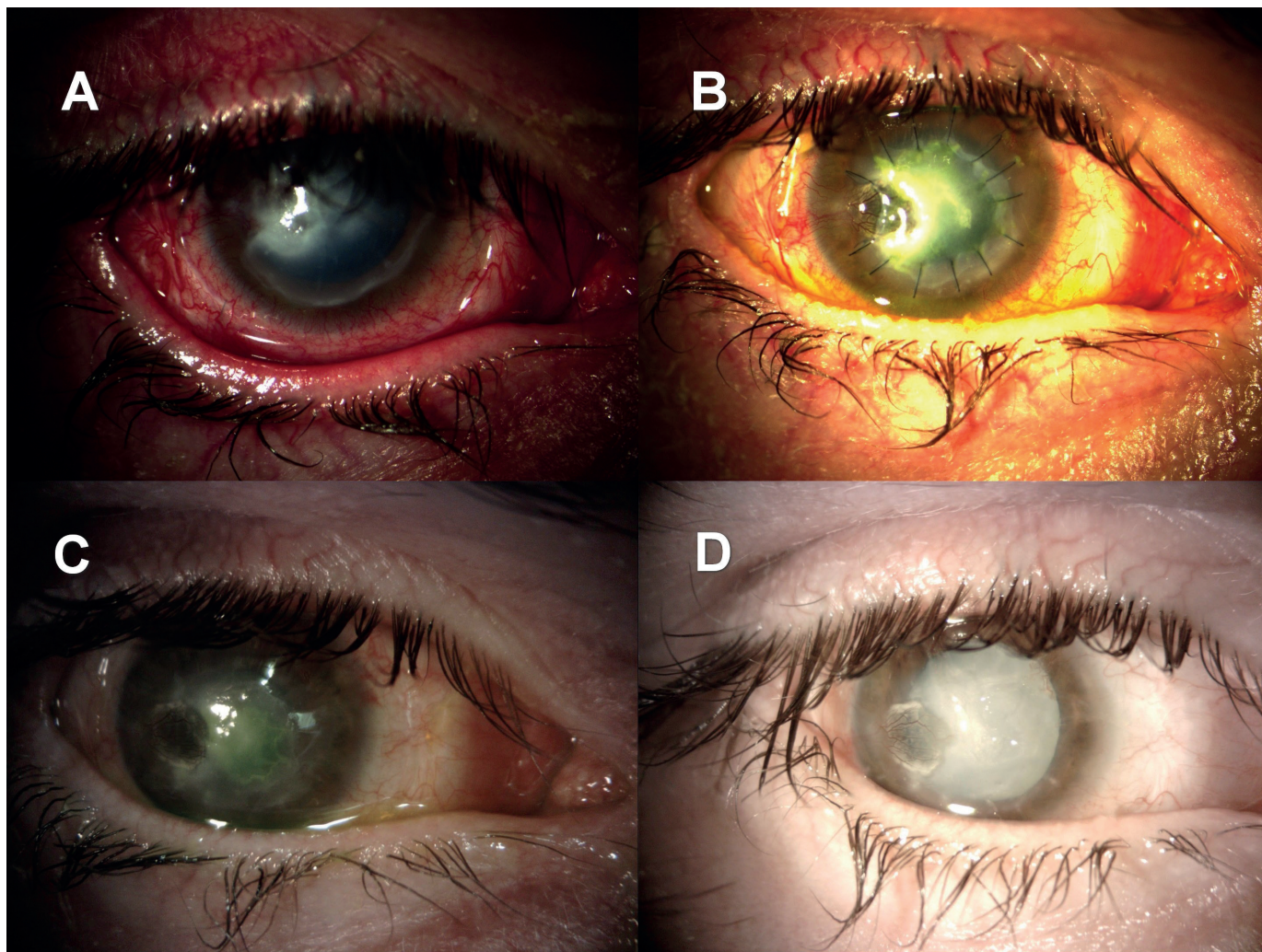Small anaesthetic areas in the scalp area on the left side (innervation area of interrupted supraorbital nerve) and on the external side of the right leg (innervation area of sural nerve used for nerve graft) persisted as a permanent consequence of indirect corneal neurotisation in the patient.

## DISCUSSION

The corneal nerves and epithelial cells mutually support one another by releasing trophic factors supporting the proliferation, migration and differentiation of epithelial cells, as well as the growth and development of the



**Fig. 3.** Indirect corneal neurotisation of right eye using sural nerve graft and contralateral supraorbital nerve. Situation after threading of sural nerve graft through prepared tunnels – visible end of graft on surface of affected right eye, graft passes through upper eyelid of right eye, then through subcutaneous tunnel to left upper eyelid (visible end of nerve graft) (A). Dissection of individual fascicles on surface of affected eye, situation before fixation of fascicles to sclera (B). Finding after suturing nerve fascicles of graft and covering them with bulbar conjunctiva (C). Ligated supraorbital nerve on healthy side, end of nerve graft is visible in upper left corner of photo (D). Dissection of supraorbital nerve (E). End-to-end coaptation of nerve graft with supraorbital nerve (F), fibrin glue application before wound closure (G).



**Fig. 4.** (A) Situation 2 weeks after surgery - visible perlimbal elevated line under bulbar conjunctiva caused by nerve fascicles of graft, further extensive ulceration of cornea. (B,C) Development 6 months (after amniotic membrane transplantation) and 8 months after surgery - gradual closure of ulceration and clearing of corneal stroma. (D) Finding 9 months after surgery (picture distorted by artificial mydriasis and intumescent cataract of right eye) - corneal ulceration is closed, nasal and central corneal parts are significantly more transparent, corneal clouding persists in temporal part of cornea.

peripheral nerves. These factors are fundamental for the maintenance of homeostasis of the ocular surface and healing of wounds. The corneal nerves exprimate several neuromediators which are important for the epithelial trophic unit, such as the substance P, CGRP (calcitonin gene-related peptide), acetylcholine, noradrenalin, serotonin, neuropeptide Y and VIP (vasointestinal peptide). By contrast, the corneal epithelial cells release various neurotrophic growth factors, including NGF, CNTF (ciliary neurotrophic factor) or GDNF (glial-cell line derived neurotrophic factor) [4-6]. These complex mutual relationships between the epithelial cells and the corneal nerves are decisive for the physiological restoration of the cornea and healing of wounds. A reduction of corneal sensitivity impairs these relationships and may trigger pathological changes typical of NK.

The classification system according to Mackie divides severity of NK into 3 degrees. In the first degree, reduced mitosis and renewal of the epithelial cells, combined with

increased permeability of the epithelium, leads to a reduction of central corneal thickness, damage to the epithelium by pressure of the eyelids and the development of corneal punctate epitheliopathy. In the second degree, non-healing corneal epithelial defects persist, with damage to the Bowman's membrane and exposure of the corneal stroma. In the third degree, the corneal stroma is affected, an imbalance develops between the activators and inhibitors of matrix metalloproteinases (MMP), with the onset of stromal lysis and the risk of corneal perforation and loss of sight or of the eye [9]. The finding in our patient was classified as third degree.

In the treatment of our patient, the options of the standard regularly available conservative and surgical therapy were progressively exhausted. Studies published in recent years have described very promising results of local therapy with the aid of NGF [4,10]. Cenegermin, sold under the brand name Oxervate™ (cenegermin-bkbj ophthalmic solution, Dompé), is a recombinant form of

human nerve growth factor (rhNGF). In July 2017 it was approved by the European Union as a preparation for eye drops used in the treatment of medium-severe to severe neurotrophic keratitis in adults, and in August 2018 it was approved in the USA. The eye drops contain 0.002% (0.02 mg/ml) of the active substance. Oxervate<sup>TM</sup> is applied six times per day at two-hourly intervals, over a period of eight weeks. The disadvantage consists partly in storage (it is necessary to store the drops at a temperature of -15 to -25 °C), and partly in the high price of the preparation (the supply price to the Czech Republic is in excess of 29 500 Euro). Other local preparations have also appeared in trials, with good results: e.g., RGTA (Cacicol20<sup>®</sup>, laboratoires Théa), thymosin beta-4, substance P, nicergoline or citicoline [4–7]. For financial reasons it was not possible to use eye drops from autologous serum, Cacicol20<sup>®</sup>, or the other mentioned agents for the treatment of the patient in our case report. For this reason, following an agreement with the patient, we decided upon a surgical procedure.

Surgical treatment is reserved for the 3rd stages of neurotrophic keratopathy, i.e., corneal ulceration not responding to conventional local therapy and/or connected complications. The most common surgical procedures include partial tarsorrhaphy, occlusion of the ocular aperture with the aid of application of botulotoxin into the levator palpebrae superioris muscle, conjunctival flap or transplantation of an amniotic membrane [11]. Small perforations can be treated effectively by cyanoacrylate or fibrin glue, larger defects may require lamellar or penetrating keratoplasty [4,12]. In the case of our patient, we progressively exhausted the available surgical methods. Partial tarsorrhaphy was performed, we did not consider the application of botulotoxin A due to its merely transitional effect, transplantations of an amniotic membrane were performed repeatedly. A conjunctival flap was not used, since after the procedure it is not possible to expect full restoration of corneal transparency. As a result, other therapeutic options were sought. The method of corneal neurotisation was chosen. This represents a procedure which is well documented in the foreign literature, although its use in Czech republic has not yet been published. The advantage of the procedure is causal influencing of the cause of corneal affliction, but it represents a demanding procedure, requiring a multidisciplinary approach and detailed postoperative observation [13,14]. The first mention of corneal neurotisation originates from 1972, when Samii described the connection of the main occipital nerve to the proximal part of the ophthalmic nerve with the aid of a graft of the sural nerve [13]. In 2009, Dr. Terzis first presented direct corneal neurotisation in cases of paralysis of the facial nerve with ipsilateral affliction of the trigeminal nerve and corneal anaesthesia. Terzis used transfer of a contralateral or supratrochlear nerve directly into a neurotrophic cornea [14].

In corneal neurotisation, the usual preference is for the supraorbital nerve, but it is also possible to use the supratrochlear nerve and in rare cases also the infraor-

bital nerve [15]. An ipsilateral approach is indicated only in cases when denervation is limited to the eyeball (i.e., only the long ciliary nerves are affected). In other cases, a contralateral approach is used, in which it is necessary to create a subcutaneous tunnel to the upper eyelid of the affected eye [8].

In the case of direct neurotisation following localisation and preparation, the supraorbital (or supratrochlear) nerve is coiled and threaded into the upper fornix of the affected eye. The exposed nerve fascicles are then drawn through the prepared tunnels in the subtenon space into the individual quadrants and fixed to the sclera by the limbus (perpendicular to the limbus). With regard to the limited length of the used nerve, an ipsilateral approach is usually used in direct neurotisation, although theoretically it is possible also to use a contralateral approach. The advantage of direct neurotisation is a more rapid course of re-innervation and the creation of only one new sensory defect (in the innervation region of the used nerve), the disadvantage is the necessity to create a large bicoronal incision.

In indirect neurotisation, the supraorbital (or supratrochlear) nerve is localised and threaded beneath the upper fornix of the orbit. A graft of the sensitive nerve (most often the sural nerve, in rare cases the great auricular nerve) is sutured onto the truncated nerve, end-to-end or end-to-side anastomoses are used. As in the case of direct neurotisation, the nerve graft is threaded into the upper fornix of the affected eye, the exposed nerve fascicles of the graft are drawn through tunnels in the subtenon space into the individual quadrants and fixed to the sclera into the perilimbal space. In indirect neurotisation it is possible to use both approaches, i.e., ipsilateral and contralateral. The disadvantage of this variant of the procedure is the longer duration of the operation, the longer time of corneal re-innervation and the creation of a further sensory defect (in the innervation region of the nerve used for the graft). In the case of our patient, it was not possible to use an ipsilateral approach, since the detailed preoperative neurological examination determined not only corneal anaesthesia but also hypoesthesia in the entire innervation region of the right trigeminal nerve. Due to the necessity of a contralateral approach, we decided to use an autologous nerve graft. Based on our experiences from preparatory operations on a cadaver, we decided in favour of anastomosis on the supraorbital nerve, which appeared stronger in comparison with the supratrochlear nerve, and therefore more appropriate for the procedure. The sural nerve was chosen as the source of the nerve graft with respect to its good accessibility and small postoperative denervation defect. The disadvantage of the selected approach is in particular the longer duration of the procedure, which could be reduced in future e.g., with the aid of parallel preparation of the sural nerve and preparation of skin and subconjunctival tunnels. The most demanding part of the procedure was the localisation and preparation of the sural nerve. Fixation of the individual nerve fascicles of the graft to the sclera of the affected eye is technically

demanding, fixation must be firm, but at the same time it is essential to prevent the traumatization of the very fragile nerve fascicles.

In 2018, Leyngold presented a minimally invasive endoscopic approach from the subgaleal space with the aid of a blunt endoscopic elevator to the upper orbital rim [15]. Due to the expected technical demand factor, an endoscopic approach was not selected for our patient. An interesting and promising modification of the procedure is the use of an alloimplant of the acellular nerve (Avance Nerve Graft, AxoGen) for indirect neurotisation [15,16]. However, the availability of these alloimplants is still low in the Czech Republic, and furthermore their wider use is so far restricted by the limited length of the alloimplant (up to 5 cm).

After surgical neurotisation of the cornea, re-innervation probably takes place through a combination of direct germination from the proximal nerve endings and the release of neurotrophic factors. Complete corneal neurotisation is evident 6 months to 2 years after surgery, in which the speed of neurotisation is influenced above all by patient age and comorbidities [17,18]. In our patient, the first signs of re-innervation of the cornea appeared 5 months after the procedure, which corresponded to our chosen approach with the use of a nerve graft. In our case report, corneal sensitivity before the procedure and during the postoperative period was observed with the aid of cotton wool buds, in future it shall be an advantage to use an esthesiometer for monitoring, or to objectify corneal neurotisation e.g., by means of in vivo confocal

corneal microscopy [19].

An early complication of the procedure may be haematoma, or infection of the wound. Later complications include primarily ineffective neurotisation and the development of neuroma in the region of anastomosis (in indirect neurotisation). We did not record any complications in our patient. However, in order to achieve a satisfactory effect, it was necessary to perform a re-transplantation of an amniotic membrane into the persistent defect.

## CONCLUSION

Direct and indirect corneal neurotisation with the use of the supraorbital, supratrochlear or infraorbital nerve represents a possibility for causal solution in patients with severe forms of neurotrophic keratopathy. In our case report of a young man with severe neurotrophic keratopathy in the right eye, the technique of indirect re-innervation of the cornea was used, with a graft of the sural nerve. The corneal finding in the patient in our case report improved markedly after the procedure, with the first signs of re-innervation appearing 5 months after surgery, with healing of chronic corneal ulceration, and 11 months after the procedure the cornea is entirely transparent with the exception of a vascularised macula in the temporal periphery. However, the procedure itself is technically demanding, the postoperative development is complex and requires careful monitoring, and in certain cases also the necessity of further surgical procedures.

## LITERATURE

- Sacchetti M, Lambiase A. Diagnosis and management of neurotrophic keratitis. *Clin Ophthalmol*. 2014 Mar;8:571-579.
- Hsu HY, Modi D. Etiologies, Quantitative Hypoesthesia, and Clinical Outcomes of Neurotrophic Keratopathy. *Eye Contact Lens*. 2015 Sep;41(5):314-317.
- Müller LJ, Marfurt CF, Kruse F, Tervo TM. Corneal nerves: structure, contents and function. *Exp Eye Res*. 2003 May;76(5):521-542.
- Versura P, Giannaccare G, Pellegrini M, Sebastiani S, Campos EC. Neurotrophic keratitis: current challenges and future prospects. *Eye Brain*. 2018 Jun;10:37-45.
- Dunn SP, Heidemann DG, Chow CY, et al. Treatment of chronic non-healing neurotrophic corneal epithelial defects with thymosin beta4. *Ann NY Acad Sci*. 2010;1194:199-206.
- Yamada N, Matsuda R, Morishige N, et al. Open clinical study of eye-drops containing tetrapeptides derived from substance P and insulin-like growth factor-1 for treatment of persistent corneal epithelial defects associated with neurotrophic keratopathy. *Br J Ophthalmol*. 2008;92(7):896-900.
- Cinar E, Yuce B, Aslan F, Erbakan G. Neuroprotective Effect of Citicoline Eye Drops on Corneal Sensitivity After LASIK. *J Refract Surg*. 2019 Dec 1;35(12):764-770.
- Weis E, Rubinov A, Al-Ghoul AR, Yau FM. Sural nerve graft for neurotrophic keratitis: early results. *Can J Ophthalmol*. 2018 Feb;53(1):24-29.
- Dua HS, Said DG, Messmer EM, et al. Neurotrophic keratopathy. *Prog Retin Eye Res*. 2018 Sep;66:107-131.
- Bonini S, Lambiase A, Rama P, et al. REPARO Study Group. Phase II Randomized, Double-Masked, Vehicle-Controlled Trial of Recombinant Human Nerve Growth Factor for Neurotrophic Keratitis. *Ophthalmology*. 2018 Sep;125(9):1332-1343.
- Krčová I, Stanislavová M, Peško K, Furdová A, Koller J. Možnosti použitia amniovej membrány – naše skúsenosti [Amniotic membrane applications - our experience]. *Cesk Slov Oftalmol*. 2016;72(6):204-208. Slovak.
- Fogle JA, Kenyon KR, Foster CS. Tissue adhesive arrests stromal melting in the human cornea. *Am J Ophthalmol*. 1980;89(6):795-802.
- Samii M. Autologe Nerven-Transplantation im Trigeminiusbereich. *Med Mitt*. 1972;46:189-94.
- Terzis JK, Dryer MM, Bodner BI. Corneal neurotization: a novel solution to neurotrophic keratopathy. *Plast Reconstr Surg*. 2009;123(1):112-120.
- Leyngold I, Weller C, Leyngold M, Tabor M. Endoscopic Corneal Neurotization: Technique and Initial Experience. *Ophthalmic Plast Reconstr Surg*. 2018 Jan/Feb;34(1):82-85.
- Leyngold IM, Yen MT, Tian J, Leyngold MM, Vora GK, Weller C. Minimally Invasive Corneal Neurotization With Acellular Nerve Allo-graft: Surgical Technique and Clinical Outcomes. *Ophthalmic Plast Reconstr Surg*. 2019 Mar/Apr;35(2):133-140.
- Malhotra R, Elalfy MS, Kannan R, Nduka C, Hamada S. Update on corneal neurotisation. *Br J Ophthalmol*. 2019 Jan;103(1):26-35.
- Fung SSM, Catapano J, Elbaz U, Zuker RM, Borschel GH, Ali A. In Vivo Confocal Microscopy Reveals Corneal Reinnervation After Treatment of Neurotrophic Keratopathy With Corneal Neurotization. *Cornea*. 2018 Jan;37(1):109-112.
- Mahelková G, Česká Burdová M, Odehnal M, Dotřelová D. In vivo corneal confocal microscopy: basic principles and applications. *Cesk Slov Oftalmol*. 2017;73(4):155-160. Available from: <http://www.cs-ophthalmology.cz/en/journal/articles/40>