

DIAGNOSTICS OF OPTIC DISC DRUSEN IN CHILDREN WITH SWEEP SOURCE OCT IMAGING

Danišová J., Fric E.

Department of Ophthalmology, Kyjov Hospital

The author of the study declares that no conflict of interests exists in the compilation, theme and subsequent publication of this professional communication, and that it is not supported by any pharmaceuticals company. The study has not been submitted to any other journal or printed elsewhere, with the exception of congress abstracts and recommended procedures.

Received: 2 November 2020

Accepted: 22 January 2021

Available on-line: 1 May 2021



MUDr. Jana Danišová
Oční oddělení Nemocnice Kyjov
Strážovská 1247/22
697 01 Kyjov
E-mail: mudrjanadanisova@gmail.com

SUMMARY

Aim: The aim of this retrospective study is to compare two methods of optic disc drusen imaging in pediatric patients – new swept source OCT technology with the B-scan ultrasonography, which has been assumed to be a gold standard in diagnosing optic disc drusen, and to compare pRNFL thickness in children with optic disc drusen and control group.

Methods: 14 eyes of 8 pediatric patients in whom optic disc drusen were confirmed by either B-scan ultrasonography, or swept-source OCT, were included in the study. We compared the sensitivity of these two imaging methods. Then we compared an average pRNFL thickness and pRNFL thickness in all four quadrants of our study group with the control group. Two statistical methods were used in data analysis – Mann-Whitney a Kruskal-Wallis test.

Results: The difference between SS-OCT and B-scan ultrasonography was not statistically significant in diagnosing optic disc drusen. Average pRNFL thickness was $135.29 \pm SD 31.2 \mu\text{m}$ in eyes with optic disc drusen, which is 24.15 % higher than in control group ($p = 0.00214$; $p = 0.00207$). pRNFL thickness of temporal ($p = 0.0001$; $p = 0.0001$), superior ($p = 0.03486$; $p = 0.03361$) and inferior ($p = 0.00652$; $p = 0.00627$) quadrant was statistically significantly higher in comparison with healthy controls, whereas the difference of pRNFL thickness in nasal quadrant was not statistically significant between the study and control group ($p = 0.09692$; $p = 0.0947$).

Conclusion: Swept source OCT is a promising new "gold standard" in optic disc drusen diagnostics in pediatric patients. An increase in pRNFL thickness values does not always confirm papilloedema as optic disc drusen may be the cause. Direct visualisation of optic disc drusen by swept source OCT can aid in differentiation from true papilloedema.

Key words: Optic disc drusen, swept source OCT, RNFL, ultrasonography

Čes. a slov. Oftal., 77, 2021, No. 2, p. 80–86

INTRODUCTION

Optic disc drusen are spherical, acellular hyaline deposits located in the prelaminar region of the optic disc of the optic nerve (ON), with a tendency towards calcification. Optic disc drusen are associated with a small papilla and a narrow scleral channel. It is assumed that drusen originate as a consequence of a malfunction of axoplasmic flow, through an excessive accumulation of calcified mitochondria.

The clinical prevalence of optic disc drusen is similar in both adults and children, and is within the range of 0.3% to 0.5%, on the basis of which it is presumed that drusen originate in early childhood [1,2,3]. The Copenhagen Child Cohort 2000 Eye Study used an EDI-OCT examination to detect the incidence of optic disc drusen in 1% of children at the age of 11–12 years [4]. An up to ten times higher prevalence of drusen in patients' relatives attests to the influence of genetics in the pathogenesis. Autosomal dominant heredity with incomplete penetration predominates [1,2,3,5,6]. According to histological studies the prevalence is higher, in as much as 1.7–2% of the

population [7,8]. The incidence of optic disc drusen in the Asian and African population is markedly less common than in the Caucasian race [1,3].

Optic disc drusen is usually a chance finding upon an ophthalmoscopic examination, and the patient is usually entirely asymptomatic. In many patients, clinically mute scotomas appear in the visual field. In rare cases, optic disc drusen are manifested through symptoms from these scotomas. Transient visual disturbances may also appear, which are probably the result of transitional ischemia caused by compression by drusen. Optic disc drusen may be accompanied also by vascular complications or in rare cases also macular edema [9,10,11].

In the great majority of cases in paediatric patients, optic disc drusen initially imitate swelling of the ON. The optic disc appears elevated, the edges of the disc are blunt and blurred. The drusen are deeply embedded in the papilla, and thus invisible on ophthalmoscopy. Over the course of time, the drusen probably increase in size and calcify. In older children there may be visible slight irregularity, predominantly on the nasal edge of the optic

disc, indicating enlarging, deeply embedded drusen, partially projecting into the peripapillary space. Elevation of the optic disc decreases or disappears entirely, thinning of the nerve fibre layer causes its fading, and the drusen become visible on the surface [1,2,3].

Differential diagnostics of an optic disc swelling is a challenge even for an experienced ophthalmologist. The term papilledema is reserved for swollen optic disc caused by increased intracranial pressure. Swollen optic disc may be caused also by other pathological states, e.g. intraocular neuritis, anterior ischemic neuropathy or increased venous pressure. Deep drusen may imitate incipient or chronic papilloedema. Optic disc drusen and papilloedema are both characterised by imprecise bordering and prominence of the optic disc, and scotomas may be present in the visual field. In both clinical units the temporal part of the optic disc is spared for a long period, thus also central visual acuity and colour perception is preserved. Photopsia and flickering may also appear [1]. Other conditions such as hypermetropic papilla, tilted disc and fibrae medullares may imitate papilloedema. Kovarik et al. [12] in their study determined that in 93% of children sent to an ophthalmologist with a finding of the swollen optic disc upon biomicroscopy, papilloedema was ruled out. Important steps in diagnostics are obtaining a detailed medical history and thorough examination of afferent and efferent functions of the visual pathway. The authors assert that if children do not suffer from further symptoms of increased intracranial pressure or a deterioration of vision, further examination is not urgent. An incorrect procedure in diagnostics often leads to unnecessary and burdensome examinations.

IMAGING METHODS

The gold standard for the diagnosis of optic disc drusen is considered to be **ultrasonography**. The drusen is displayed as an ovoid hyperechogenic lesion with an acoustic shadow in the region of the optic disc, which is visible even at lower levels of the ultrasonic signal. B-scan also displays calcifications which are invisible upon an ophthalmoscopic examination. The advantage of ultrasonography is high sensitivity, speed, non-invasivity, relatively low price of examination and zero radiation burden. The disadvantage is the low resolution of the image. Because optic disc drusen in children are more often fine, deeply embedded and less calcified, the sensitivity of ultrasonography in the diagnosis of optic disc drusen may be lower in children than in adults [5].

Optical coherence tomography (OCT) brought about a revolution in the imaging of ocular structures. It represents a fast, non-invasive and constantly developing imaging method, which enables the display of in vivo cross-sectional images with the use of low-coherence light. In 2008 the EDI (Enhanced Depth Imaging) module was presented, with improved imaging of the depth of the cross-section, by the simple method of shifting the point of maximum sensitivity in the direction towards the deep tissues – into the region of the sclera. However, this shift worsened the imaging of the vitreous body. In the case of

EDI-OCT it is therefore necessary to select an appropriate mode, on the basis of whether we wish to display deeper tissue, or the vitreoretinal interface [7,13].

The latest swept source technology uses a laser beam with an adjustable wavelength of light. The photo detector is a simple photo diode, and no spectrometer or line scan camera is required. The result is a higher scanning speed – an SS-OCT instrument is capable of recording up to 100 000 A-scans per second. By using a large wavelength (1050 nm), this method achieves deeper penetration into the ocular structures, which is not influenced by the reflectivity of the RPE and photoreceptors. This enables simultaneous imaging of the vitreous body and deep tissues [7,13,14,15,]. This technology enables detailed imaging of the optic disc as far as the lamina cribrosa, which could not previously be visualised by its predecessor – SD-OCT. Diagnostic methods such as ultrasonography and also for example CT focus on the detection of a calcification. OCT represents a promising contactless method in the diagnosis of drusen, including those which are non-calcified, fine and deeply embedded.

MORPHOLOGY OF DRUSEN ON OCT

In several publications there is a lack of consensus regarding the diagnosis of drusen on OCT. Since 2011, a number of studies have described drusen on OCT images as hyperreflective ovoid structures localised on the nasal edge of the optic disc [5]. Publications have also appeared in which drusen were described as hyporeflexive ovoid lesions with a hyperreflective margin. The assumption began to predominate that the hyperreflective structures were certain variants or precursors of drusen, but no correlation was demonstrated with histological findings of drusen. In 2015 the international scientific alliance The Optic Disc Drusen Studies (ODDS) Consortium was established [7,16]. Its work includes the recommendation for OCT diagnosis of optic disc drusen published in 2016. According to this recommendation, which we respect also in this study, a drusen is displayed on OCT as an oval, hyporeflexive lesion with hyperreflective margins in the prelaminar space. EDI-OCT and SS-OCT have provided better resolution in comparison with their predecessors and have even enabled imaging of the posterior edge of the drusen. According to this recommendation, it is further assumed that hyperreflective lesions, referred to as PHOMS (peripapillary hyperreflective ovoid mass-like structures), are rather a non-specific OCT finding of prelaminar peripapillary herniation and distension of axons in a variety of optic neuropathies (Fig. 1), and should not be indicated as drusen on OCT. PHOMS have been found in optic disc drusen [17] and papilloedema, in optic neuritis, in ischemic neuropathies and even in high myopia [7,16,18].

RNFL IN OPTIC DISC DRUSEN

Another indisputable advantage of OCT is measurement of the thickness of the individual layers of the retina. In optic disc drusen this specially concerns the thickness of the nerve fibre layer and the ganglion cell

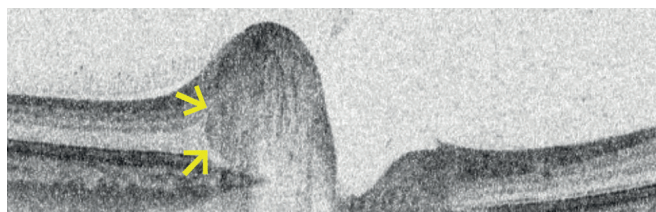

Fig. 1. Peripapillary hyperreflective ovoid mass-like structure (PHOMS) in one of our patients. This lesion should not be diagnosed as an optic disc drusen

complex. According to available studies, it appears that in the case of deeply embedded drusen, more commonly in children, RNFL thickness is normal or even increased, whereas in the case of surface drusen, evidently due to the impact of axonal damage, RNFL thickness decreases. A frequent indicator of axonal damage may also be the thickness of the macular complex of ganglion cells, mainly in the case of deep drusen, in which RNFL thickness may still be within the norm due to swelling [7,18]. According to the Copenhagen Child Cohort 2000 Eye Study, no difference was found in RNFL thickness between the eyes of children with and without drusen [4]. Noval et al. in their study described thickening of the RNFL in the case of deeply embedded drusen in children in comparison with a control group [19]. Malmqvist et al. conducted a study on adult patients with optic disc drusen and determined that RNFL thickness is dependent on the localisation of drusen. In the case of surface drusen, a thinning of the RNFL was present, correlating with defects in the visual field, whereas in the case of deeply embedded drusen thinning was not so evident [20]. Sato et al. in their study also determined a negative correlation between drusen size and RNFL thickness. A lower thickness of the RNFL was determined in the nasal part of the optic disc, where drusen are most frequently located [21].

COHORT AND METHOD

Our cohort incorporated the results of one examination of a total of 14 eyes of 8 paediatric patients with optic disc drusen, in whom diagnosis of optic disc drusen had been confirmed on at least one of the imaging methods B-scan ultrasonography and SS-OCT. All the patients from our cohort were examined at our centre in the period from February 2018 to December 2019. Age at the time of diagnosis was 4 to 14 years, average 8 years. The cohort included 5 girls and 3 boys. In two children optic disc drusen was a unilateral finding, in six it was determined bilaterally. In all patients we conducted measurement of refraction in cycloplegia, ophthalmoscopic examination of the ocular fundus in artificial mydriasis, examination of best corrected central visual acuity on a Snellen chart, ultrasonography and SS-OCT focusing on the qualitative imaging of the optic disc, with simultaneous quantitative measurement of the thickness of the peripapillary nerve fibre layer. Suspicion of a diagnosis of optic disc drusen was determined on the basis of a fundoscopic image. In all eyes an image of a pseudopapilloedema was

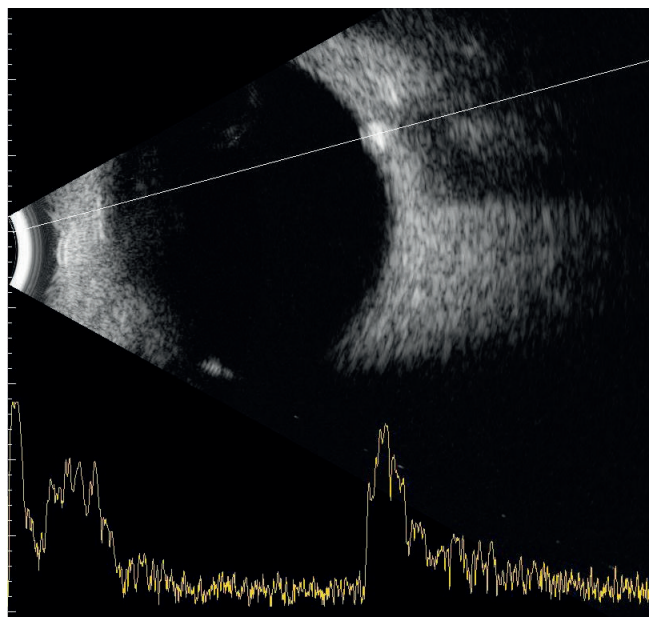


Fig. 2. Ocular ultrasound demonstrates optic disc drusen as hyper-echogenic focus within the optic disc

found, an ophthalmoscopically clear optic disc drusen was not visible in any of the patients. Ultrasonography of the eyeballs was performed using the instrument Accutome B-scan (Keeler), equipped with a broadband 12MHz probe. A B-scan was performed for a two-dimensional cross-sectional image of the eyeball and optic nerve, with the aim of identifying hyperechogenicity in the area of the optic disc, corresponding to drusen. The examination on all children was conducted in such a manner that the signal was not altered by its passage through the lens. After identification of lesion hyperechogenicity in the region of the optic disc, the image was converted by an A-scan cross-vector into an orientational display of reflectivity (Fig. 2). In order to prevent false positive results, the signal of the image was weakened, and after this weakening of the signal, hyperechogenicity of the optic disc had to be clearly distinguishable.

On all the children we also conducted an OCT examination of the optic disc on the instrument Deep Range Imaging OCT Triton (Topcon). DRI OCT Triton is a swept source device, which uses a light source with a wavelength of 1050 nm, the scanning speed is 100 000 A-scans per second and its axial resolution is 8 μm . It contains an eye-tracking system and an invisible scanning beam, which limits unwanted eye movements during the examination. After reviewing the scans, we identified drusen as a hyporeflexive ovoid lesion with partial hyperreflective margins. Examples of OCT images of optic disc drusen in our patients can be seen in Fig. 3. Fig. 4 and 5 present further examples of optic disc drusen in our patients as a combination of images from fundoscopic, ultrasound and SS-OCT scans.

The thickness of the peripapillary RNFL (hereinafter referred to as pRNFL) with centration on the optic disc was measured in a 3D scan of the papilla 6.0 mm x 6.0 mm. The average value of pRNFL was recorded in this scan. The thickness of the pRNFL was also recorded in the superior (S), inferior

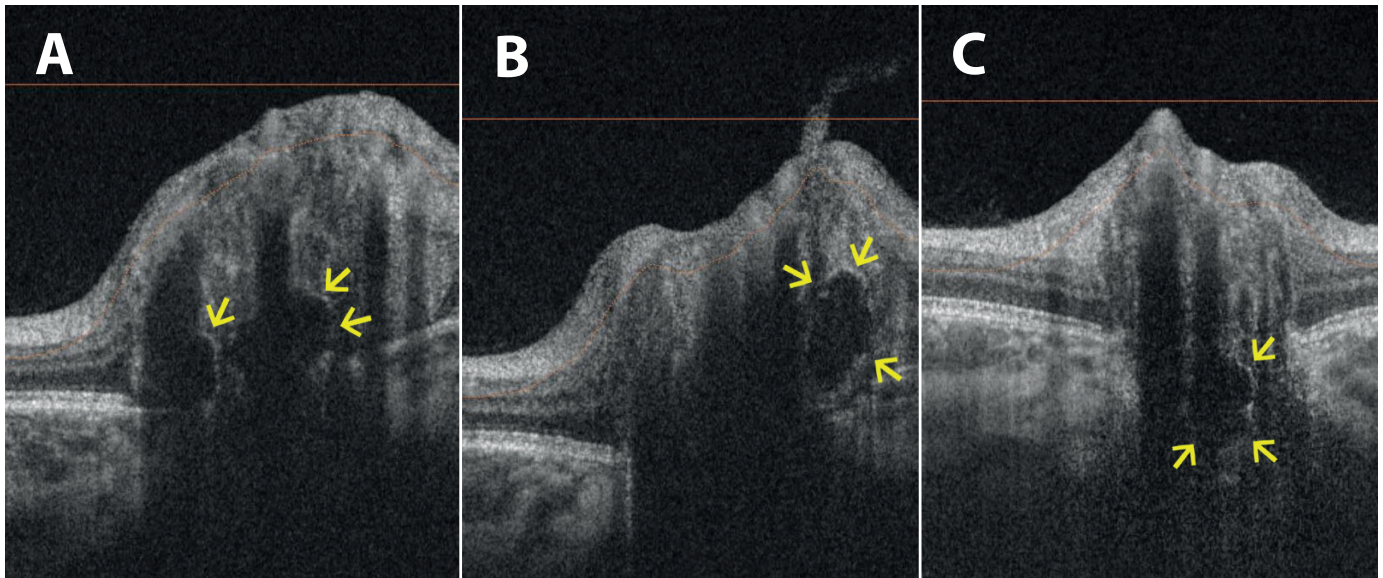


Fig. 3. On linear horizontal transpapillary swept source OCT scans we observe optic disc drusen as hyporeflective lesions with hyperreflective margins
(A) Two deeply embedded optic disc drusen and pseudopapilloedema in 11-year-old patient. **(B)** Another lesion in different cross-section of the same scan. **(C)** Deeply embedded lesion in 5-year-old patient

(I), temporal (T) and nasal (N) quadrant. With regard to the fact that the instrument contains a normative database that incorporates measurements on probands aged over 18 years, we compared our studied cohort of eyes with optic disc drusen against a control group composed of 32 eyes of 16 healthy children aged between 3 and 15 years, with an average age of 9 years. The control group comprised 10 boys and 6 girls with a physiological finding on the ocular fundus, with BCVA of 5/5 in both eyes and with measured refraction in cycloplegia within the range of -2.0D to +3.5D of spherical equivalent. All the patients from the study group were entirely asymptomatic, neither cephalgia nor any other neurological symptoms were determined in any of the patients. Despite this, we sent 6 children for a specialist neurological examination and 5 children for magnetic resonance imaging of the brain for possible coexistence of optic disc drusen and increased intracranial pressure. The finding was physiological in all the children. We statistically evaluated the sensitivity of ultrasonography and SS-OCT examination with the aid of a chi-quadrat test on a level of significance of <0.05. We also statistically evaluated pRNFL thickness in eyes with optic disc drusen and pRNFL thickness in eyes from the control group with the aid of Mann-Whitney and Kruskal-Wallis tests, on a level of significance of <0.05.

RESULTS

In 13 eyes, optic disc drusen were clearly demonstrated sonographically, in 1 eye the finding was ambiguous – in the region of the optic disc with suspected drusen, the hyperechogenic lesion was not displayed convincingly, i.e., after reduction of the signal this lesion disappeared. With the aid of SS-OCT, drusen were demonstrated in 11, of which it was confirmed in 1 eye in which the finding was ambiguous on ultrasound, while in 3 eyes drusen was not visible in the OCT

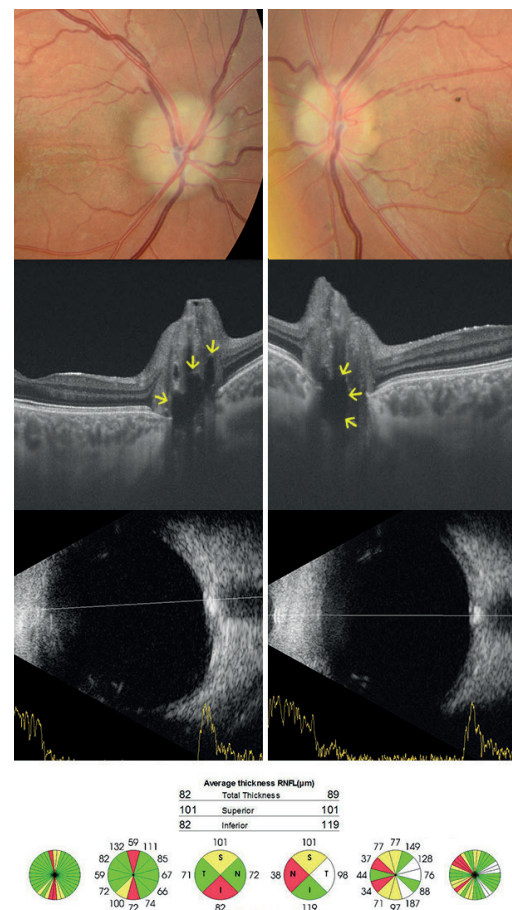


Fig. 4. Bilateral fundus photography of the oldest patient in our study group shows pseudopapilloedema and subtle pallor of optic disc. There are multiple hyporeflective lesions in linear horizontal transpapillary swept source OCT scans corresponding to optic disc drusen. Optic disc drusen are highly reflective on ultrasound B-scan. Average thickness of the peripapillary retinal nerve fibre layer (pRNFL) is reduced

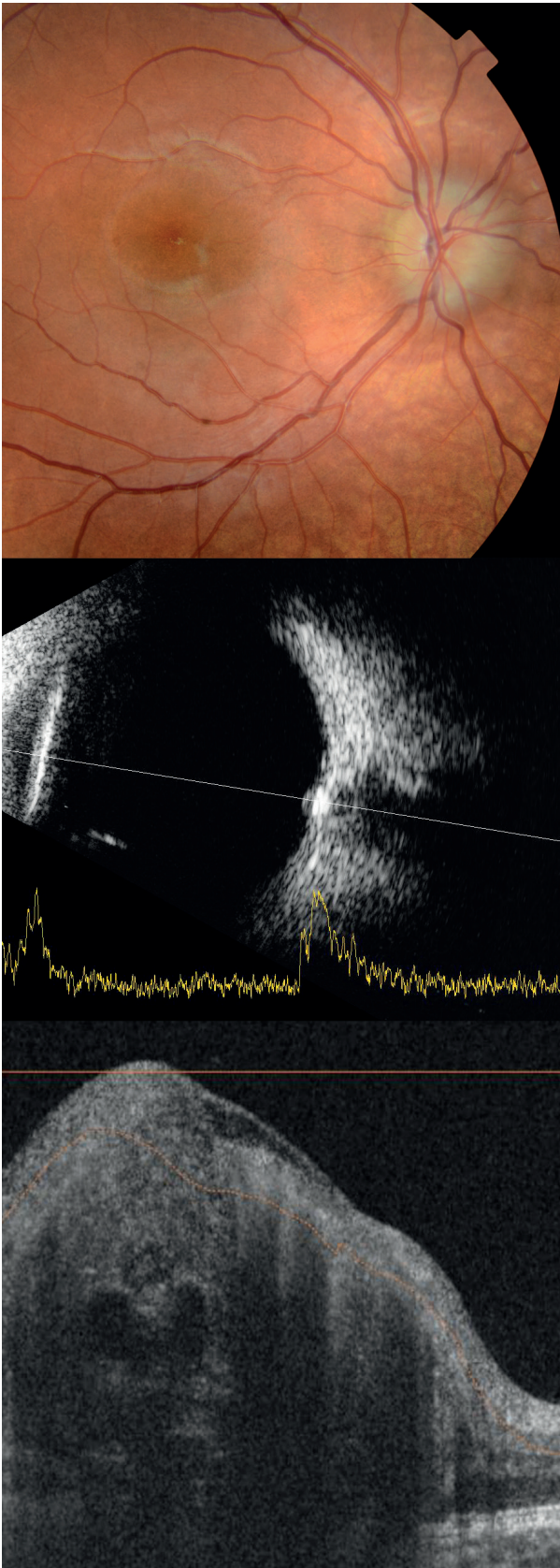


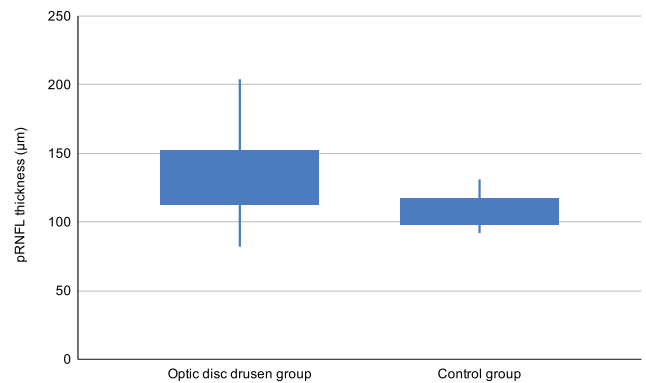
Fig. 5. Fundus photography of right eye of 8-year-old patient shows pseudopapilledema, predominantly temporally. Echogenic lesion of optic disc is displayed sonographically. Multiple small optic disc drusen are seen as hyporeflective ovoid lesions with hyperreflective margins on swept source OCT scan. Vessels with typical shadowing are also visible

image. Using the chi-squared test we did not determine a statistically significant difference between these two methods in the diagnosis of optic disc drusen ($p = 0.280087$).

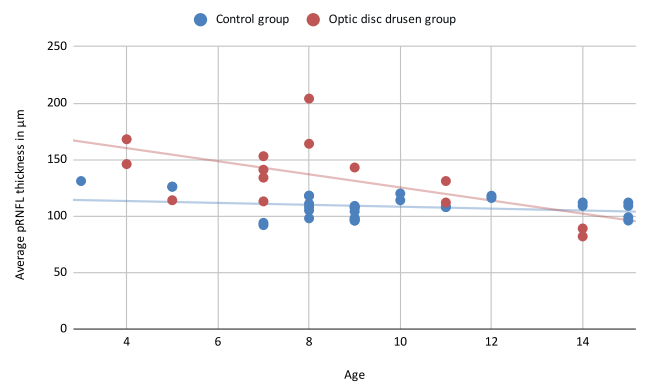
In all the children we also examined peripapillary thickness of the RNFL. Average pRNFL thickness in the control group was $108.97 \pm SD 10.0 \mu m$. Average pRNFL thickness in the group of eyes with optic disc drusen was $135.29 \pm SD 31.2 \mu m$, thus on average 24.15 % greater (Graph 1). The quality index of the OCT images in the group of children with optic disc drusen was on average 60.93. We also measured pRNFL thickness in the individual quadrants – the measured values are presented in table 1.

In the group with optic disc drusen, greater variability was recorded in pRNFL thickness, mainly in the lower and upper quadrant.

With the aid of 2 non-parametric tests – Mann-Whitney and Kruskal-Wallis test – we attempted to confirm the difference in pRNFL thickness between in the group with optic disc drusen and the control group on a level of significance of 0.05. Average pRNFL thickness in the group of eyes with optic disc drusen is statistically significantly higher than in the control group ($p = 0.00214$; $p = 0.00207$), which applies also to pRNFL thickness measured in the temporal quadrant ($p = 0.0001$; $p = 0.0001$), upper quadrant ($p =$



Graph 1. Comparison of average peripapillary retinal nerve fiber layer (pRNFL) thickness values in optic disc drusen group and control group



Graph 2. Comparison of average thickness of peripapillary retinal nerve fiber layer (pRNFL) in optic disc drusen group and control group relative to age

Table 1. Average thickness of peripapillary retinal nerve fibre layer (pRNFL) and pRNFL thickness in each quadrant in optic disc drusen and control group

	Average pRNFL thickness	Thickness of temporal pRNFL	Thickness of superior pRNFL	Thickness of nasal pRNFL	Thickness of inferior pRNFL
ODD group	135,29 ± SD 31,2	105,21 ± SD 16,73	157,14 ± SD 40,29	85,14 ± SD 19,85	192,07 ± SD 58,2
Control group	108,97 ± SD 10,0	80,56 ± SD 14,69	135,06 ± SD 14,54	78,69 ± SD 11,02	142,28 ± SD 17,37

0.03486; $p = 0.03361$) and lower quadrant ($p = 0.00652$; $p = 0.00627$). The difference was not statistically significant in the nasal quadrant ($p = 0.09692$; $p = 0.0947$).

In graph 2 it is possible to demonstrate the development of pRNFL thickness in eyes with optic disc drusen in relation to age. In younger children, pRNFL thickness is greater than in the control group, and decreases with age. In the oldest patient (14 years), average pRNFL thickness and pRNFL thickness in the individual quadrants is reduced in comparison with controls of the same age, which corresponds to axonal degeneration.

DISCUSSION

The influence of drusen on RNFL thickness is described in several publications. Thinning of the RNFL represents axonal degeneration, which correlates with defects in the visual field. A reduction of pRNFL thickness was determined in patients with surface drusen in comparison with deeply embedded drusen [20]. Several studies have attempted to differentiate optic disc drusen from papilloedema with the aid of OCT. Sarac et al. in their study state that RNFL thickness in particular may be useful in differential diagnostics. According to this finding, RNFL thickness in the case of optic disc drusen is the same as in the control group, whereas papilloedema is manifested in thickening of the RNFL [22]. Kulkrani et al., in a comparison of two groups of patients – with optic disc drusen and with a mild degree of papilloedema – determined that there was no difference in RNFL thickness between these two groups. In patients with surface drusen, RNFL thickness was demonstrated to be a reliable marker in differentiation from papilloedema, but in young patients and children with deeply embedded drusen RNFL thickness was normal or greater [3,23], which was demonstrated also in our cohort of patients. It is therefore not possible to differentiate papilloedema from optic disc drusen reliably solely on the basis of RNFL values.

We explain the higher values of pRNFL in our patients with reference to the selection of the sample. The cohort comprised children with optic disc drusen identified at a paediatric eye clinic on the basis of suspected papilloedema. With reference to the fact that all the patients in our cohort were entirely asymptomatic, as well as the fact that in the children examined further there was a negative neurological finding, and the finding on magnetic resonance imaging and the ophthalmoscopic finding remained unchanged even over the course of time at follow-up examinations, it is possible to assume that incre-

ased pRNFL thickness may appear in deeply embedded optic disc drusen in children. A recent histopathological study also confirms thickening of the RNFL in the case of deep drusen [8]. With regard to the absence of a normative database for paediatric probands in the DRI OCT Triton instrument, we compared the study cohort with a control group with an average age of 9 years. Our referential value corresponds to the referential values in the literature [24,25].

The values of pRNFL thickness related to age presented in graph 2 correspond to the results in the available studies – deeply embedded drusen in children do not cause a decrease of pRNFL, while with increasing age drusen become more superficial and cause axonal damage and a reduction of pRNFL. It would be interesting to examine the relationship between pRNFL thickness in optic disc drusen and age with the aid of a linear regression analysis, but a limitation in this study is the small sample of patients, due to the low incidence of this diagnosis.

As yet, few studies have been conducted on optic disc drusen with the aid of SS-OCT, and the studies that exist often contain only a small sample of patients [15,25]. No study comparing SS-OCT with ultrasonography in the diagnosis of drusen has been published to date. Merchant et al. determined that EDI-OCT enables the identification of optic disc drusen better than ultrasonography [26]. In some studies, drusen of the optic disc are considered to be "PHOMS", and for this reason the results of these studies were not compared with our results. These lesions should be differentiated from drusen because they are not autofluorescent, they are not visible on ultrasound and do not correspond to clinically visible drusen. As yet, their origin is not entirely clear, and morphologically they rather correspond to axonal distension [3,8,16,27].

In this study, SS-OCT and ultrasonography are relatively comparable in the diagnosis of optic disc drusen. The advantage of SS-OCT is the high resolution of the image and the possibility of measuring RNFL thickness. So far, we cannot entirely exclude optic disc drusen and confirm papilloedema by means of the absence of drusen on OCT scans. A limitation of SS-OCT is artefacts caused by shadows of blood vessels and tissues of the optic disc, motion artefacts and background noise. In future, advances in OCT technologies will undoubtedly bring better visualisation of deep structures and further improved resolution, without shadows and artefacts, and thereby over the course of time bring better differentiation of optic disc drusen from incipient or chronic papilloedema.

We shall observe the morphology of drusen and quantitative parameters in our patients with optic disc drusen with the aid of SS-OCT also in future years.

CONCLUSION

An image of optic disc swelling in children is a relatively common finding. Deep optic disc drusen are often incorrectly evaluated as incipient papilloedema caused by intracranial hypertension, and patients are exposed to unnecessary, invasive and last but not least also very expensive examinations. Sonographic examination need not always be entirely unambiguous in children. It appears that advances in the development of OCT technology may elevate this method to the status of the new "gold standard" in the diagnosis and mo-

onitoring of deep optic disc drusen, since it represents a fast, non-invasive examination with high sensitivity, which enables high resolution of the image and incorporates other functions such as the measurement of individual layers of the retina, which may be influenced by drusen. Increased thickness of the pRNFL need not always mean swelling. In the case of pseudopapilloedema, optic disc drusen can best be differentiated by means of direct demonstration of drusen in the disc of the optic nerve on transpapillary OCT scans. However, it is still necessary to consider also rare but possible coexistence of optic disc drusen and papilloedema

LITERATURE

1. Brodsky MC. Pediatric Neuroophthalmology. 3rd ed. Rochester (USA): Springer; 2016. Chapter 3, The Swollen Optic Discs in Children; p.167-180.
2. Otradovec J. Klinická neurooftalmologie. Praha (ČR): Grada; 2003. 504.
3. Palmer E, Gale J, Crowston JG, Wells AP. Optic Nerve Head Drusen: An Update. Neuroophthalmology. 2018 Apr 25;42(6):367-384.
4. Malmqvist L, Li XQ, Eckmann CL, et al. Optic Disc Drusen in Children: The Copenhagen Child Cohort 2000 Eye Study. J Neuroophthalmol. 2018 Jun;38(2):140-146.
5. Chang MY, Pineles SL. Optic disc drusen in children. Surv Ophthalmol. 2016 Nov-Dec;61(6):745-758.
6. Gerinec A. Detská oftalmológia. Bratislava (SR): Osveta; 2005. 592.
7. Fraser JA, Bursztyn LLCD. Optical coherence tomography in optic disc drusen. Ann Eye Sci. 2020;5:5-5.
8. Skougaard M, Heegaard S, Malmqvist L, et al. Prevalence and histopathological signatures of optic disc drusen based on microscopy of 1713 enucleated eyes. Acta Ophthalmologica. 2020 Mar;98(2):195-200.
9. Štrofová H, Jarošová A. Drúzy papily zrakového nervu a jejich komplikace [Optic Disc Drusen and their Complications]. Cesk Slov Oftalmol. 2016;72:298-308. Czech.
10. Čmelo J, Valášková J, Krásnik V. The optic nerve drusen and hemodynamics. Cesk Slov Oftalmol. 2019;75(5):252-256. doi: 10.31348/2019/5/2
11. Beňová A, Kuthan P, Kousal B, et al. Příběh jedné papily [Story of the Papilla - a Case Report]. Cesk Slov Oftalmol., 2015;71:116-121. Czech.
12. Kovarik JJ, Doshi PN, Collinge JE, Plager DA. Outcome of pediatric patients referred for papilledema. J AAPOS. 2015 Aug;19(4):344-348.
13. Silverman AL, Tatham AJ, Medeiros FA, Weinreb RN. Assessment of optic nerve head drusen using enhanced depth imaging and swept source optical coherence tomography. J Neuroophthalmol. 2014 Jun;34(2):198-205.
14. Cole ED, Duker JS. OCT Technology: Will We Be "Swept" Away? [Internet] Reviewofophthalmology.com 2021 [cited 16 January 2021]. Available from: <https://www.reviewofophthalmology.com/article/oct-technology-will-we-be-swept-away>
15. Miller AR, Roisman L, Zhang Q, et al. Comparison Between Spectral-Domain and Swept-Source Optical Coherence Tomography Angiographic Imaging of Choroidal Neovascularization. Invest Ophthalmol Vis Sci. 2017 Mar 1;58(3):1499-1505.
16. Malmqvist L, Sibony PA, Fraser CL, et al. Optic Disc Drusen Studies Consortium. Peripapillary Ovoid Hyperreflectivity in Optic Disc Edema and Pseudopapilledema. Ophthalmology. 2018 Oct;125(10):1662-1664.
17. Teixeira FJ, Marques RE, Mano SS, et al. Optic disc drusen in children: morphologic features using EDI-OCT. Eye. 2020 Sep;34(9):1577-1584.
18. Tuğcu B, Özdemir H. Imaging Methods in the Diagnosis of Optic Disc Drusen. Turk J Ophthalmol. 2016 Oct;46(5):232-236.
19. Noval S, Visa J, Contreras I. Visual field defects due to optic disc drusen in children. Graefes Arch Clin Exp Ophthalmol. 2013 Oct;251(10):2445-2450.
20. Malmqvist L, Wegener M, Sander BA, Hamann S. Peripapillary Retinal Nerve Fiber Layer Thickness Corresponds to Drusen Location and Extent of Visual Field Defects in Superficial and Buried Optic Disc Drusen. J Neuroophthalmol. 2016 Mar;36(1):41-45.
21. Sato T, Mrejen S, Spaide RF. Multimodal Imaging of Optic Disc Drusen. Am J Ophthalmol. 2013;156(2):275-282.
22. Sarac O, Tasci YY, Gurdal C, Can I. Differentiation of optic disc edema from optic nerve head drusen with spectral-domain optical coherence tomography. J Neuroophthalmol. 2012 Sep;32(3):207-211.
23. Malmqvist L, Bursztyn L, Costello F, et al. The Optic Disc Drusen Studies Consortium Recommendations for Diagnosis of Optic Disc Drusen Using Optical Coherence Tomography. J Neuroophthalmol. 2018 Sep;38(3):299-307.
24. Turk A, Ceylan OM, Arici C, et al. Evaluation of the nerve fiber layer and macula in the eyes of healthy children using spectral-domain optical coherence tomography. Am J Ophthalmol. 2012 Mar;153(3):552-559.
25. Yanni SE, Wang J, Cheng CS, et al. Normative reference ranges for the retinal nerve fiber layer, macula, and retinal layer thicknesses in children. Am J Ophthalmol. 2013 Feb;155(2):354-360.
26. Merchant KY, Su D, Park SC, et al. Enhanced depth imaging optical coherence tomography of optic nerve head drusen. Ophthalmology. 2013 Jul;120(7):1409-1414.
27. Lee KM, Woo SJ, Hwang JM. Differentiation of optic nerve head drusen and optic disc edema with spectral-domain optical coherence tomography. Ophthalmology. 2011 May;118(5):971-977.