

# DIAGNOSES THAT MIMIC PACHYCHOROID DISEASES OF THE MACULA – CASE REPORTS

Tesař J.<sup>1</sup>, Šín M.<sup>1</sup>, Němec P.<sup>1</sup>, Studnička J.<sup>2</sup>

<sup>1</sup> Department of Ophthalmology, Central Military Hospital – General University Hospital, Prague

<sup>2</sup> Charles University, Faculty of Medicine in Hradec Králové, Department of Ophthalmology University Hospital, Hradec Králové, Department of Ophthalmology

## Sworn declaration:

The authors of the study declare that no conflict of interest exists in the compilation, theme and subsequent publication of this professional communication, and that it is not supported by any pharmaceuticals company. The study has not been submitted to any professional journal or printed elsewhere, with the exception of congress abstracts and recommended procedures.

Received: 27 September 2020

Accepted: 22 December 2020

Available on-line: 11 March 2021



MUDr. Jan Tesař, FEBO  
Oční klinika, Ústřední vojenská nemocnice – všeobecná fakultní nemocnice v Praze  
U Vojenské nemocnice 1200  
169 02 Praha 6  
jan.tesar@uvn.cz

## SUMMARY

Pachychoroid disease of retina is a spectrum of diseases manifested by thickening and hyperperfusion of the choroid with changes in the sensory part of the retina. The main unit of this group is central serous chorioretinopathy (CSC). In practice, we often encounter other conditions, which are manifested by thickening of the choroid and changes in the retina, but they cannot be classified as pachychoroid diseases. The aim of this study is to point out on a series of 3 case reports the difficulties in the differential diagnosis of retinal diseases in which we find thickening of the choroid.

**Case report 1:** 42-year-old patient treated for central serous chorioretinopathy. After optical coherence tomography (OCT), fluorescence angiography (FAG) and indocyanine green angiography (ICG) the diagnosis was changed to choroidal hemangioma and he was treated with photodynamic therapy (PDT) which led to a reduction of the hemangioma.

**Case report 2:** A 30-year-old patient treated for ankylosing spondylitis comes for visual impairment in the left eye. On OCT the condition resembled chronic CSC. The patient suffered from a febrile exanthema a few days ago. Serological testing for coxsackievirus was positive and the diagnosis was changed to acute chorioretinitis in coxsackievirus infection. Oral treatment with prednisone was successful.

**Case report 3:** A 46-year-old patient was treated conservatively for CSC. After FAG and ICG, a solitary dilated choroidal vessel was found in the area of the papillomacular bundle with leakage under the sensory epithelium which was diagnosed as choroidal macrovessel. We performed PDT with a very good anatomical effect.

**Conclusion:** Precise differentiation of these mentioned diseases from pachychoroid retinal diseases was essential in choosing the appropriate therapy. The use of all modern imaging methods of the retina and choroid plays a key role in determining the diagnosis.

**Key words:** pachychoroid disease, central serous chorioretinopathy, choroidal hemangioma, chorioretinitis, coxsackievirus, choroidal macrovessel

Čes. a slov. Oftal., 77, 2021, No. 1, p. 36–44

## INTRODUCTION

Modern imaging methods, headed by optical coherence tomography (OCT) and its mode EDI (enhanced depth imaging) have enabled us to better observe thickening of the choroid, as well as its structural changes such as dilation of individual vessels or its pathological course. A pathological value of choroidal thickening is considered to be <300 μm subfoveally.

Pachychoroid diseases of the macula cover conditions in which thickening of the choroid takes place in the macular region, by means of dilation of vessels of the Haller's layer, with subsequent hyperperfusion of these vessels [1]. This results in the destruction of cells of the retinal pigment epithelium (RPE) and an infiltration of fluid beneath the sensory epithelium (SE). The basic clinical unit is central serous chorioretinopathy (CS), in which we distinguish between acute and chronic form. Other units from the set of pachychoroid diseases of the retina include pachychoroid pigment epitheliopathy (PPE), in which destruction of the RPE cells takes place without manifest collection of fluid beneath the SE, as well as pachychoroid neovasculopathy (PNV), in which we most often demonstrate an occult choroidal neovascular membrane (CNV) in the region of undulation of the RPE, and ablation of the SE. The last clinical unit is polypoid choroidal vasculopathy (PCV), in which we also find thickening of the choroid, accompanied by sacciform dilation of the choroidal vessels – polyps.

## CASE REPORT 1

A 42 year old male patient was observed and conservatively treated for CSC with chronic ablation of the SE. Due to persistent ablation of the SE, the patient was sent to our retinal centre for an additional examination. He subjectively complained of occasionally flashing and blurring of the image in the right eye. He negated eye pain and metamorphopsia, and described the condition as persistent.

Best corrected visual acuity (BCVA) in the right eye was 1.0, and in the left eye also 1.0. The finding on the anterior segment corresponded to the patient's age. On the ocular fundus of the right eye a number of whitish deposits were visible, without pronounced elevation of the retina in the macula around the optic nerve. There was no presence of haemorrhage, and the finding on the vessels and in the periphery was within the norm (Fig. 1). On OCT there was evident ablation of the SE in the nasal part of the macula, beneath the SE hyperreflexive deposits were visible, corresponding to the whitish deposits on the retina (Fig. 2). Intraretinally the retina was within the norm. There was conspicuous prominence of the choroid in the proximity of the optic nerve papilla in the superonasal part of the macula, especially upon the use of EDI mode. Fluorescence angiography (FAG) and indocyanine green angiography (ICGA) were performed, demonstrating early and progressive hyperfluorescence, which exceeded the deposit of ablation of the SE (Fig. 3, 4). The total scope of the saturating deposit was as much as 5x7 DA (disc area) on a wide-angle image. In the region by the papilla there were hyperfluorescent deposits, corresponding with exudates beneath the SE. Configuration of the vessel and speed of filling were within the norm in both eyes. Magnetic resonance imaging was performed, with a negative finding, and suspicion of choroidal haemangioma was stated.

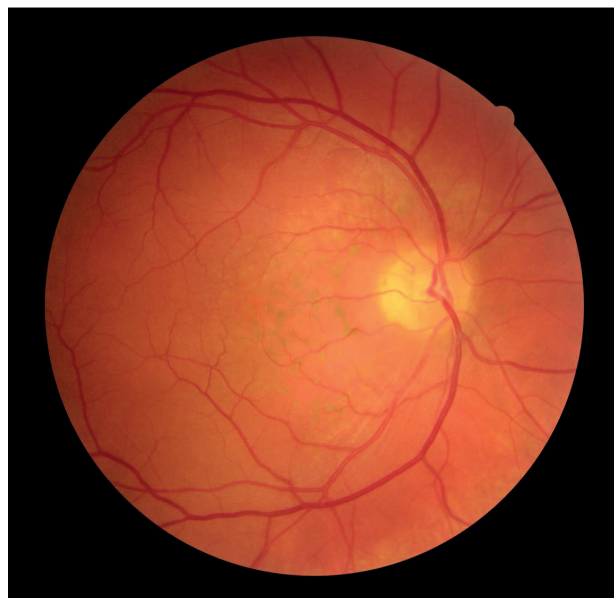Due to the patient's good visual acuity and minimal subjective complaints, we decided only to observe the patient's finding. However, one year later the patient reported to us with a decrease of BCVA to 0.3 and subjective deterioration. We decided in favour of treatment with the aid of reduced photodynamic therapy (PDT) in three

deposits in the nasal region of the macula, where exudative activity was greatest. As a pre-treatment we used intravitreal application of aflibercept.

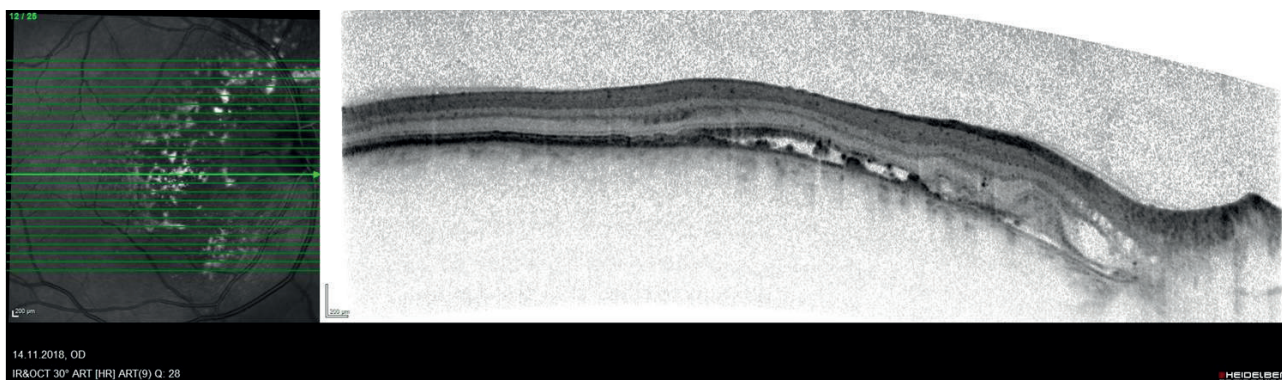
Four months after treatment, the patient's condition was stabilised, with thinning of the choroidal deposit and a reduction of ablation of the SE (Fig. 5). BCVA was stabilised at 0.5 and subjectively the patient ceased to notice flashing of the image, even if he was aware of a reduction of quality of vision in comparison with the other eye.

## DISCUSSION

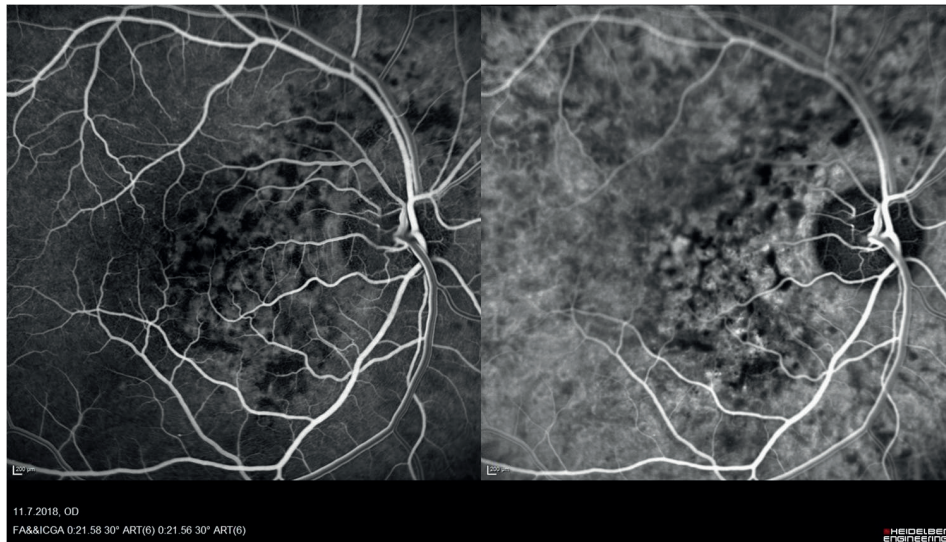
Choroidal haemangioma is a benign vascular hamartoma, which is manifested as an orange, individual unilateral mass by the posterior pole of the eye. We divide it into two types: diffuse and bordered. The diffuse type is generally a component of Sturge-Weber syndrome. Histologically we distinguish between capillary, cavernous and mixed types. The cells of the vascular wall do not manifest signs of proliferation, and if the tumour increases in size this is rather due to vas-



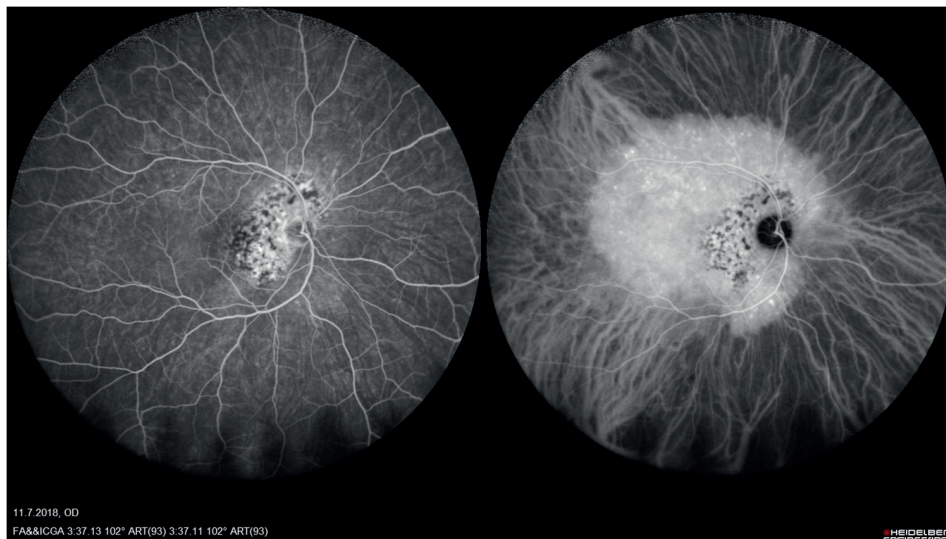**Fig. 1.** Image of ocular fundus of right eye of patient with choroidal haemangioma



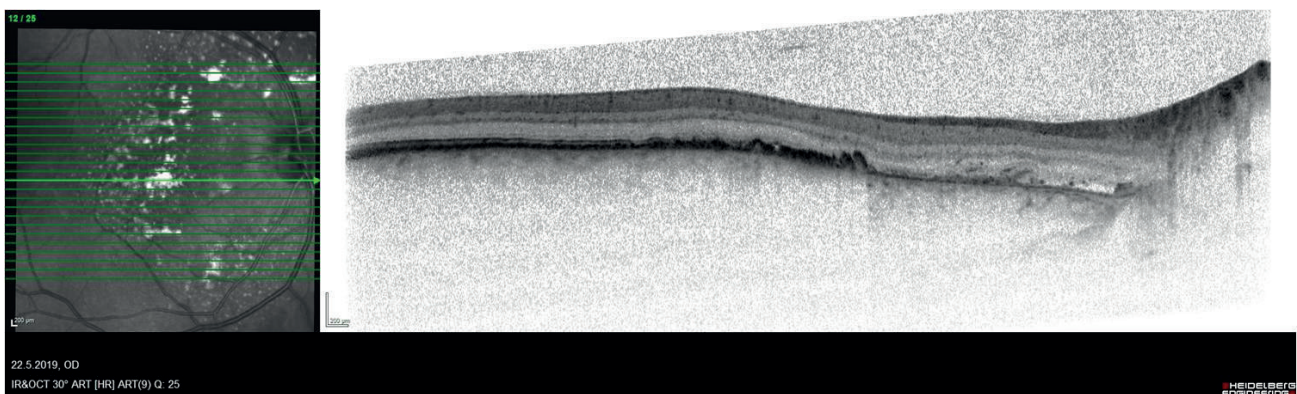
**Fig. 2.** Optical coherence tomography image of right eye of patient with choroidal haemangioma



**Fig. 3.** Fluorescence angiography and indocyanine green angiography images of choroidal haemangioma



**Fig. 4.** Wide-angle fluorescence angiography and indocyanine green angiography images of choroidal haemangioma



**Fig. 5.** Optical coherence tomography image of patient after photodynamic therapy, with visible reduction of ablation of sensory epithelium

cular congestion than multiplication of the actual tumour cells [2,3]. It is frequently accompanied by serous ablation of the SE and cystoid macular edema. Macrophages with lipofuscin may be found in the subretinal space, producing a yellowish-white appearance [4]. The formation of a fibrous scar, ossification of the tumour and the formation of a neovascular membrane are rare but observed phenomena [2]. The ganglion cell layer is almost never afflicted [5]. The fundamental examination methods include OCT, FAG and ICG angiography, ultrasound (US) and magnetic resonance imaging. On ICG angiography we observe early "laced" hyperfluorescence, and in the later phases, by contrast we observe "wash-out" of colour and hypofluorescence [6,7,8]. On a US A scan we find high internal reflexiveness, which helps distinguish haemangioma from choroidal melanoma [9]. OCT images help distinguish secondary changes of the retina, and in EDI mode help analyse the internal structure of the tumour [10]. The average age of onset of complaints is between twenty and fifty years [2,3]. It is sufficient only to observe asymptomatic lesions, while symptomatic lesions can be treated with the aid of photodynamic therapy, laser photocoagulation, radiotherapy, brachytherapy with the aid of a local emitter, transpupillary thermotherapy, proton therapy and anti-VEGF therapy. PDT appears to be the method producing the best results, while ensuring minimal destruction of tissue, even if its options are limited, especially in the case of more extensive lesions [11]. Repeated PDT brings a risk of choroidal atrophy and degeneration of the neuroretina [12].

In differential diagnostics, it is important to differentiate haemangioma from amelanotic choroidal melanoma, choroidal nevus, choroidal metastasis, CSC, choroidal osteoma and posterior scleritis.

## CASE REPORT 2

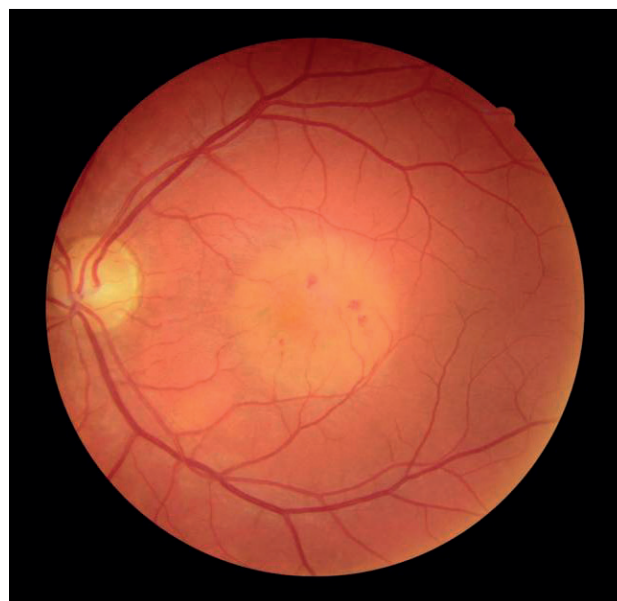A 30 year old male patient reported to our centre due to deterioration of vision in the left eye persisting for 2 days. He stated a blind spot in the centre of the visual field, and negated eye pain. A number of days before the onset of the complaints, the patient, his wife and 3 year old child had suffered from a febrile illness with exanthema of the palms and soles of the feet, which spontaneously subsided in all members of the family. Our patient has been receiving treatment for ankylosing spondylitis with the aid of biological treatment by adalimumab (Humira) for 10 years, without pronounced clinical manifestations.

Vision in the right eye was 1.0 naturally, in the left eye movement with correct light projection, IOP was within the norm, the finding on the anterior segment was commensurate to age. In the region of the macula of the left eye, there was an ophthalmoscopic finding of a rounded greyish-yellow deposit with the size of 2 papillary diameter without elevation, 3 very small haemorrhages and indication of dysgrouping of pigment of the salt and pepper type. The finding in the vessels and in the periphery of the retina was within the norm (Fig. 6). On OCT images of the macular landscape we found disintegrati-

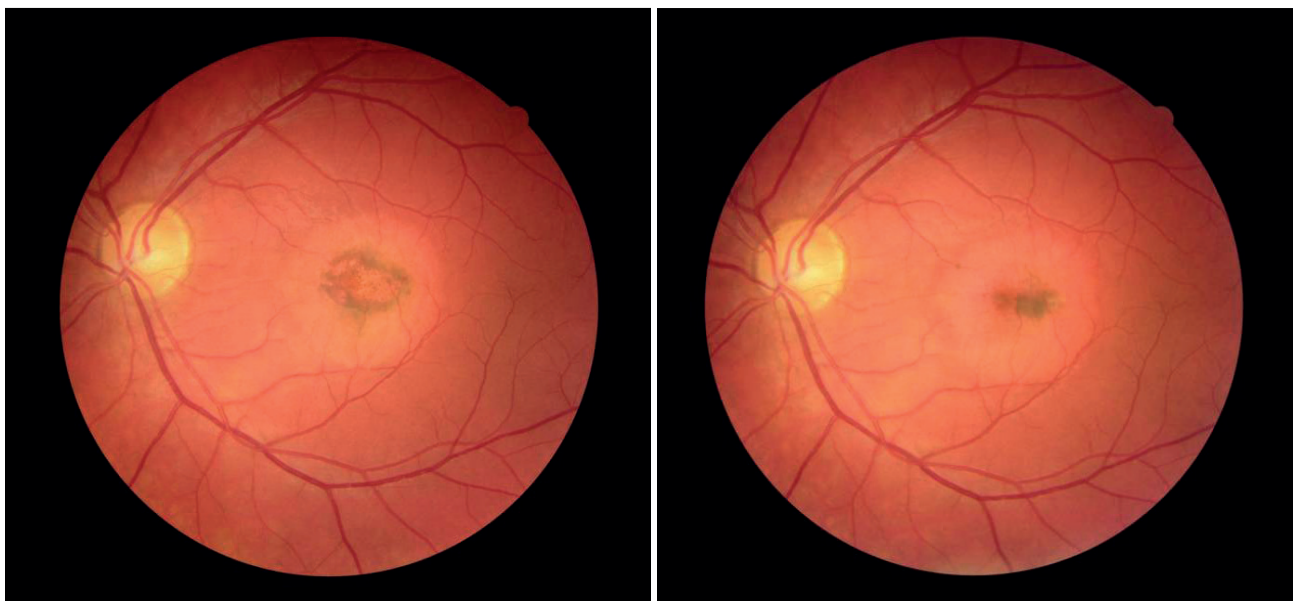
on of the layer of the RPE and photoreceptors within the scope of the rounded defect. We also found a thickened choroid in the region exceeding the deposit (subfoveal thickness of the choroid was 400  $\mu\text{m}$  in the left eye, 300  $\mu\text{m}$  in the right eye), intraretinally the finding was within the norm, without edema, without breach of stratification of layers, the foveal depression was not breached (Fig. 9). On FAG there was evident early and progressively increasing mottled hyperfluorescence, which corresponded in terms of scope with the edge of the lesion (Fig. 8 A,B). The condition imitated pachychoroid disease of the retina, most of all chronic CSC in the stage of remission, thus without collection of fluid beneath the SE.

With regard to the patient's anamnesis of febrile exanthema, we also expressed suspicion of chorioretinitis upon a background of "hand, foot and mouth" disease, caused by the coxsackievirus. Therapy was applied of nepafenac drops 1 mg/ml (Nevanac) 3xd, aescin (Escinum alfa) tablets 3xd and prednisone tablets 1 mg/kg with progressive reduction of the doses and overall dosage period of 14 days. Upon the advice of a rheumatologist, the patient discontinued treatment with adalimumab (Humira), and was applied nimesulide 100 mg tablets 3x daily.

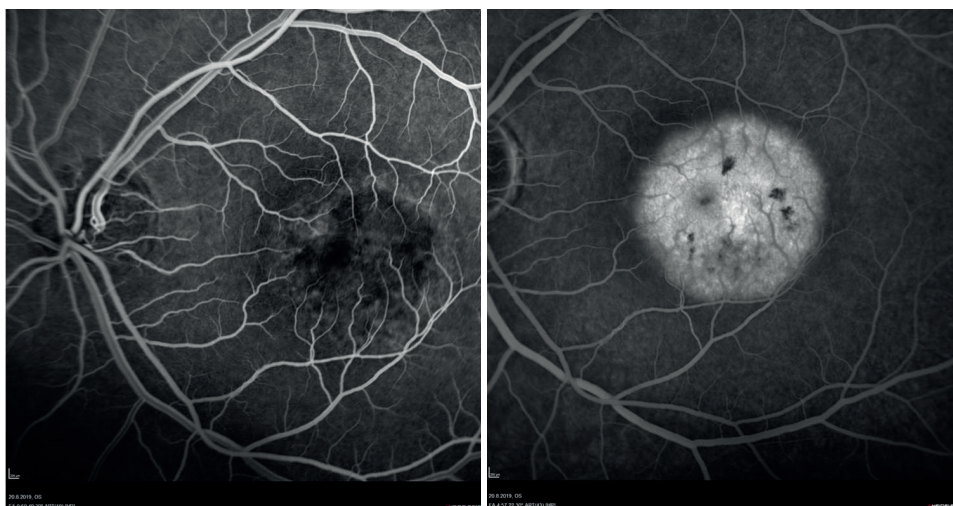
Within the course of two months, a progressive improvement of the finding was achieved, vision gradually returned to 1.0 naturally. However, the patient still states lower contrast sensitivity and change of colour perception in the left eye. On the ocular fundus of the left eye there was evident migration of pigment to the centre of the lesion, with a surrounding paler halo (Fig. 7 A, B). On the OCT image there was evident progressive reconstruction in the macular region, the progression of an increasing amount of hyperreflexive ablation of the RPE, progressive renewal of hyperreflexivity of the outer layers of the retina, and thinning of the choroid to 300  $\mu\text{m}$  subfoveally (Fig. 9, 10 A, B). Control



**Fig. 6.** Image of ocular fundus of left eye of patient with chorioretinitis



**Fig. 7.** Image of ocular fundus of left eye of patient with chorioretinitis (A), migration of pigment centrally (B)



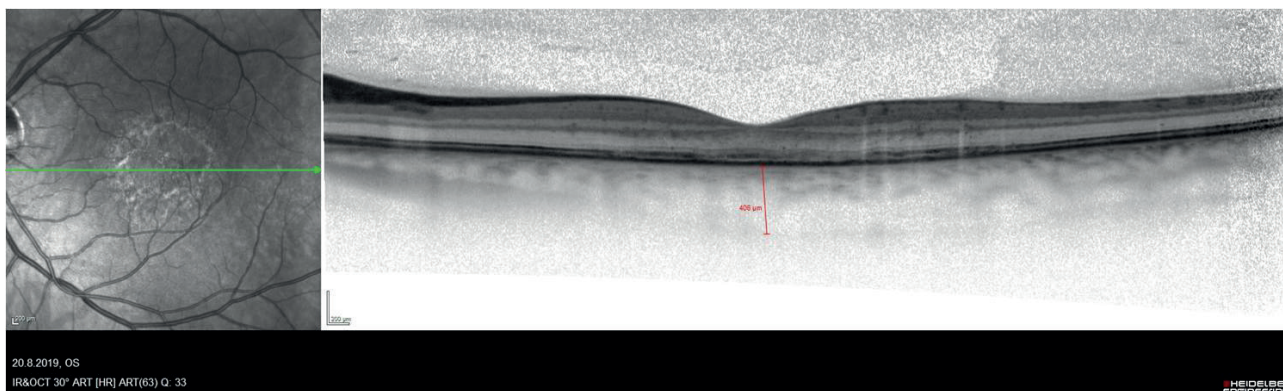
**Fig. 8.** Early (A) and later phase (B) of fluorescence angiography of patient with chorioretinitis

serology 1 month after the first examination demonstrated a reduction of IgM and an increase of IgG antibodies against coxsackivirus, which confirmed acute infection with this virus at the time of onset of the initial complaints.

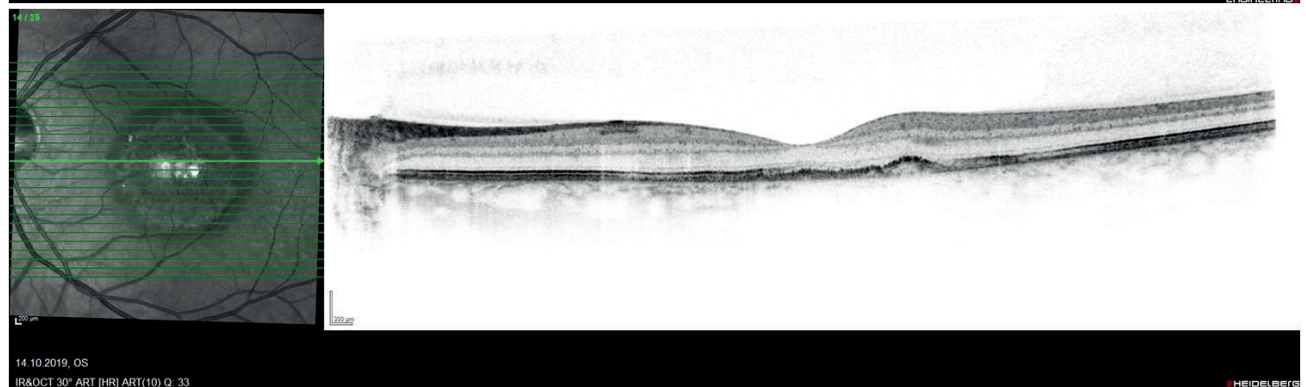
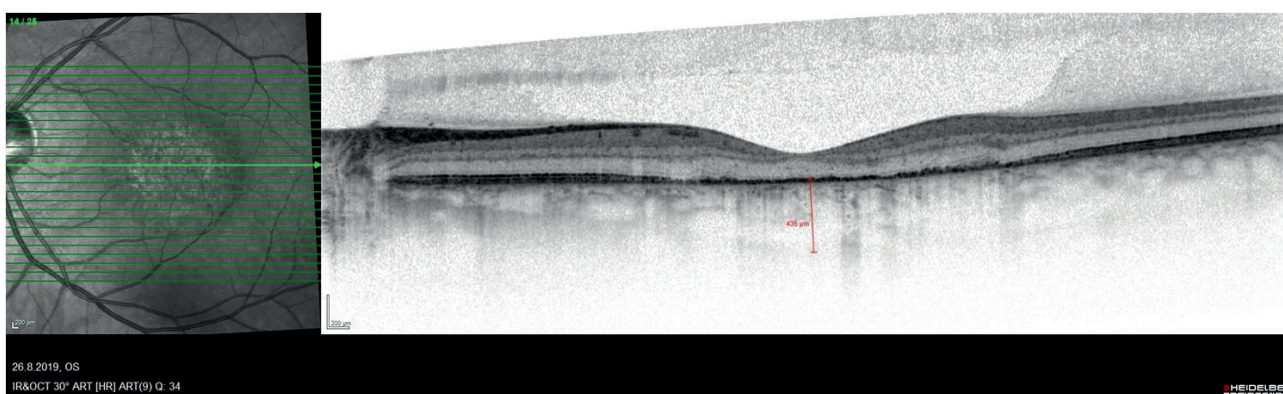
## DISCUSSION

The coxsackievirus is a highly infectious virus from the group of enteroviruses, causing “hand, foot and mouth disease”, which is manifested in fever and maculopapular to papulous exanthema on the palms of the hands, soles of the feet and oral mucosa, persisting for a number of days. It is generally accompanied with laryngitis, which may be mistaken for bacterial (most often streptococcal) sore throat, and may also be mistakenly treated with the aid of antibiotics. No direct therapy exists, and the illness often spontaneously subsides within a few days. In rarer

cases, infection with this virus may cause encephalitis, meningitis, pneumonia and myocarditis [13]. The described ocular afflictions include keratoconjunctivitis and uveitis. One of the rare manifestations may be panuveitis [13-17], manifested in vitritis and central chorioretinitis (unilateral acute idiopathic maculopathy – UAIM). Changes to the outer layers of the retina and thickening of the choroid may cause the condition to be mistaken for a pachychoroid disease of the retina, especially for chronic CSC without the presence of fluid, with the result that the doctor may choose therapy with the aid of an aldosterone antagonist, laser or PDT. However, the diagnosis of a pachychoroid disease is contradicted by the speed of onset, the presence of minor haemorrhages and the asymmetry of choroidal thickness between both eyes. By contrast, in UAIM there is often presence of subretinal fluid and normal intraretinal configuration of the retina, which may make it difficult to



**Fig. 9.** Optical coherence tomography image of patient with chorioretinitis, with reduction of reflexivity of layer of retinal pigment epithelium and thickening of choroid



**Fig. 10.** Progressive development of finding on optical coherence tomography image in patient with chorioretinitis, restoration of reflexivity of retinal pigment epithelium (RPE) (A), migration of RPE cells centrally (B)

differentiate from CSC. It is important to record a careful anamnesis, not only of chronic conditions for which the patient is being treated, but also acute illnesses.

### CASE REPORT 3

A 46 year old man had perceived deterioration of vision in his left eye, persisting for approximately one year. He had been diagnosed with CSC, and treated by a conservative method at a private facility. After 4 months of treatment he was sent to our centre for a more detailed examination. Subjectively his visual image was blurred, and he perceived a central scotoma, described slightly

positive Amsler grid test, BCVA was 0.1, vision in the right eye with similar correction 1.0, IOP within the norm. Objectively there was a normal finding on the anterior segment, on the retina there was evident granulation of pigment and hard exudates in the inferonasal part of the retina, the other finding on the retina and in the retinal vessels was within the norm (Fig. 11).

On the OCT image there was evident ablation of the SE, and focal and minor ablation of the RPE, changes in the outer layers of the retina (interdigital zone, ellipsoid zone and RPE), also hyperreflexive intraretinal spots, which corresponded with a finding of hard exudates. A foveal depression was formed, but changes in the outer retinal layers also

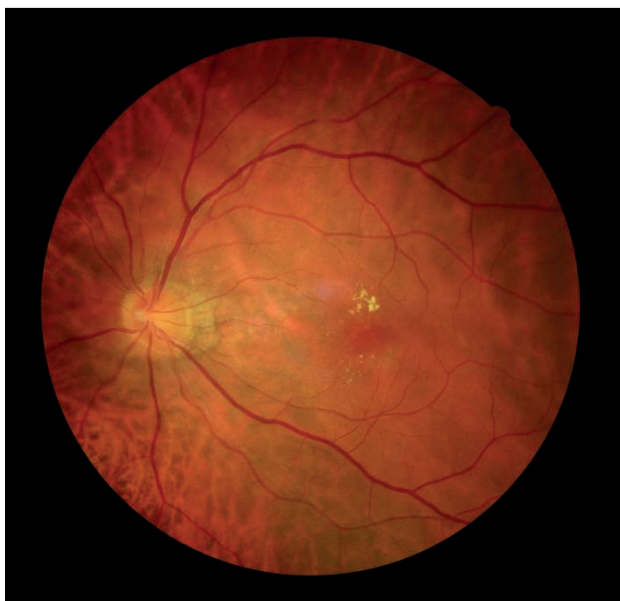reached this point, which would explain the deterioration of the patient's vision (Fig. 13). There were also evident retinal and choroidal folds, with maximum in the lower nasal quadrant of the macula and beneath the optic nerve papilla. On an autofluorescent image, hyperautofluorescence could be seen in the lower part of the macula, where there was also the largest amount of changes in the outer segments of the retina, also hypoautofluorescence corresponding to hard exudates. On a FAG image there was evident early and progressing hyperfluorescence in the region of the defects of the outer retinal layers, and by chance we also detected a chorioretinal aneurysm in the lower part of the macula (Fig. 12). On an OCT image, and especially in its EDI mode [18], there was also evident focal spreading of the choroid, spe-

cifically one of its vessels leading vertically and crossing the papillomacular bundle. In the inferonasal part of the macula, the choriocapillaris layer between the dilated vessel and outer RPE was markedly thinned, and in this location there was also the largest number of changes in the outer segments of the retina and the greatest accumulation of subretinal fluid. ICG angiography was performed, which excluded the presence of neovascularisation and confirmed the presence of a choroidal macrovessel [19], which was very probably the cause of the chronic changes on the retina (Fig. 12). The choroidal macrovessel was distinguished by early hyperfluorescence, increasing over time, but without infiltration in the late phases.

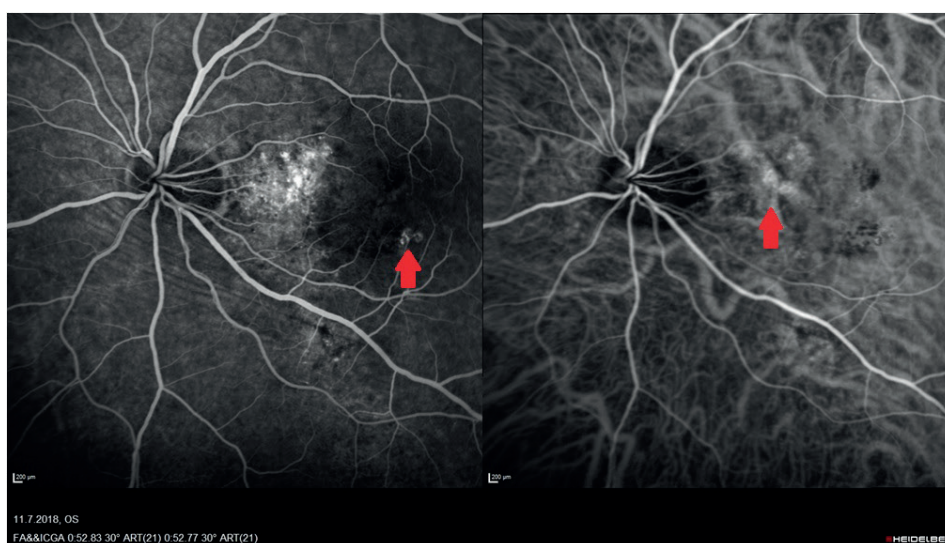
The patient was indicated for reduced PDT and focal laser treatment of a chorioretinal aneurysm. PDT was performed with 2.5 mg verteporfin (Visudyne), light wavelength 589 nm, length of exposure 83 seconds, size of beam 2830  $\mu\text{m}$ . Focal laser of the aneurysm was performed on a yellow laser (Quantel Medical) with a wavelength of 577 nm, size of beam 150  $\mu\text{m}$ , time 0.03 seconds, energy 210 mW. After the procedure, nepafenac drops (Nevanac) 1 mg 3xd were prescribed. After one month a complete absorption of the sub- and intraretinal fluid had taken place. The diameter of the dilated choroidal vessel in one of the images was 227  $\mu\text{m}$ , and one year after PDT this had been reduced to 165  $\mu\text{m}$  in the same location (Fig. 13). The patient's vision improved to 0.2. Subjectively the patient perceives a slight improvement, but due to the chronicity of the pathology and the condition of the outer parts of the retina, further functional changes cannot be expected.

In differential diagnostics it is necessary to consider choroidal hemangioma, subretinally embedded parasite [20], chorioretinal anastomosis, anomalous posterior ciliary vessels and inflammatory chorioretinal processes.

Chorioidal hemangioma is characterised by early hyperfluorescence with late infiltration on ICGA [8]. At the same time, the patient did not manifest signs of Sturge-



**Fig. 11.** Image of ocular fundus of left eye of patient with chorioidal macrovessel



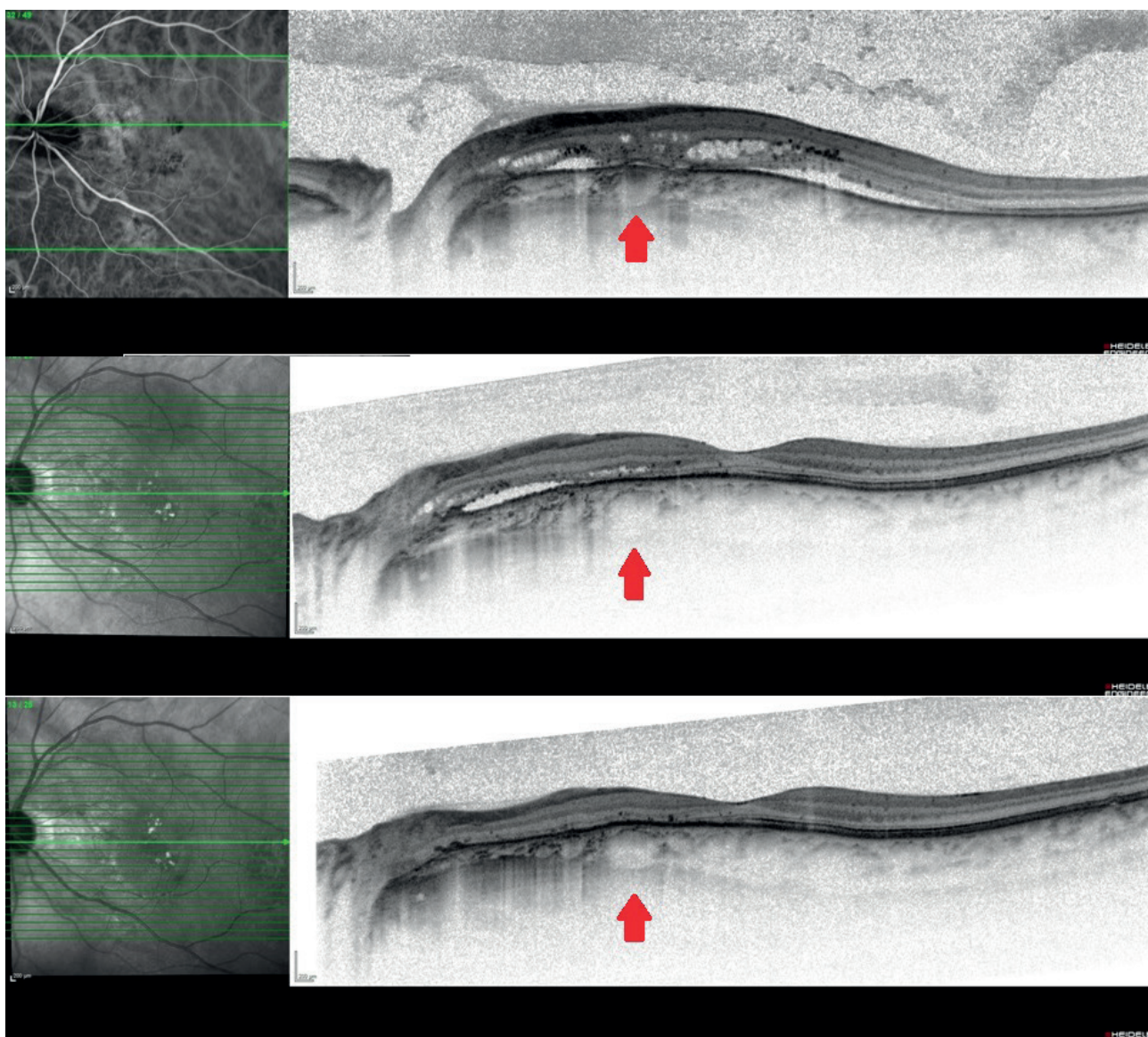
**Fig. 12.** Left – image of fluorescence angiography – evident chorioretinal anastomosis, right – image of indocyanine green angiography – evident macrovessel in papillomacular bundle

-Weber syndrome. In our case, infiltration did not appear even in the later phases. Chorioretinal anastomosis was present, though as a random finding, in a different location from that of the macrovessel. The patient's negative history of travel in exotic regions excludes the possibility of an ocular parasite. The macrovessel was saturated in the arterial phase, and as a result a diagnosis of vortex vein varix appears to be improbable. Furthermore, this condition never appears in the macular region.

## DISCUSSION

A choroidal macrovessel was first described by Lima et al [19] as an anomalous choroidal vessel with normal fluorescence on ICGA in the early phase, and progressive hypofluorescence without infiltration in the later phase. They are localised in the inner layers of the choroid, more often tem-

porally from the fovea, and no intraretinal change has been observed in the retina lying above this macrovessel. In another case, Ehlers et al. [21] described a case of a macrovessel with intraretinal changes (hyperpigmentation of RPE, subretinal fluid). In both cases the patients were asymptomatic. In our case, we describe pronounced intraretinal changes, including diffuse epitheliopathy of the RPE and outer parts of the retina, very probably caused by the influence of pressure of the macrovessel on the choriocapillaris layer. With the use of modern methods (OCT-EDI), it is possible not only to determine that the patient's choroid is thickened, but also to display in detail e.g. thinning of the choriocapillaris and pathologically dilated vessels of the deeper layers of the choroid, as was the case in our patient. Only a few cases of a choroidal macrovessel have been described, and it is necessary to consider this condition in differential diagnostics of pachychoroid diseases of the retina. In this case, correct



**Fig. 13.** Development of finding on optical coherence tomography image – before and after photodynamic therapy, evident constriction of macrovessel and decrease of ablation of sensory epithelium



diagnosis led to successful treatment.

## CONCLUSION

In regular practice, we encounter a whole range of pathologies which mimic pachychoroid diseases of

the retina. Upon a finding of thickening of the choroid, it is necessary to use all the available modern examination methods in order to obtain the most detailed possible diagnosis of these conditions. Only in this manner is it possible to configure the correct treatment for the patient.

## LITERATURE

1. Stepanov A, Studnička J, Středová M, Jirásková N. Pachychoroid disease of the macula. *Cesk Slov Oftalmol*. 2018 Spring;74(1):3-8. DOI: 10.31348/2018/1/1-1-2018
2. Shields CL, Honavar SG, Shields JA, Cater J, Demirci H. Circumscribed choroidal hemangioma: Clinical manifestations and factors predictive of visual outcome in 200 consecutive cases. *Ophthalmology*. 2001;108:2237–2248.
3. Shields JA, Stephens RF, Eagle RC Jr, Shields CL, De Potter P. Progressive enlargement of a circumscribed choroidal hemangioma. A clinicopathologic correlation. *Arch Ophthalmol*. 1992 Sep;110(9):1276–1278.
4. Shields JA, Rodrigues MM, Sarin LK, Tasman WS, Annesley WH Jr. Lipofuscin pigment over benign and malignant choroidal tumors. *Trans Sect Ophthalmol Am Acad Ophthalmol Otolaryngol*. 1976 Sep-Oct;81(5):871-881.
5. Witschel H, Font RL. Hemangioma of the choroid. A clinicopathologic study of 71 cases and a review of the literature. *Surv Ophthalmol*. 1976;20:415–431.
6. Arevalo JF, Shields CL, Shields JA, Hykin PG, De Potter P. Circumscribed choroidal hemangioma: characteristic features with indocyanine green videoangiography. *Ophthalmology*. 2000 Feb;107(2):344–350.
7. Shields CL, Shields JA, De Potter P. Patterns of indocyanine green videoangiography of choroidal tumours. *Br J Ophthalmol*. 1995 Mar;79(3):237–245.
8. Schalenbourg A, Piguat B, Zografos L. Indocyanine green angiographic findings in choroidal hemangiomas: A study of 75 cases. *Ophthalmologica*. 2000;214(4):246–252.
9. Long RS. Problems of diagnosis and treating choroidal hemangiomas. *Ophthalmol Times*. 1981;6:144.
10. Torres VL, Brugnoli N, Kaiser PK, Singh AD. Optical coherence tomography enhanced depth imaging of choroidal tumors. *Am J Ophthalmol*. 2011 Apr; 151(4):586–593.e2.
11. Porrini G, Giovannini A, Amato G, Ioni A, Pantanetti M. Photodynamic therapy of circumscribed choroidal hemangioma. *Ophthalmology*. 2003 Apr;110(4):674–680.
12. Jurklics B, Bornfeld N. The role of photodynamic therapy in the treatment of symptomatic choroidal hemangioma. *Graefes Arch Clin Exp Ophthalmol*. 2005 May; 243(5):393–396.
13. Kadrmas EF, Buzney SM. Coxsackievirus B4 as a cause of adult chorioretinitis. *Am J Ophthalmol*. 1999;127(3):347–349.
14. Takeuchi M, Sakai J, Usui M. Coxsackievirus B4 associated uveoretinitis in an adult. *Br J Ophthalmol*. 2003;87(4):501–502.
15. Forster W, Bialasiewicz AA, Busse H. Coxsackievirus B3-associated panuveitis. *Br J Ophthalmol*. 1993;77(3):182–183.
16. Haamann P, Kessel L, Larsen M. Monofocal outer retinitis associated with hand, foot, and mouth disease caused by coxsackievirus. *Am J Ophthalmol*. 2000;129(4):552–553.
17. Alexander JP Jr, Chapman LE, Pallansch MA, Stephenson WT, Török TJ, Anderson LJ. Coxsackievirus B2 infection and aseptic meningitis: a focal outbreak among members of a high school football team. *J Infect Dis*. 1993 May;167(5):1201–1205.
18. Choudhry N, Rao RC. Enhanced depth imaging features of a choroidal macrovessel. *Retin Cases Brief Rep*. 2016 Winter;10(1):18-21.
19. Lima LH, Laud K, Chang LK, Yannuzzi LA. Choroidal macrovessel. *Br J Ophthalmol*. 2011 Sep;95(9):1333–1334.
20. Ahmed E, Houston MA, Husain D. High-definition spectral domain OCT of a subretinal nematode. *Eye (Lond)*. 2010 Feb;24(2):393–394.
21. Ehlers JP, Rayess H, Spaide RF. Isolated choroidal macrovessel: a tracklike choroidal lesion. *Can J Ophthalmol*. 2014 Dec;49(6):e158–e160.