

# NANOLASER IN CATARACT SURGERY AND ITS INFLUENCE ON THE CORNEAL ENDOTHELIUM

## SUMMARY:

### NANOLASER IN CATARACT SURGERY AND ITS INFLUENCE ON THE CORNEAL ENDOTELIUM

**Aim:** To compare the safety and efficacy of a new nanolaser photofragmentation technique of cataract surgery with ultrasound phacoemulsification.

**Method:** A cohort of 20 patients underwent ultrasound phacoemulsification in one eye (group I) and nanosecond laser fragmentation in the other eye (group II). All cataracts were classified as stage 3 of cataract progression, i.e. nuclear opalescence (NO) was NO2-NO3 according to the used Lens Opacities Classification System III.

We observed uncorrected visual acuity (UCVA expressed in decimal units) before and after surgery, as well as corneal endothelial cell density (ECD), the percentage of hexagonal cells and the pleomorphism index (PI) and corneal thickness (CT) before surgery and 7 days after surgery.

**Results:** In all 40 eyes the course of surgery was uncomplicated. BCVA was  $0.70 \pm 0.10$  in group I before surgery, in group II  $0.68 \pm 0.10$ , and 7 days after surgery in group I  $0.98 \pm 0.05$  and in group II  $0.98 \pm 0.04$  (p-NS).

Average ECD (cells/mm<sup>2</sup>) before surgery in group I was  $2508 \pm 205.54$  bb/mm<sup>2</sup> and in group II  $2472.5 \pm 287.78$  bb/mm<sup>2</sup>. After surgery in group I this was  $2024.92 \pm 271.50$  bb/mm<sup>2</sup> and in group II  $2138.50 \pm 390.85$  bb/mm<sup>2</sup>. The differences in the loss of endothelial cells between both groups were statistically insignificant.

In a comparison of the difference of both groups upon average incidence of hexagonal cells before and after surgery, the differences were statistically insignificant, as they were upon a comparison of the differences of corneal thickness. In all the observed parameters we therefore did not record any statistically significant differences.

**Conclusion:** Nanolaser lens photofragmentation and ultrasound phacoemulsification can be considered of equal value from the perspective of a comparison of both methods on perioperative influence on the corneal epithelium.

**Key words:** cataract surgery, ultrasound phacoemulsification, nanolaser lens photofragmentation, endothelial cells

Čes. a slov. Oftal., 75, 2019, No.5, p. 268-271

## INTRODUCTION

Cataract surgery is one of the most frequently performed operations worldwide. The method and techniques of the operation have undergone intensive development up to today's standard stage of ultrasound phacoemulsification and implantation of various types of intraocular lenses.

Despite the sophisticated phacoemulsification technique, there is still an endeavour to improve the process. For example, to minimise the surgical trauma, improve perioperative intraocular stability, perfect intraocular lenses and so on.

The adverse effect of ultrasound on the ocular structures and its contribution to the onset of endothelopathy and cystoid macular edema is well known.

Juhás T., Juhás T. ml.

OFTUM Eye Clinic, Košice, Head: prof. MUDr. Tomáš Juhás, DrSc.

*The authors of the study declare that no conflict of interest exists in the compilation, theme and subsequent publication of this professional communication, and that it is not supported by any pharmaceuticals company.*



prof. MUDr. Tomáš Juhás, DrSc.  
Očná klinika OFTUM  
Moldavská 21/A, 040 11 Košice  
juhastomas@yahoo.com

Received: 18. 3. 2019

Accepted: 30. 10. 2019

Available on-line: 17. 2. 2020

The cause of these complications is not only the time, intensity of ultrasonic energy, mechanical and thermal damage upon phacoemulsification, but also the state of the cornea, hardness of the lens nucleus, axial length, traumatization of the eye, experience of the surgeon and quality of the used material, such as viscomaterial.

This study compares the density of endothelial cells, their morphology and corneal thickness before and after surgery in two groups of operated-on eyes: in group I following ultrasound phacoemulsification and group II following nanolaser lens photofragmentation.

The use of laser energy for phacolysis of the human lens has been known for almost 30 years. Neodymium: YAG laser was first experimentally used in 1990 by Dodick (5). The technique was perfected up to the development of the commercially available nanosecond Cetus laser (Fig. 1).

## MATERIAL AND METHODS

We began to perform cataract surgery with a nanolaser instrument at the beginning of 2018. Our cohort comprised 40 eyes of 20 patients aged between 55 and 70 years, featuring 9 women and 11 men. Cataract surgery was performed at the Oftum Eye Clinic in Košice, and all the operations were performed by a single surgeon (T.J. sr.). The cohort included patients with nuclear cataract up to the 3rd degree. The nuclear opalescence (NO) of the lens was assessed according to the established Lens Opacities Classification System III. A further condition was a number of endothelial cells larger than 1200 cells/mm<sup>2</sup>.

Excluded from the cohort were patients with a pathologically altered anterior segment of the eye, such as corneal opacities, keratoconus, symptoms of uveitis, pseudoexfoliation syndrome, zonular dialysis, glaucoma and diabetes.




Fig. 1. Nanolaser Cetus ARC Laser GmbH, Erlangen, Germany

The cohort was divided into 2 groups. In group I the eyes were operated on by ultrasound phacoemulsification in the right eye and in group II the contralateral eyes were operated on by nanolaser lens photofragmentation in the left eye.

Before surgery all the patients underwent an ophthalmological examination covering examination of visual acuity, examination by a slit lamp, applanation tonometry and fundus ophthalmoscopy. In addition, a specular microscope (Nidek CEM 530 Specular microscope, Japan) was used to examine endothelial cell density, corneal thickness and the percentage of hexagonal cells or the pleomorphism index.

## SURGICAL TECHNIQUE

We performed cataract surgery using the nanolaser system Cetus, ARC Laser GmbH Germany (Fig. 1). The pulsing laser energy in this laser is conducted from the source via an optical fibre. Laser energy is usually 5 mJ with a time interval of 5ns. The optical fibre ends in the aspiration opening of the probe in a titanium disc, the aspiration and irrigation system is connected via the vitrectomy module of the Centurion (Alcon) phacoinstrument and ends in the same probe fitted with an irrigation silicone sleeve (Fig. 2) and (Fig. 3).

Fragmentation of lens matter takes place by means of laser pulses which form plasma and blast the lens matter. The laser probe has a diameter of 2.4 mm.

The Centurion phacoemulsification instrument was used for phacoemulsification. In both cases the traditional “clear cornea cataract surgery” technique was used, therefore with a corneal incision, viscomaterial into the anterior chamber, capsulorhexis, hydrodissection, hydrodelineation and fragmentation of the lens matter with the aid of irrigation and aspiration.

In group I, 40% energy was used, with vacuum 350 mm/Hg and aspiration flow 40 cc/min. In group II, 5 mJ energy was used, with vacuum 350 mmPHg and aspiration 40 cc/min.

All patients were implanted with an identical monofocal hydrophobic IOL (iMedical Ophthalmic International Heidelberg GmbH, Mannheim, Germany).

All three parameters of early influence on the cornea by means of cataract surgery were measured before surgery and 7 days after surgery.

A statistical analysis was conducted with the use of SPSS software, accompanied by a paired T-test and Wilcoxon test.

## RESULTS

The cohort contained 20 patients, of whom 9 were women and 11 men. The average age was  $65 \pm 5.96$  years.

Before surgery, uncorrected visual acuity (UCVA) in group I was  $0.70 \pm 0.07$ , in group II  $0.68 \pm 0.10$ . After surgery, BCVA in group I was  $0.98 \pm 0.05$  and in group II



Fig. 2. Detail of end of nanosecond laser

$0.98 \pm 0.04$ . There was no statistically significant difference between the individual groups ( $p = 0.65$ ).

Average ECD before surgery in group I was  $2508.50 \pm 205.54$  bb/mm<sup>2</sup> and in group II  $2472.50 \pm 287.78$  bb/mm<sup>2</sup>. In the same order these values 7 days after surgery were  $2024.92 \pm 271.50$  bb/mm<sup>2</sup> and  $2138.50 \pm 390.85$  bb/mm<sup>2</sup>. In both groups the differences in the numbers of bb/mm<sup>2</sup> before and after surgery were statistically significant ( $p \geq 0.01$ ). However, the difference between group I and group II was statistically insignificant.

Average corneal thickness before surgery in group I was  $562.75 \pm 22.07$   $\mu\text{m}$  and in group II  $568 \pm 31.14$   $\mu\text{m}$ . Corneal thickness 7 days after surgery in group I was  $580.42 \pm 28.53$   $\mu\text{m}$  and in group II  $591.58 \pm 36.38$   $\mu\text{m}$ . Changes in the individual groups were statistically significant ( $p=0.01$ ), but the differences between both groups were not statistically significant ( $p$ -NS).

The average percentage of hexagonal cells before surgery in group I was  $71.25 \pm 3.79\%$ , in group II  $69.75 \pm 4.35$  in group II. One week after surgery the values were in group I  $68.50 \pm 4.52\%$  and in group II  $68.42 \pm 5.66\%$ . The changes in the individual groups were statistically insignificant, as were the differences between groups I and II ( $p$ -NS).

## DISCUSSION

The essence of this comparative study of contralateral eyes was to compare the phacoemulsification technique of cataract surgery with the nanolaser technique, upon use of the same flow system of the same phacoemulsification instrument (Centurion, Alcon) and its influence on the cornea in the early postoperative period. Both groups had approximately the same stage of lens opacification.

After 7 days, both groups had very similar results of improvement of UCVA, which attests to rapid rehabilitation of vision in both techniques. Similar results are also stated in the literary sources (1, 2, 3, 6).

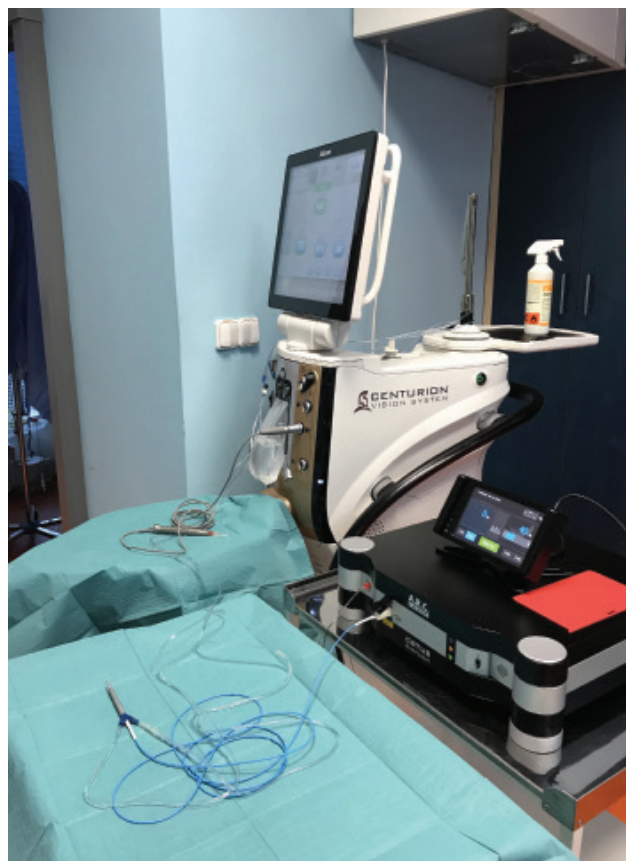

Fig. 3. View of connection of both instruments

At present, each cataract surgery may lead to corneal damage in the sense of a reduction and change of morphology of endothelial cells (7, 8, 12).

A loss of the number of endothelial cells following an intraocular procedure is virtually inexorable, and this is closely linked also to postoperative corneal edema. Change of the hexagonal shape of the endothelial cells is a more sensitive indicator than ECD, and its effect is manifested after a longer time (3).

Upon a comparison of our 2 groups, no statistically significant differences were recorded between the observed parameters, which attests to the efficacy of both methods.

Changes within the framework of the individual groups observed following surgery however attest to the fact that minimal impacts occur, involving negative consequences following intraocular manipulation in the anterior chamber of the eye, even despite the of both procedures.

The process of rehabilitation of the endothelial cells is specific. Undamaged endothelial cells fill in free areas so as to renew their normal function. The healing process takes place over a period substantially longer than 7 days, and continual loss of these cells continues for as long as several years following the implantation of an intraocular lens (4, 11). Kanellopoulos and Asmelilis compared normalisation of corneal thickness following cataract surgery after 3 months (10). In our

observation, after surgery corneal thickness in group I was increased by  $18.7 \pm 6.46 \mu\text{m}$  and in group II by  $22.1 \pm 5.24 \mu\text{m}$ , which can be considered an expected change following cataract surgery by both techniques. Upon a comparison of all three observed indicators, the differences between them were statistically insignificant.

## CONCLUSION

In conclusion it is possible to state that nanolaser

in cataract surgery is a safe and effective alternative to phacoemulsification with the aid of ultrasound. It is minimally invasive, with comparable renewal of the function of the corneal endothelium.

It is necessary to emphasise that in principle laser fragmentation is different from ultrasound phacofragmentation, and the harder the nucleus of the opacified lens, the longer and more demanding the process. Further and more extensive studies should designate the indication spectrum of nanolaser technique in cataract surgery.

## LITERATURE

1. **Baradaran-Rafii A., Rahmati-Kamel M., Eslani-M. et al.:** Effect of hydrodynamic parameters on corneal endothelial cell loss after phacoemulsification. *J Cataract Refract Surg*, 35; 2009: 732-737.
2. **Conrad-Hengerer I., Al Jubury M., Schultz T. et al.:** Corneal endothelial cell loss and corneal thickness in conventional compared with femtosecond laser-assisted cataract surgery: three-month follow. *J Cataract Refract Surg*, 39; 2013: 1307-1313.
3. **DeBry, P., Olson, R.J., Crandall, A.S.:** Comparison of energy required for phaco-chop and divide and conquer phacoemulsification. *J Cataract Refract Surg*, 24; 1998: 689-692.
4. **Dick, H.B., Kohnen, T., Jacobi, F.K. et al.:** Long-term endothelial cell loss following phacoemulsification through a temporal clear incision. *J. Cataract Refract Surg*, 22; 1996:22:71.
5. **Dodick, J.M., Christiansen, J.:** Experimental studies on the development and propagation of shock waves created by interaction of short Nd: YAG laser pulses with a titanium target; possible implications for Nd: YAG laser phacolytic of the cataractous human lens. *J Cataract Refract Surg*, 17; 1991: 794-797.
6. **Ecsedy, M., Miháľt K., Kovács I. et al.:** Effect of femtosecond laser cataract surgery on the macula. *J Refract Surg*, 27; 2011: 717-722.
7. **Hayashi K., Hayashi H., Nakao F. et al.:** Risks factor for corneal endothelial injury during phacoemulsification, 22; 1996: 1079-1084.
8. **Hayashi K., Manabe S.I., Yoshimura K. et al.:** Corneal endothelial damage after cataract surgery in eyes with pseudoexfoliation syndrome. *J Cataract Surg*, 139; 2013: 881-887.
9. **Huetz, W.W., Eckhardt, H.B.:** Photolysis using the Dodick ARC lasersystem for cataract surgery. *J Cataract Refract Surg*, 27; 2001: 208-2012.
10. **Kanellopoulos, A.J., Dodick J.M., Brauweiler P. et al.:** Dodick photolysis for cataract surgery; early experience with the Q switched neodymium YAG laser in 100 consecutive patients. *Ophthalmology*, 106; 1999: 2197-2202.
11. **Liesegang, T.J., Bourne, W.M., Istrup, D.M.:** Short and long-term endothelial cell loss associated with cataract extraction and intraocular lens implantation. *Am J Ophthalmol*, 97; 1984: 32-39.
12. **Pirazzoli, B., D'Eliseo D., Ziosi M. et al.:** Effects of phacoemulsification time on the corneal endothelium using phacofracture and phaco chop techniques. *J Cataract Refract Surg*, 22; 1996: 967-969.