

PARS PLICATA VITRECTOMY IN PREMATURE NEWBORNS FOR RETINAL DETACHMENT AS A RESULT OF RETINOPATHY OF PREMATURITY, OUR RESULTS

Hejsek L., Kadlecová J., Dusová J.,
Macháčková M., Jirásková N.

Department of Ophthalmology, University
Hospital Hradec Králové, Chief prof.
MUDr. Naďa Jirásková, PhD., FEBO

The authors of the study declare that no conflict of interest exists in the compilation, theme and subsequent publication of this professional communication, and that it is not supported by any pharmaceuticals company.



MUDr. Libor Hejsek, PhD., FEBO
Oční klinika FN Hradec Králové
Sokolská 581
500 05 Hradec Králové

SUMMARY

Introduction: The aim of this work is to evaluate our own results of surgical treatment of retinal detachment in immature newborns. Retinopathy of prematurity (ROP) is one of the most complicated ocular disorders, both in terms of diagnosis and therapy. It is a potentially blinding illness that arises from the incomplete development of the bloodstream of the neuroretina of preterm infants. Currently, the most effective therapy is ablation of the avascular retina by laser photocoagulation or cryocoagulation. Despite this treatment, the immature retina may develop its detachment.

Methodology: We report 2 case-reports, retrospective results of 4-eyes in 2 patients with severe ocular and overall complications of prematurity. The ocular background of preterm babies was investigated in arteficial mydriasis by an indirect ophthalmoscope, and later with the RetCam photographic device. The ROP stages were evaluated according to the ICROP classification. All eyes were treated with cryo-retinopexy at the threshold stage of ROP, followed by intraocular surgery for progression of traction retinal detachment. The surgical technique was a 3-port 25-G PPV (pars-plicata vitrectomy) with insertion of ports 1.5 mm from limbus. The PPV was performed using the Constellation (ALCON) operating unit, controlling the intraocular pressure for 15 torr. The assessment of visual acuity was performed according to the scale: no light perception (no response of the child to light), light sensitivity (positive or negative reaction to illumination), fixation of light.

Results: The retina stayed attached in all operated eyes, more in each case-report.

Conclusion: Contemporary vitreoretinal surgery allows for the anatomical success of traction retinal detachment surgery during ROP already in neonatal age.

Key words: retinal detachment, retinopathy of prematurity, PPV, surgery

Čes. a slov. Oftal., 73, 2017, No. 4, p. 140–145

INTRODUCTION

Retinopathy of prematurity (ROP) ranks among the most serious ocular pathologies, both in the sense of diagnosis and in terms of therapy. In more advanced stages even the examination of the ocular fundus itself is problematic (usually due to insufficient mydriasis or complications of the patient's general condition), in which the fine details of the intraocular finding influence the correct determination of the diagnosis and the timing of any applicable treatment.

ROP is a potentially blinding pathology, which occurs upon a background of incomplete development of the bloodstream of the neuroretina of prematurely born infants (11). The pathology afflicts primarily children born before the 31st week of gestation, with a weight of 1 250 g or less. Significant risk factors are anaemia, respiratory problems and the general (lack of) progress of the patient.

Despite highly effective therapy for sight-threatening forms of ROP by laser (study ETROP 2003) (5) or cryocoagulation (study CRYO-ROP 2001) (4), we continue to encounter tractional retinal detachment (TRD) in the case of ROP. The results regarding visual functions upon TRD are generally not satisfactory (6). Recently more encouraging reports have appeared

in literature regarding good anatomical and functional results of vitrectomy, performed in the early stages of retinal detachment upon ROP (3, 9, 10).

An empirically confirmed precondition for the success of pars-plicata vitrectomy (PPV) upon retinal detachment upon ROP is the timing of the procedure before the time of expiration of neovascular activity of ROP (and regression of signs of "plus disease"). If "plus disease" persists, it is often the predictor of complications: haemorrhage, increased exudation and continuing proliferation, which induce later contraction of the neuroretina following the performance of PPV, thus potential failure of the surgical procedure (3, 7). However, in certain cases there may be very rapid progression of amotio before "plus disease" and neovascular activity have sufficiently receded. Hesitation in indication for PPV then leads to a worse prognosis of the postoperative condition. The more advanced the stage, the worse the postoperative prognosis, and the chance for re-attachment is reduced (especially upon total retinal detachment) (8).

There is also the possibility of anti-VEGF pre-treatment before the performance of PPV, the effect of which has also been the subject of a number of publications. The sense of

anti-VEGF intravitreal therapy is “preparation” before actual PPV, the purpose of which is to ensure a decrease of vascular activity of the pathology before the procedure (15).

The aim of this study is to evaluate our own results of surgical solution to retinal detachment upon ROP in premature infants and to indicate aspects and pitfalls of the treatment of this pathology.

METHOD

We present our case report results from a retrospective observation of 4 eyes in 2 patients with severe ocular and general complications upon premature birth. Throughout the entire period of intensive ocular observation, the patients were hospitalised at the Department of Paediatrics of the University Hospital in Hradec Králové. The ocular fundus of prematurely born infants was examined 1x per week in artificial mydriasis (Unitropic 1% gtt. and Neosynephrine 10% gtt.) by an indirect ophthalmoscope and during the course of the later observation period also by the photographic instrument RetCam (Clarity Medical Systeme, Pleasanton, CA). The stages of ROP were evaluated according to the ICROP classification (International Classification of Retinopathy of Prematurity) (13).

Upon reaching the threshold stage of ROP, all eyes were treated by cryo-retinopexy and observed further, and due to progression with the occurrence of tractional retinal detachment were indicated for intraocular surgery of amotio.

The surgical technique under general anaesthesia was generally the same in all cases. All the operations were performed by one surgeon (L.H.). Three-port 25-G PPV (pars plicata vitrectomy) was performed, with insertion of the ports 1.5 mm from the limbus. The position of the infusion cannula was altered during the operation with regard to the possibility of treating the entire periphery of the retina. Ringer's solution 500 ml with 5 ml 10% glucose and 0.4 ml adrenaline was used as the infusion. Vitrectomy was performed with the aid of the surgical unit Constellation (ALCON), controlling intraocular tension at 15 torr, with a cutting speed of 1000-5000 per minute. A surgical microscope ZEISS OPMI Lumera 700 (with Resight non-contact system for display of the posterior segment) was used for visualisation. The main aim of the operation was to cut out the altered vitreous body and to traverse all the tractional forces connecting pars plana and the intraocular lens and pars plana and the retina with the optic nerve. Unfortunately in the first case (case report no. 1) it was not possible to leave the patient phakic due to the burden of the finding in the remote periphery of the retina. At the same time, in this case it was necessary also to use tamponade by decalin and silicone oil. In the second case (case report no. 2) no intraocular tamponade was used. At the end of the procedure, all the surgical incisions were treated with a transconjunctival suture using absorbable suture (8-0 Vicryl). The last element of the operation was parabolbar application of a 3 ml compound of Diprophos and Gentamicin (in a ratio of 1:1).

An evaluation of visual acuity was performed by an estimate according to the scale: without light perception (no reaction of child to light), light perception (positive or negative reaction to illumination), fixation and following eye movements.

RESULTS

In this study we retrospectively evaluate two cases of our most complicated premature patients on whom it was necessary to operate due to the development of tractional retinal detachment upon ROP in the neonatal period.

Case report no. 1

This concerned a boy born in the 27th gestation week (GW), with a birth weight of 700 g. The birth was preceded by partial haemorrhagic abruption of the placenta in the 25th GW, with hypotrophisation of the foetus. After birth respiratory distress syndrome occurred, with the necessity of administering surfactant, and on the third day of life spontaneous perforation of the ileum upon a congenital developmental defect. The condition was addressed by means of two resections of the affected sections of the intestines and end-to-end anastomoses. In the first month of life it was then necessary to perform one more resection of the ileum. Only afterwards did the patient begin to tolerate enteral intake. Distension of the stomach worsened respiratory complaints, and the patient by turns required full lung ventilation. We briefly present a basic summary of the further diagnoses: short bowel syndrome with anaemia (necessity of transfusions) and hypovitaminosis, bronchopulmonary dysplasia, mild hydronephrosis, bilateral inguinal hernia and condition following respiratory failure in the 4th week of life (31st GW).

The patient tolerated full enteral intake only after the 33rd GW, in the 35th GW respiratory support with oxygen therapy was terminated.

This risk patient was observed for ROP at weekly intervals from the 31st GW. In the 36th GW we recorded 2nd degree ROP in zone 2, and this pacific state did not change until the 41st GW. In that week pronounced tortuosity of capillaries was determined in the periphery, as well as circular progression of the height of the fornix, on which there were haemorrhages and live vascular proliferation into the vitreous area. The retina was attached, tractional manifestations in the vitreous body were not evident, we evaluate the condition as stage 3 with “plus disease” and indicate the performance of cryoretinopexy. The treatment was performed immediately on the following day. During the procedure (detailed examination under general anaesthesia with indentation of the periphery of the retina) we raised suspicions of flat amotio in the upper quadrants of both eyes. Following cryoretinopexy of the retina, new respiratory complaints occurred in the patient, which again required two-day full lung ventilation. The patient was further observed at weekly intervals, manifestations of “plus disease” gradually subsided, haemorrhage and neovascularisation disappeared, the vascular element was pacified. However, in the 45th GW we confirmed retinal detachment in the right eye with lying macula (ROP in stage 4A). We estimated visual functions on the level of light perception. Behind the lens was an evident tractional rib, which communicated via a ligament bridge in the detached periphery of the retina. The finding in the left eye remained stable, here retinal detachment was only suspected (ophthalmoscopically), with a negative finding upon ultrasonic examination of the ocular fundus. With regard to the progression of the finding and

pacification of the vascular component of retinopathy, we embarked upon the performance of a surgical solution in the right eye.

Before the procedure on the RE, an examination of the fundus of the left eye was performed (under general anaesthesia) by direct ophthalmoscope: the finding was without signs of plus disease, the retina lying, vascularisation of large blood vessels practically complete, in the temporal periphery (zone 3) is suspect flat amotio, tractional manifestations were not found. At this point we did not indicate the left eye for surgery. PPV was further performed on the right eye: close behind the lens was a circular high ridge in its periphery, which was connected by ligament membranes to the posterior capsule of the lens, as a result of which pars plana lensectomy was performed, we continued in PPV, amotio was total (flat in the macula), cutting out of heavily fibrously altered vitreous body, separation of dense membranes in front of and around the papilla, where they formed a truncated cup from the detached neuroretina, separation of very firmly adhering posterior vitreous membrane down to vitreous base, peeling of multiple membranes on the posterior pole following staining with diluted Triamcinolone and blue, release of posterior pole by decalin, segmentation and delamination of very thick tractional membranes in the area of the ciliary body. Even after complete release of all the fibrous changes, the retina could not be completely reattached. Replacement by air, Miostat to PK, basal coloboma in no. VI vitrectomy, subsequent replacement by silicone tamponade (Oxane 1300, Bausch and Lomb).

In the perioperative finding there was a clear very thinly vascularised macula, the neuroretina contained practically only large blood vessels, the temporal part of the macula and the outer middle periphery was degeneratively to cystically altered, ROP in stage 5 (fig. 1).

We continued with weekly examinations – the intraocular finding in the left eye deteriorated in the 48th GW, when amotio retinae ophthalmoscopically progressed in the nasal quadrants (ROP 4A). We indicated a surgical procedure also in this eye. The following were performed: cutting out of retro-lental fibrously altered vitreous body, taut membranes were behind the posterior surface of the lens, which stretched the ridge of amotio (circularly) high in the periphery of the retina (fig. 2), as a result lensectomy was also performed by vitrectomy. Vitreous body stained with diluted triamcinolone, peeling of multiple membranes on the posterior pole, declaine for flattening of the macula. Progressive cutting out and separation of numerous membranes circularly. Relaxation radial cuts performed in ligament on the peak of the circularly deposited ridge in the periphery. Forceps used to progressively separate ligament ring, which circularly retracted the retina. Miostat into PK, basal iridectomy by vitrectomy in no. VI, replacement by air and subsequently by silicon tamponade (Oxane 1300, Bauch and Lomb).

In the postoperative period the finding on the ocular fundus gradually improved, amotio retinae decreased and residual flat detachment reliably subsided in the left eye 2.5 months and in the right eye as long as 4 months following performed PPV. Silicone tamponade did not penetrate into the anterior chamber, the cornea was transparent, intraocu-

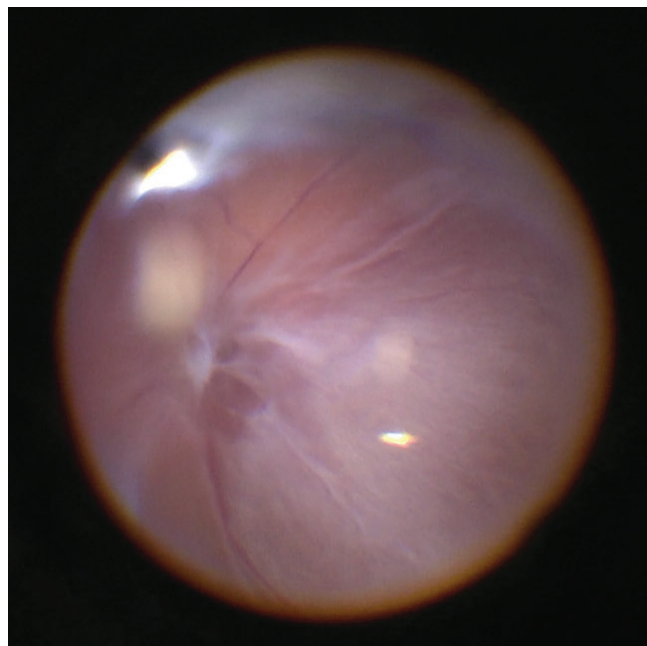


Fig. 1 Perioperative finding in RE: weak vascularisation, fibrous changes on surface of retina, in lower periphery (upper part of image), high ridge with membranes on surface

lar tension normal (measured using TonoPen instrument) and colobomas clear.

At the end of the observation period (1.5 years after birth) the child is physically vital, general condition without alteration, the somatic finding corresponds to retardation of growth (weight 6 580 g). He wears glasses correction of +15.0 in the right eye and +18.0 in the left eye, visual acuity is bilaterally on the level of reliable fixation. No nystagmoid movements are present. The anterior segment in both eyes is without complications, silicon tamponade in the vitreous area, retina lying. The papillas are paler bilaterally. Large vascular trunks are evident on the retina, otherwise the vascular image is weak, in the right eye we find perivascular pale exudations along the main vascular trunks and pronounced pigment shifts up to atrophy from the central central periphery (fig. 3). In the left eye the developmental defect of the vascular channel

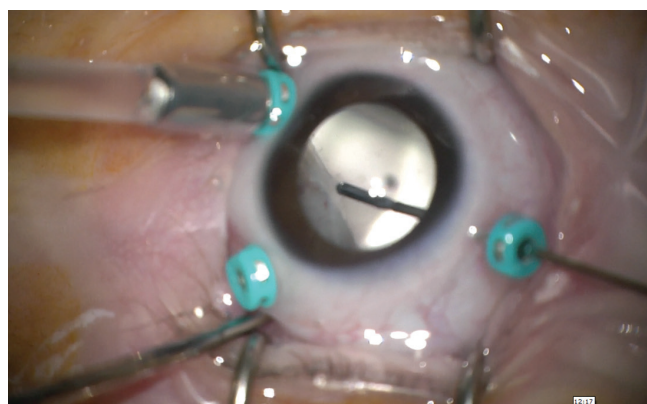


Fig. 2 Perioperative finding in LE: after performance of lensectomy, shave of fibrous membranes on surface of elevated tractional ridge in periphery

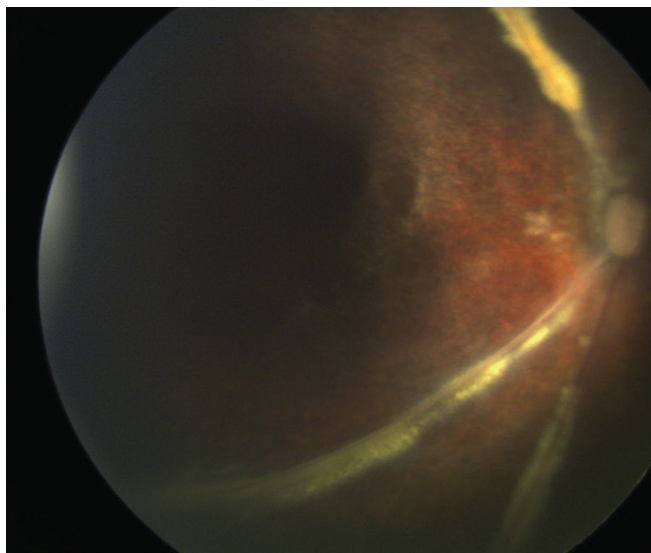


Fig. 3 Colour photo of right eye in postoperative period

is less pronounced than in the right eye, no exudations, the macula and central periphery also manifest signs of pronounced pigment shifts, externally from the centre there are atrophic changes of the RPE.

Case report no. 2

This concerns a girl (born as twin "B", together with brother - "A") in the 24th gestation week, with a birth weight of 500 g. ROP developed also in the brother, which was treated in the threshold stage bilaterally by cryo-retinopexy. In this case a regression of the finding took place following the procedure, without subsequent development of tractional amotio.

The birth of these twins was preceded by chorioamnionitis in the 24th GW. Shortly after birth respiratory distress syndrome occurred in the girl, with persistent pulmonary hypertension. 2 doses of surfactant were administered, connection to full lung ventilation and general corticotherapy for bronchopulmonary dysplasia. Lung ventilation was terminated in the 31st GW, but respiratory support with oxygen therapy was necessary up to the 39th GW. The post-natal course was further complicated by repeated infections: staphylococcus sepsis, candidiasis sepsis and subsequent pneumonia. In the 45th GW necrotising enterocolitis developed, treated by surgical revision and resection of part of the small intestine. Of other pathologies we identified: transitory hyperglycaemia with necessity of insulin therapy by pump (persisting for two months), anaemia of mixed etiology, periventricular leukomalacia with atrophy of the corpus callosum (38th GW), cytomegaloviral hepatitis.

This risk patient was observed for ROP at weekly intervals from the 29th GW. From the 31st GW we observed incipient stages – ROP 1 in zone 2. Progression of retinopathy was observed in the 33rd GW, ROP 2 to 3 in zone 2, vascularisation of large blood vessels gradually increases but the vessels began to be tortuous. In the 37th GW signs of "plus disease" became more pronounced in the right eye (here ROP 2 to 3 in zone 2) and especially in the left eye (here ROP 3 in entire temporal periphery, elevation of retina on fornix and focal haemorrh-

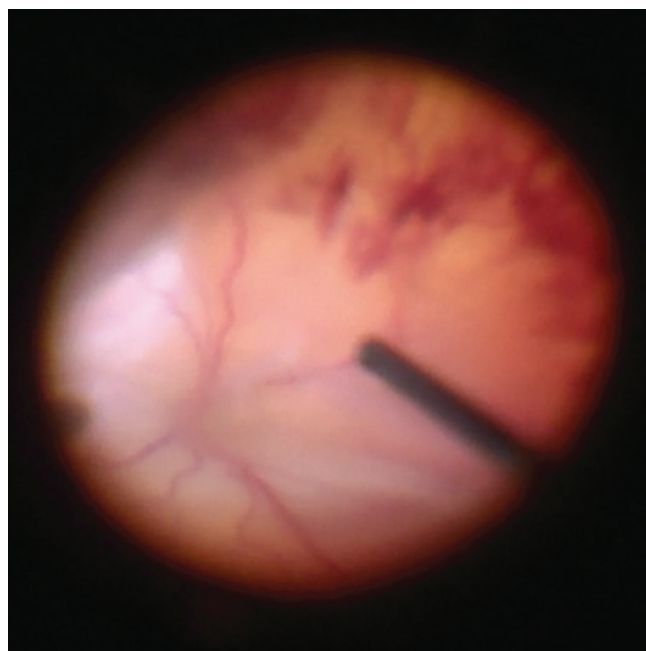


Fig. 4 Perioperative finding in RE: haemophthalmos, funnel total amotio

age in vitreous body). On the following day cryo-retinopexy was performed bilaterally, in which active neovascular proliferations were also active in the entire temporal periphery of the right eye, as well as mild haemophthalmos. During the further observation the vascular pathology subsided, neovascularisation disappeared and the prominent fornix in the periphery of both eyes was flattened. From an entirely pacific state in the periphery of the retina, at the end of the 39th GW flat amotio was observed on the fundus of the right eye (ROP 5) and in the lower periphery of the left eye (ROP 4A). Visual functions were on the level of light perception. We indicated a surgical solution on both eyes simultaneously (sequential performance of PPV).

In PPV on the RE, cutting out of the vitreous body was performed, as well as traversing of the tractional lanes in front of the retina, sparing shave of the circular membrane, which formed a ridge at the edge of the vitreous base and induced total retinal detachment (fig. 4).

In the LE first of all fine haemophthalmos was cut out, followed by traversing of multiple membranes which circularly separated the retina. Segmentation and delamination of tractional membranes in front of the papilla and in the macular landscape, release of assumed posterior vitreous membrane up to the periphery, cutting out of base of vitreous body and its shave (fig. 5).

The patient was left bilaterally phakic and without intraocular tamponade. Perioperatively we diagnosed ROP stage 5 bilaterally. After the procedure the retina was again loosely reattached, in the right eye completely lying 35 days after the procedure and as long as 45 days in the left eye.

At the final follow-up examination (at 7 months of age) the child is healthy, vital, with a weight of 3 680 g. Visual acuity is on the level of reliable fixation. No manifestations of strabismus or nystagmus are present. The finding in the anteri-

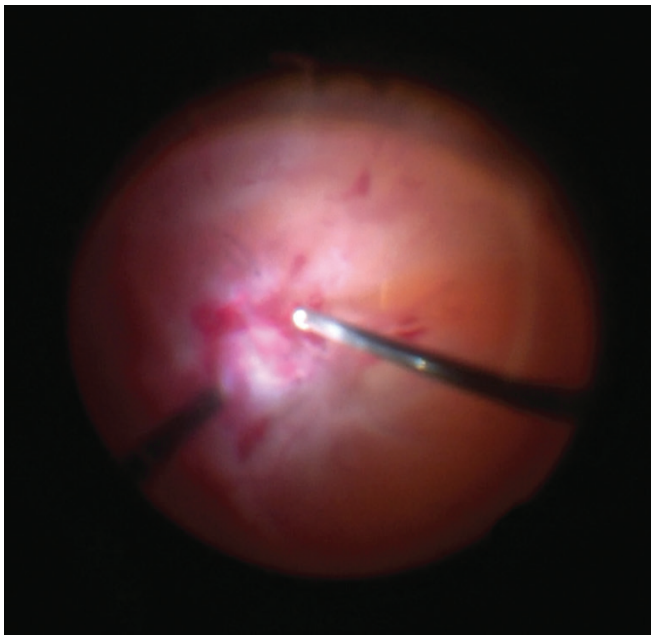


Fig. 5 Perioperative finding of RE: blood coagulation and fibrous proliferation in macula, total amotio

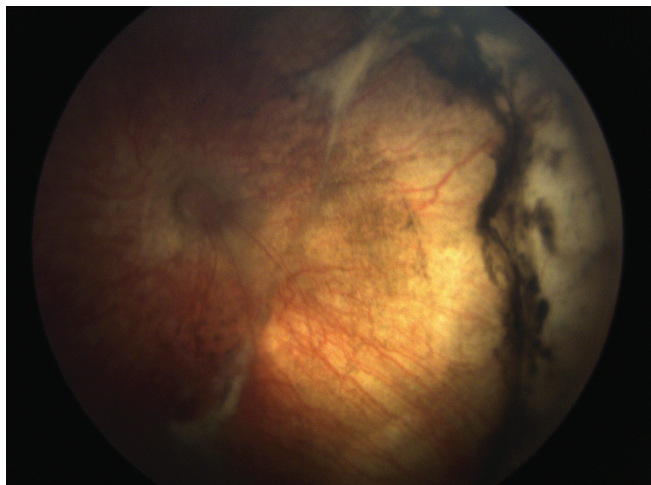


Fig. 6 Colour photo of right eye in postoperative period

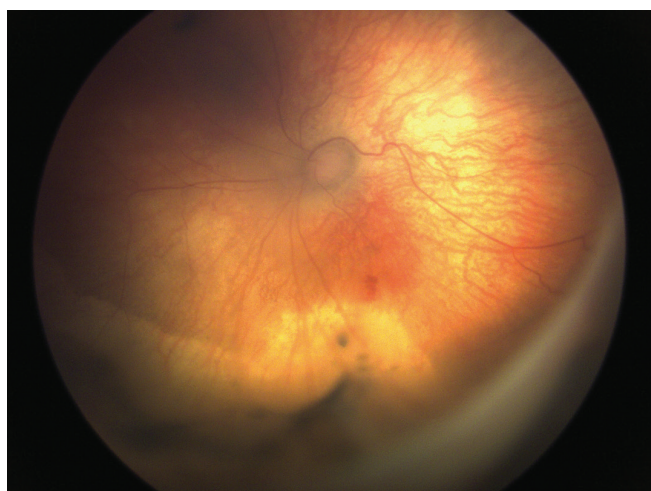


Fig. 7 Colour photo of left eye in postoperative period

or segment of both eyes is physiological, the vitreous area is clean, the retina lying. In the right eye the papilla is with a normal finding, in the left eye covered with flat gliosis. The central landscape of the left eye manifests changes of pigmentation and fibrous manifestations, the vascular network of both eyes is weak (fig. 6 and 7).

DISCUSSION

Retinopathy of prematurity is a potentially blinding pathology, especially due to the risk of tractional retinal detachment. At the same time it is also a risk factor for other potential ocular complications: severe short-sightedness, amblyopia, glaucoma etc. The most effective therapy at present is ablation of the vascular retina by laser photocoagulation or cryocoagulation (1). However, these techniques are more or less destructive for the ocular fundus. A promising treatment for certain types of ROP appears to be anti-VEGF therapy, which at present is the subject of clinical research.

If the above ROP therapy fails, amotio of the affected retina develops. From the beginning detachment usually afflicts only a part of the retina (stage 4). The basic types of amotio which may occur in ROP are as follows: serous and tractional (and a combination thereof), in exceptional cases also rhegmatogenous. Serous amotio is caused by an infiltration of fluid through abnormal vascular structures into the retina and subretinal space. The shape of such amotio is generally convex, usually amotio is behind the ridge and extends to the macula and behind the lens. Serous amotio may reattach spontaneously, even without a surgical solution. Predominantly tractional amotio is accompanied by the presence of fibrovascular tissue, which may form wrinkles or stanovitá elevations of the neuroretina. In the case of tractional detachment, the possibility of spontaneous correction of the finding is improbable. Some detachments may therefore correct themselves or at least remain stationary over time. It may then be difficult to decide and correctly time the indication for the performance of PPV, the main sense of which is to prevent the development of blindness.

Unfortunately, affliction by amotio is not exceptionally rare: in the ETROP study (5) 16% of prematurely born infants with a risk form of retinopathy had amotio in at least 1 eye. A retrospective study of monitored cases sought risk factors predisposing amotio which does not have a tendency toward spontaneous correction. These factors include: 1. persistent or recurrent "plus disease" in 2 quadrants of the eye, 2. elevation of the ridge within the scope of 6 or more continuous hours and 3. organisation of the vitreous body on the vascular interface and vascular neuroretina, or by the optic nerve, and 4. haemorrhage or fibrovascular contraction on the ridge (12).

A reliable differentiation of these details however may be difficult: this depends on the experience of the attending physician, size of the pupil, possibility of examining the patient etc. An insufficient evaluation of the finding may endanger the patient in the sense of late performance of the procedure, in which the current intraocular state may be so severe that it requires the performance of lensectomy and the use of intraocular tamponade. Such a situation occurred in our

case – Case report no. 1. Photography (for example using the RetCam instrument) and ultrasonography obtained during the procedure appear to us to be a highly beneficial display technique.

On the basis of our surgical experiences and operating results, we incline toward the recommendations of the American Academy (AAO): We recommend PPV with retention of the lens upon a diagnosis of ROP in stage 4, with the aim of averting the progression to stage 5 and preserving macular functions and the development of sight. The main aim of the operation is to release all tractional forces and thus enable the retina to reattach spontaneously without intraocular tamponade. If TOS is operated on in stage 5, we can expect success in approximately 1/3 of cases (4). Earlier performance of PPV limits the risk of contact of the fibrovascular tissue with the rear surface of the lens and the vitreous base. Such an operation is then also technically simpler (as was evident in our second case report) and enables us to leave the patient's lens in situ (15).

Potential complications of the procedure are 1. postoperative aphakia – due to very difficult visual rehabilitation and high risk of severe amblyopia and 2. iatrogenic holes of the neuroretina which induce rapid development of inoperable amotio with proliferative vitreoretinopathy and thus lead to blindness. Other known risks are: development of cataract (5-15% of cases), endophthalmitis and severe deterioration of the patient's condition of health following the procedure under general anaesthesia (12). Retention of the patient's

own lens in prematurely born infants is important, with a significant effect in averting the development of deprivation amblyopia and supporting the development of sight (14).

It is also necessary to reiterate that a surgical solution has the best results upon expired vascular activity of ROP. Persistence of activity in the sense of “plus disease” worsens the surgical results. Such PPV is linked with a risk of complicating perioperative haemorrhage, more pronounced exudative activity and continuing proliferation, which together with retraction of the subsequently formed membrane is the main cause of failure of PPV (3).

CONCLUSION

The current possibilities of eye surgery enable anatomical success of the operation of tractional retinal detachment in retinopathy of prematurity in neonatal age. According to our experiences and the literary data, the operation is technically simpler in the earlier stages of detachment. Timing of the procedure (according to the development of amotio and activity of the vascular component of retinopathy) is of key importance for its final success. An essential prerequisite for diagnosis and therapy is thorough performance of examination and the use of auxiliary display methods (photography and echography).

Thanks:

Thanks to Dr. Milan Odehnal MBA for consultation and Dr. Anna Zabanová for co-operation.

LITERATURE

1. **Autrata, R., Holousova, M., Rehurek, J.:** Cryotherapy and photocoagulation in the treatment of retinopathy of prematurity. *Cesk Slov Oftalmol.* 2002 Jan;58(1):30-5.
2. **Azuma, N., Ishikawa, K., Hama, Y. et al.:** Early vitreous surgery for aggressive posterior retinopathy of prematurity. *Am J Ophthalmol*, 142; 2006: 636–643.
3. **Capone, A. Jr., Trese, M. T.:** Lens-sparing vitreous surgery for tractional stage 4A retinopathy of prematurity retinal detachments. *Ophthalmology*, 108; 2001: 2068–2070.
4. Cryotherapy for Retinopathy of Prematurity Cooperative Group.: Multicenter trial of cryotherapy for retinopathy of prematurity: ophthalmological outcomes at 10 years. *Arch Ophthalmol.*, 119; 2001: 1110–1118.
5. Early Treatment for Retinopathy of Prematurity Cooperative Group: Revised indication for the treatment of retinopathy of prematurity: results of early treatment for ROP randomized trial. *Arch Ophthalmol*, 121; 2003: 1684–1696.
6. **Gilbert, W.S., Quinn, G.E., Dobson, V. et al.:** Partial retinal detachment at 3 months after threshold retinopathy of prematurity. Long-term structural and functional outcome. *Arch Ophthalmol*, 114; 1996: 1085–1091.
7. **Hartnett, M.E.:** Features associated with surgical outcome in patients with stages 4 and 5 retinopathy of prematurity. *Retina*, 23; 2003: 322–329.
8. **Mintz-Hittner, H.A., O'Malley, R.E., Kretzer, F.L.:** Long-term form identification vision after early, closed, lens-sectomy-vitreotomy for stage 5 retinopathy of prematurity. *Ophthalmology*, 104; 1997: 454–459.
9. **Moshfeghi, A.A., Banach, M.J., Salam, G.A. et al.:** Lens-sparing vitrectomy for progressive tractional retinal detachments associated with stage 4A retinopathy of prematurity. *Arch Ophthalmol*, 122; 2004: 1816–1818.
10. **Prenner, J.L., Capone, A., Jr., Trese, M.T.:** Visual outcomes after lens-sparing vitrectomy for stage 4A retinopathy of prematurity. *Ophthalmology*, 111; 2004: 2271–2273.
11. **Steinkuller, P.G., Du, L., Gilbert, C. et al.:** Childhood blindness. *J AAPOS*, 3; 1999: 26–32.
12. **Shulman, J.P., Hobbs, R., Hartnett, M.E.:** Retinopathy of Prematurity: Evolving Concepts in Diagnosis and Management. *FocalPoints AAO*, Vol. XXXIII, N. 7, Jul 2015.
13. The Committee for the Classification of Retinopathy of Prematurity. An international classification of retinopathy of prematurity. *Arch Ophthalmol.*, 102; 1984: 1130-4.
14. **Taylor, D., Hoyt, C.S.:** Pediatric ophthalmology and strabismus, 3rd edn. Edinburgh, Scotland: Elsevier Saunders, 2005.
15. **Yu, X., Qi, Z., Xiaoli, K. et al.:** Early vitreoretinal surgery on vascularly active stage 4 retinopathy of prematurity through the preoperative intravitreal bevacizumab injection. *Acta Ophthalmol.*, 91; 2013: 304–310.