

ORIGINAL ARTICLE

Effect of the vaginal pessaries Melanizol[®] and Klimedeks[®] on the glycogen level in the vaginal tissue of rats on the background of experimental vaginitis

Vliv vaginálních globulí Melanizol[®] a Klimedeks[®] na hladinu glykogenu ve vaginální tkáni potkanů s experimentálně vyvolanou vaginitidou

Olena V. Dolzhykova • Ludmyla M. Maloshtan • Rimma F. Yeriomenko • Volodymyr A. Maloshtan

Received: March 17, 2017 / Accepted: May 12, 2017

Summary

The experimental studies of the new vaginal pessaries Melanizol[®] and Klimedeks[®] have been carried out on the model of experimental vaginitis induced in rats by a mixture of terebenthine oil and dimethyl sulfoxide. The obtained experimental data indicate that the vaginal pessaries Melanizol[®] and Klimedeks[®] on the background of experimental vaginitis have a therapeutic effect on the 5th and 8th days of the experiment, significantly surpassing the group of animals of control pathology and placebo in its ability to restore physiological functions and accumulate glycogen by the vaginal epithelium. Melanizol[®] and Klimedeks[®] have significantly surpassed the reference drugs, the pessaries Gravagin[®] and Hippophaes oleum, but have been less efficient in the activity to the reference drug, the vaginal tablets Micogynax[®] on this criterion.

Key words: glycogen • vaginal pessaries • vaginitis • rats

Souhrn

Experimentální studie nových vaginálních globulí Melanizol[®] a Klimedeks[®] byla provedena na modelu experimentální vaginitidy u potkanů vyvolané směsí terpentýnové silice a dimethylsulfoxidu. Získaná experimentální data ukazují, že vaginální globule Melanizol[®] a Klimedeks[®] vykazovaly 5. a 8. den experimentu významně vyšší terapeutický efekt ve srovnání s kontrolní skupinou a skupinou užívající placebo v oblasti obnovení fyzi-

logických funkcí a kumulace glykogenu ve vaginální sliznici. Melanizol[®] a Klimedeks[®] překonaly v účinku referenční přípravky globule Gravagin[®] a globule s Hippophaes oleum, ale byly méně účinné ve srovnání s referenčním přípravkem vaginální tablety Micogynax[®] ve sledovaných kritériích.

Klíčová slova: glykogen • vaginální pesary • vaginitita • krysa

Introduction

Infectious vaginitis appears as a result of violation of the normal flora of the vagina, which suppresses the immune response of the host and pathogenic microorganisms entering the vagina. As a result of changes in the substrate, there is an imbalance of microorganisms in the vagina. An example of a specific type of vaginitis is the presence of a chronic fungal infection in women with impaired cellular immune response, the ingress of *Trichomonas* to the vaginal epithelium, which has an adequate supply of glycogen. The changes in opportunistic bacterial flora of the lower genital tract, which is usually dominated by *Lactobacillus* spp., is typical of “non-specific vaginitis”^{1,2}. When an inflammation of the vaginal mucosa takes place, the violation of the tissue tropism arises. At the heart of the pathogenesis of the inflammatory process there are alterations caused by the damaging action of microorganisms and their toxins. This leads to dystrophic and necrobiotic changes in cells, followed by metabolic disorders in the lesion. In chronic vaginitis there are dystrophic changes in the stratified squamous epithelium and stroma infiltration by polymorphonuclear leukocytes, lymphocytes, plasmocytes and histiocytes of the vagina. The glycogen content in the epithelium is being reduced, which is associated with impaired enzymatic processes that determine the self-cleaning, and other protective functions of the vaginal mucosa³.

Glycogen is a large branched polymer of glucose synthesized and deposited within the vaginal epithelial

Assoc. Prof. Olena Viktorivna Dolzhykova (✉) L. M. Maloshtan • R. F. Yeriomenko

Department of Physiology and Human Anatomy
National University of Pharmacy (NUPh)
12 Kulikovska str., 61000 Kharkiv, Ukraine
e-mail: dolzhikova.elena20@gmail.com

V. A. Maloshtan

Department of Anaesthesiology and Intensive Care of the Kharkiv Medical Academy of Postgraduate Education

cells during the menstrual cycle in women, at the peak of estrogen levels^{4,5}).

Lactobacilli, present in the vagina, use glycogen of the epithelial cells as an energy source and produce lactic acid during anaerobic metabolism. Microorganisms increase vaginal acidity (healthy vagina has a pH corresponding to less than 4.5) and provide protection against infection. In bacterial vaginosis the amount of lactic acid decreases and the pH (pH > 4.5) increases, which leads to the increased susceptibility to infection^{1,6}.

Vaginitis treatment must be complex. In the presence of specific pathogens, the sensitivity of the prescribed drugs to the pathogen is considered. Sanitation of secondary vaginitis without any treatment of the primary lesion will not be effective. Very often, when it is not possible to identify only one causative agent of the inflammatory process, there is a mixed infection. In such cases, in the treatment it is crucial to apply integrated local drugs³.

Taking into account the above-mentioned, the interest lies in the study of the effect of the new vaginal pessaries Melanizol^{® 7}) and Klimedeks^{® 8}) developed by the staff member of the Drug Technology Department of the National University of Pharmacy Y.V. Levachkova under the guidance of Prof. T.G. Yarnykh, on the level of glycogen in the vagina on the background of experimental vaginitis.

Experimental part

Materials

The drugs under study were the pessaries Melanizol[®] (1 pessary contains 250 mg of metronidazolium, 100 mg of tea tree oil, a mixture of PEO-1500 and PEO-400 (9 : 1)⁷), Klimedeks[®] (1 pessary contains 100 mg of clindamycin phosphate, 150 mg of metronidazolium, 100 mg of fluconazole, 0.5 mg dexamethasonum, 200 mg of oleum hippophaes, a mixture of PEO 1500 and PEO-400 (9 : 1)⁸). The reference drugs employed were the vaginal tablets Micogynax[®] (international unpatented denomination: Comb drug, production of “Mekophar Chemical Pharmaceutical Joint-Stock Company”, Vietnam; 1 tablet contains 200 mg of metronidazolium, 80 mg of chloramphenicolum, 0.5 mg of dexamethasonum acetate, nystatinum – 100 000 IU), Gravagin[®] (unpatented denomination, production of “Sperco Ukraine”, Ukraine; 1 pessary contains 500 mg of metronidazolium), Hippophaes oleum pessaries (unpatented denomination, production of “Nizhpharm”, Russia; 1 pessary contains 500 mg of oleum Hippophaes), which have anti-inflammatory activity⁹) and are used in gynecological practice for a complex treatment of inflammatory processes of the vagina and cervix, as well as by erosion of the cervix¹⁰).

Methods

Model pathology

The study was conducted on 128 non-linear white laboratory female rats weighing 190 ± 10 g. The animals were kept on a standard diet of the vivarium. Care of them

(including euthanasia) during the experiment was carried out according to the available documents which regulate organization of the work using experimental animals. The principles of the “European Convention for the Protection of Vertebrate Animals Used for Experimental and Other Scientific Purposes” were observed (Strasbourg, 18 March 1986)¹¹), adopted by The Ist National Congress on Bioethics (Kiev, 2000), which is coordinated with the “European Convention for the Protection of Vertebrate Animals Used for Experimental and Other Scientific Purposes”, Council Directive 86/609/EEC of 24 November 1986 on the approximation of laws, regulations and administrative provisions of the Member States regarding the protection of animals used for experimental and other scientific purposes, Order of the Ministry of Health of Ukraine from February 13, 2006 No. 66, Law of Ukraine “On protection of animals from cruelty” (№3447-IV 21.02.2006)¹²). After completion of the experiment, the rats were taken out from the experiment in accordance with the ethical principles of animal testing. In accordance with the Bioethical Commission of the National Pharmaceutical University (Protocol No. 3 from 15.03.2017).

Before the beginning of the experiment, the oestrous cycle was examined in female rats and the animals in prooestrus-oestrus phases were selected, in order to minimize the differences in the assessment of the functional state of the vaginal mucosa when comparing the obtained results.

Vaginitis was modelled by a single intravaginal application of the irritant, presented by a mixture of terebenthine oil (JSC “Yantar”, Ukraine) with dimethyl sulfoxide (Dimexid, “Arterium”, JSC “Halychpharm”, Ukraine) in the ratio of 1 : 1 at the dose of 0.5 ml/100 g of the body weight of the animal. Each experimental group consisted of 16 female rats. The animals were divided into 8 groups as follows:

- Group 1 – intact animals (intact control, no pathology)
- Group 2 – control pathology (positive control)
- Group 3 – animals treated with the vaginal pessaries Melanizol[®]
- Group 4 – animals treated with the vaginal pessaries Klimedeks[®]
- Group 5 – animals treated with the reference drug Hippophaes oleum pessaries
- Group 6 – animals treated with the reference drug, the vaginal pessary Gravagin[®]
- Group 7 – animals treated with the reference drug, the vaginal tablets Micogynax[®]
- Group 8 – animals to which the pessary base in an equivalent amount was applied (placebo; negative control; a mixture of PEO-1500 and PEO-400 (9 : 1)

The treatment started 24 hours after the administration of the irritant. The studied drugs were being injected into the vagina during 7 days, once a day¹³). The studied pessaries and reference drugs were injected vaginally once a day at doses calculated using the specific sustainability factors by Y.R. Rybolovliev, applied in the experimental pharmacology¹⁴).

On the 5th and 8th day, the animals (8 animals of every group) were taken out from the experiment by the method of euthanasia. After autopsy, the macroscopic study of vaginal mucosa of the animals of all groups was carried out, and the samples of the vagina were taken for histochemical and quantitative study of glycogen content.

Semi-quantitative study of pH

Semi-quantitative determination of pH of the content of the vagina was performed using the indicator test strips “pH-test” (Limited Liability Company “Norma”, Ukraine).

Determination of glycogen

Glycogen in the vaginal tissue in female rats was determined spectrophotometrically (Spekol 1500, “Analytik Jena AG”, Germany) at a wavelength of 620 nm after the destruction of simple sugars KOH and adding 0.2% anthrone solution¹⁵).

Histochemical studies

All samples were fixed in 10% formalin solution, dehydrated in alcohols of increasing fortress, embedded into paraffin. The Schiff test (Periodic Acid Schiff (PAS) reaction) was carried out to identify glycogen^{16, 17}. The viewing of micropreparations was performed using a microscope Granum L3003 (“Granum”, China-Ukraine), photomicrography of microscopic images was carried out with a digital camera Granum DCM 310 (“Granum”, China-Ukraine). The photos were processed on Pentium 2,4GHz computer using the Toup View programme.

Morphological studies were carried out on the basis of the Central Research Scientific Lab NUPh with an advice of Y.B. Larianovska, Senior Researcher, Candidate of Biological Sciences.

Statistical treatment

Statistical treatment of the obtained results was carried out with the program “Statistica 6.0”, using parametric and nonparametric criteria.

Results and discussion

On the first day after the administration of the mixture of irritants, inflammation and a white discharge from the vagina were observed in all female rats. On the 5th day after the treatment, the inflammation remained and the discharge was observed in animals of the control pathology, placebo and Hippophaes oleum pessaries groups; in the groups treated with the pessaries Melanizol[®], Klimedeks[®] and the vaginal tablets Micogynax[®], the inflammatory response decreased by 2 times and the discharge disappeared. In the group of animals treated the with vaginal pessary Gravagin[®], the discharge disappeared but inflammation remained on the level of the control pathology.

On the 8th day, the visible symptoms of the inflammation completely disappeared and there was no discharge from the vagina in the animals treated with the pessaries Melanizol[®], Klimedeks[®], Hippophaes oleum pessaries, Gravagin[®] and the vaginal tablets Micogynax[®]. In the groups of control pathology and placebo, the inflammatory response remained and the discharge from the vagina disappeared.

Table 1. The pH indicator in the vagina of female rats treated with vaginal pessaries Klimedeks[®], Melanizol[®] and reference drugs on the background of experimental vaginitis (average \pm SD, n = 8)

Group	pH, standard units		
	1 st day	5 th day	8 th day
Intact control	7.06 \pm 0.15	7.13 \pm 0.13	7.00 \pm 0.13
Control pathology	8.13 \pm 0.13*	8.50 \pm 0.09*	8.13 \pm 0.08*
Melanizol [®]	8.31 \pm 0.09*	7.88 \pm 0.08***/§/♣	7.50 \pm 0.09***/#/♣
Klimedeks [®]	8.13 \pm 0.16*	7.56 \pm 0.18**/§/♣	7.00 \pm 0.21***/#/§/♣
Placebo	8.44 \pm 0.06*	8.31 \pm 0.09*	7.88 \pm 0.08*/♣
Hippophaes oleum pessaries	8.38 \pm 0.08*	8.13 \pm 0.18*	7.81 \pm 0.09***/♣
Gravagin [®]	8.38 \pm 0.08*	8.19 \pm 0.13*	7.69 \pm 0.09***/#/♣
Micogynax [®]	8.25 \pm 0.13*	8.00 \pm 0.13**/**	7.50 \pm 0.13***/#/♣

*significant in relation to intact control (p \leq 0.05)

**significant in relation to control pathology (p \leq 0.05)

#significant in relation to the Hippophaes oleum (p \leq 0.05)

&significant in relation to the Gravagin[®] pessaries (p \leq 0.05)

@significant in relation to the vaginal tablets Micogynax[®] (p \leq 0.05)

§significant in relation to placebo (p \leq 0.05)

♣significant in relation to the first day of the study (p \leq 0.05)

n – number of animals in the group

Effect of Klimedeks® and Melanizol® on the level of pH in rats with experimental vaginitis

During the experiment, the changes in the pH indicator observed are tabulated in Table 1.

Table 1 shows that on the background of the model pathology the day after modelling of vaginitis, changes in pH toward alkalinity were observed, compared with animals in the intact control group, being maintained throughout the whole experiment, which may indicate a breach of the barrier functions of the vaginal epithelium, as well as the accession of infection^{1, 6)}. During the treatment with the studied drugs and reference drugs, a significant decrease in pH by the 8th day of the experiment was observed, compared with the first day of the study, which indicates their therapeutic effect in comparison with animals of the control pathology group. The studied pessaries Melanizol® and Klimedeks® significantly lowered the pH in the studied animals on the 5th and 8th day of the experiment in comparison with control pathology, significantly exceeding the placebo group and the reference drug Hippophaes oleum pessaries. Throughout the experiment, the vaginal pessaries Melanizol® and Klimedeks® were practically of the same efficiency as the vaginal tablets Micogynax® in the indices and surpassed the pessaries Gravagin®.

Shifting of the pH to the alkaline side on the background of vaginitis or bacterial vaginosis indicates excess glycogen hydrolysis and a reduction of its synthesis¹⁸⁾. As a result, there is a depletion of the pool of *Lactobacilli* and their replacement by opportunistic and pathogenic flora. These criteria are crucial for the development of this pathology¹⁸⁾.

Thus, an increase in pH leads to a decrease in glycogen^{19–21)} and a reduction of the number of *Lactobacilli*,

which in turn provokes a further decrease in pH²⁰⁾. Therefore, the study of the content of glycogen in the vaginal epithelium in the dynamics on the background of vaginitis may be indicative of the effectiveness of the therapy²²⁾.

Effect of Klimedeks® and Melanizol® on the level of glycogen in rats with experimental vaginitis

The results of the quantitative determination of glycogen in the vaginal tissue are presented in Table 2.

The data in Table 2 show that the level of glycogen in the control pathology group significantly decreased on the 5th day of treatment by 1.4 times, which is associated with a significant damage of the mucous membrane of the vagina, on the 8th day the level of glycogen partially restored but did not reach the level of the intact control. In the animals treated with placebo, the index of glycogen on the 5th and 8th day remained on the level of control pathology. In the animals treated with the pessaries Melanizol®, the level of glycogen on the 5th and 8th day was significantly higher than in the animals of the control pathology and placebo groups. In the animals treated with the pessaries Gravagin® and the Hippophaes oleum pessaries, the level of glycogen was lower than in the animals treated with the pessaries Melanizol®. By the end of the experiment, the level of glycogen in the groups of the animals treated with the vaginal tablets Micogynax® and the pessaries Melanizol® was the same.

On the 5th and 8th day, the animals treated with the pessaries Klimedeks® significantly surpassed the control pathology group in the ability to store glycogen. With regard to the reference drugs, the pessaries Klimedeks® surpassed the pessaries Gravagin® and were significantly superior to the Hippophaes oleum pessaries in the ability of the vaginal epithelium to store glycogen, but were less

Table 2. The level of glycogen in the vagina of female rats treated with the vaginal pessaries Klimedeks®, Melanizol® and the reference drugs on the background of experimental vaginitis (average \pm SD, n = 8)

Group	Glycogen, mg/g	
	5 th day	8 th day
Intact control	0.76 \pm 0.02	0.76 \pm 0.01
Control pathology	0.53 \pm 0.06*	0.70 \pm 0.04
Melanizol®	0.98 \pm 0.05***/#/@/§	0.93 \pm 0.06***/#/&/§
Klimedeks®	0.90 \pm 0.06***/#/@/§	0.81 \pm 0.07
Placebo	0.60 \pm 0.05*	0.74 \pm 0.05
Hippophaes oleum pessaries	0.68 \pm 0.02**/**	0.72 \pm 0.02
Gravagin®	0.86 \pm 0.01***/#/@/§	0.74 \pm 0.01
Micogynax®	1.30 \pm 0.11***/#/@/§	0.94 \pm 0.02***/#/&/§

*significant in relation to intact control (p \leq 0.05)

**significant in relation to control pathology (p \leq 0.05)

#significant in relation to the Hippophaes oleum (p \leq 0.05)

&significant in relation to the Gravagin® pessaries (p \leq 0.05)

@significant in relation to the vaginal tablets Micogynax® (p \leq 0.05)

§significant in relation to placebo (p \leq 0.05)

n – number of animals in the group

efficient than the vaginal tablets Micogynax® to a certain degree.

An increase in the level of glycogen under the influence of the pessaries Klimedeks® and Melanizol® may indicate an increase in the amount of *Lactobacilli* and confirms a decrease in pH in comparison with the control pathology group²³).

The data of the quantitative determination of glycogen are confirmed by histomorphological studies²⁴).

Histochemical studies of effect of Klimedeks® and Melanizol® in rats with experimental vaginitis

When setting the Schiff test (Periodic Acid Schiff (PAS) reaction), the cells of intermediate and functional layers of animals of the intact control group clearly stained as positive, indicating the presence of a considerable amount of glycogen. Figure 1 illustrates a normal glycogen content in the vaginal mucosa of the vagina of intact female rats.

On the 5th day after the administration of the mixture of terebenthine oil and dimethyl sulfoxide, it was observed that 87.5% of females in the control pathology group had focal or extended destructive and inflammatory changes. When setting the PAS reaction, it was found out that glycogen is formed and stored typically in the cells of intermediate and functional layers in the areas with a pre-

served epithelial formation, still in places it is present mosaically in the formation, mainly in the distal vaginal mucosa. Figures 2A and 2B illustrate the accumulation of glycogen in the epithelial cells of the vagina of female rats on the 5th day after the administration of the mixture of terebenthine oil and dimethyl sulfoxide.

On the 8th day of the experiment, the changes in the mucous membrane of the vagina in the female rats of the control pathology group were not significant. Glycogen is sufficiently visually accumulated in the cells of intermediate and functional layers. Figures 3A and 3B illustrate accumulation of glycogen in the epithelium of female rats on the 8th day after the administration of the mixture of terebenthine oil and dimethyl sulfoxide.

The administration of the vaginal pessaries Klimedeks® positively influenced the condition of the vaginal mucosa, injured with the mixture of terebenthine oil and dimethyl sulfoxide. On the 5th day of the experiment, the intensity of PAS reaction in the epithelial cells was fully consistent with the norm, indicating the presence of glycogen in them. Figure 4 illustrates the content of glycogen in the epithelial cells of rats treated with vaginal pessaries Klimedeks® on the 5th day.

On the 8th day after the administration of the mixture of terebenthine oil and dimethyl sulfoxide, the vaginal mucosa of all rats treated with the vaginal pessaries Klime-

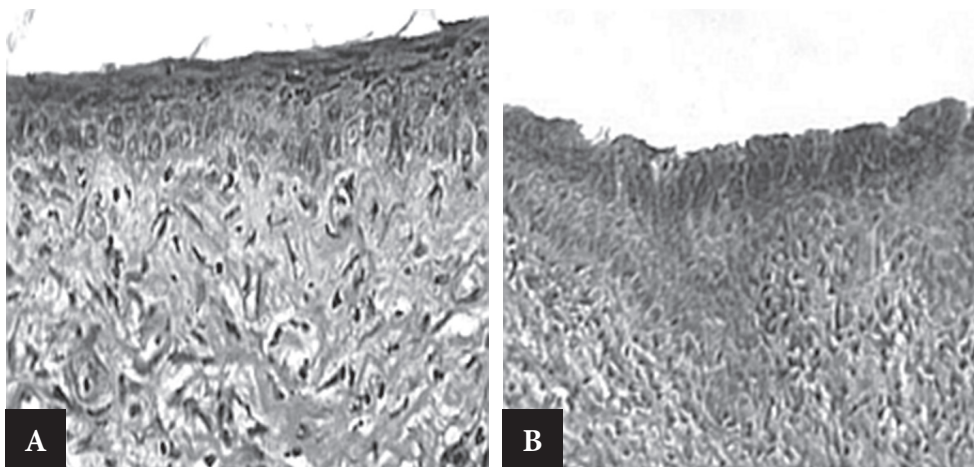


Fig. 1. The wall of the vagina of intact female rats: A, B – a normal glycogen content in the epithelium of the proximal part of the mucous membrane of the vaginal wall (oestrus phase, prooestrus phase). PAS reaction. $\times 250$

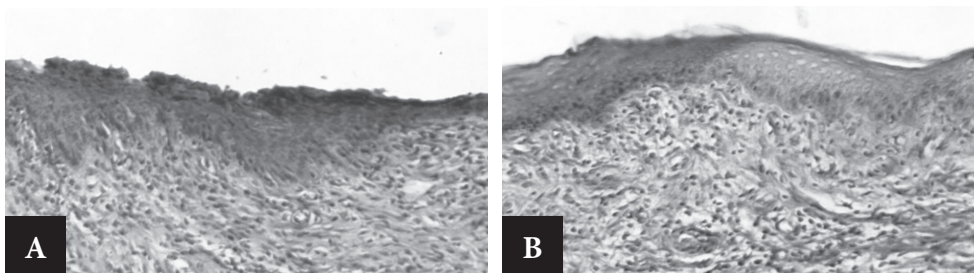


Fig. 2. The wall of the vagina of female rats on the 5th day after the administration of the mixture of terebenthine oil and dimethyl sulfoxide: A, B – the accumulation of glycogen in the epithelial cells (A – typical, B – a mosaic, oestrus phase). PAS reaction. $\times 200$

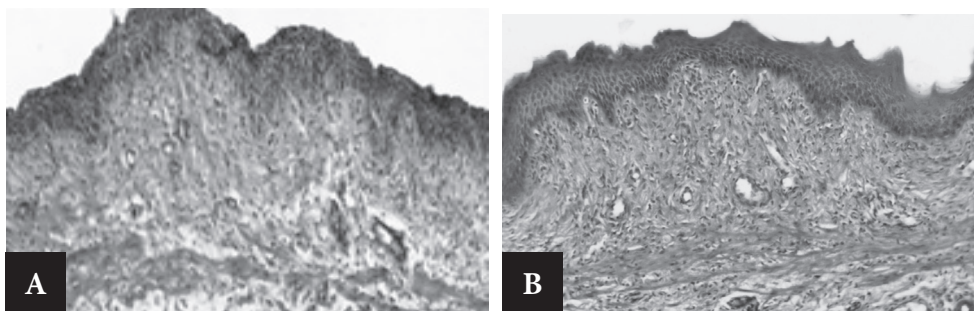


Fig. 3. The wall of the vagina of female rats on the 8th day after the administration of the mixture of terebenthine oil and dimethyl sulfoxide. Proximal part: A – normal accumulation of glycogen in the epithelium ($\times 200$). Prooestrus phase. Distal part: B – glycogen content is normal ($\times 200$). Oestrus phase. PAS reaction.

deks[®] responded to the physiological norm by the glycogen content in the epithelial cells. Figure 5 illustrates the average glycogen content in the epithelial cells of the vagina of female rats treated with the vaginal pessaries Klimedeks[®] on the 8th day after the administration of the mixture of terebenthine oil and dimethyl sulfoxide.

On the background of treatment with the vaginal pessaries Melanizol[®], on the 5th day after the administration of the mixture of terebenthine oil and dimethyl sulfoxide, the glycogen content in the cells of intermediate and functional layers of the epithelium responded to the intact control in 75% of female rats. Figure 6 illustrates the nor-

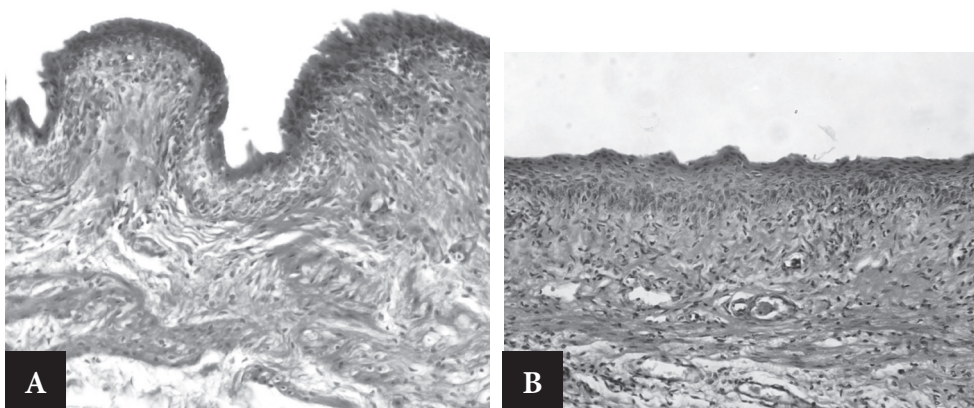


Fig. 4. The wall of the vagina of female rats treated with vaginal pessaries Klimedeks[®] on the 5th day after the administration of the mixture of terebenthine oil and dimethyl sulfoxide. The content of glycogen in the epithelial cells is normal: A – proximal, B – distal part. Oestrus phase. PAS reaction. $\times 200$

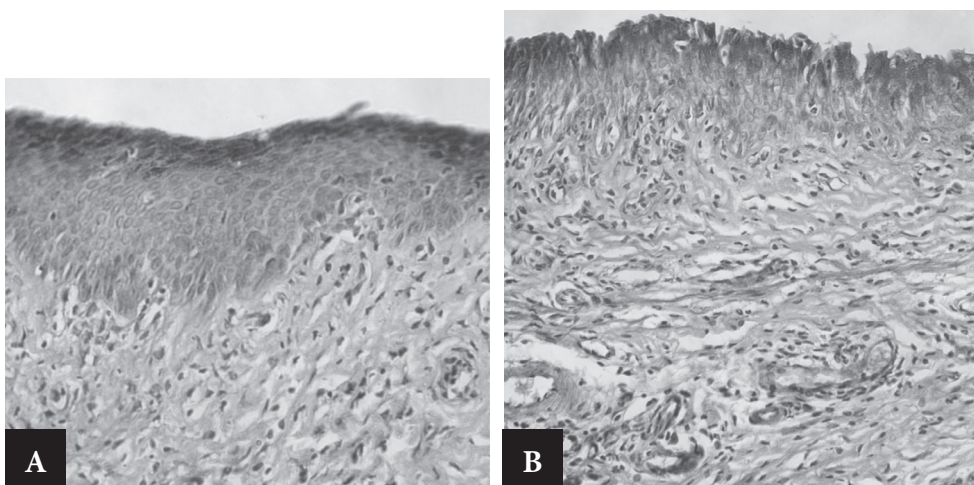


Fig. 5. The wall of the vagina of female rats treated with the vaginal pessaries Klimedeks[®] on the 8th day after the administration of the mixture of terebenthine oil and dimethyl sulfoxide. The average glycogen content in the epithelial cells (A – distal, B – proximal part). Prooestrus phase, PAS reaction. $\times 200$

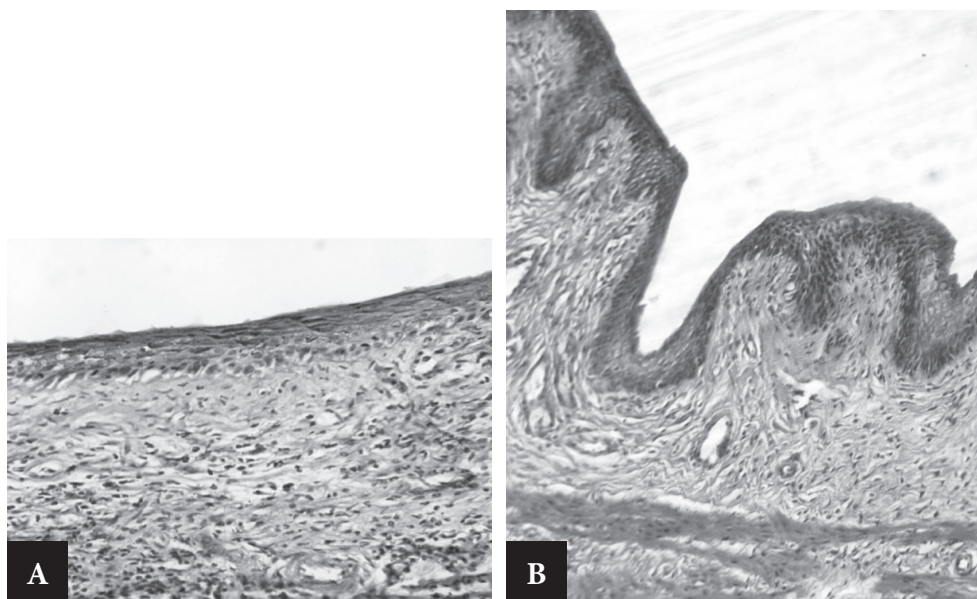


Fig. 6. The wall of the vagina of female rats treated with the vaginal pessaries Melanizol[®] on the 5th day after the administration of the mixture of terebenthine oil and dimethyl sulfoxide. The normal state of the intensity of PAS reaction in A – distal ($\times 200$), B – proximal ($\times 100$) parts. Oestrus phase. PAS reaction.

mal state of the intensity of PAS vaginal mucosa reaction of the vagina of female rats treated with the vaginal pessaries Melanizol[®] on the 5th day after the administration of the mixture of terebenthine oil and dimethyl sulfoxide. In 25% of the animals, glycogen in the epithelial cells was determined not equally. Figure 7A illustrates a non-uniform accumulation of glycogen in the epithelial cells of the vagina of female rats treated with the vaginal pessaries Melanizol[®] on the 5th day after the administration of the mixture of terebenthine oil and dimethyl sulfoxide. On the 8th day of the experiment, in all 100% of the animals of the group there were no changes in the wall of the vagina, PAS reaction was typical. Figure 7B illustrates the wall of the vagina of female rats treated with the vaginal pessaries Melanizol[®] on the 8th day after the admi-

nistration of the mixture of terebenthine oil and dimethyl sulfoxide in the proximal part.

On the 5th day of the experiment after the administration of the Hippophaes oleum pessaries, 37.5% (3 of 8) female rats had mucosa defects in the wall of the vagina, which varied in extension and depth. Outside the areas of destruction, a normal accumulation of glycogen in the epithelial cells was observed. Figure 8A illustrates a significant PAS reaction in the epithelial cells of the wall of the vagina in female rats treated with the Hippophaes oleum pessaries on the 5th day after the administration of the mixture of terebenthine oil and dimethyl sulfoxide.

In the remaining 62.5% of female rats, the intensity of the PAS reaction responded to the physiological norm, as in all animals on the 8th day of the experiment. Figures 8B,

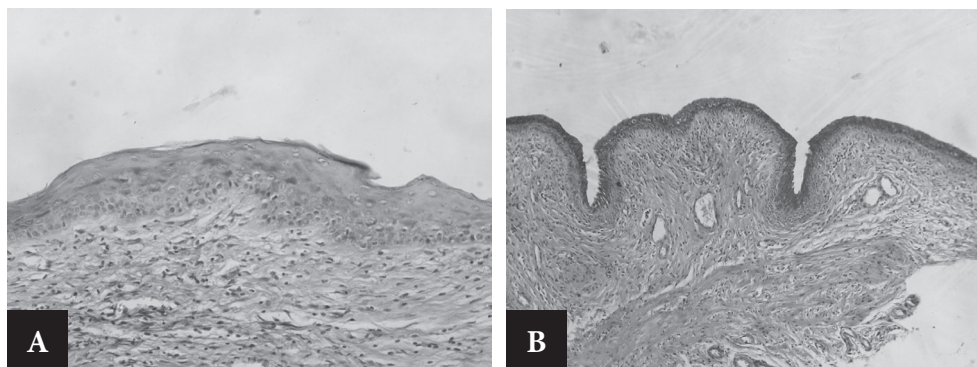


Fig. 7. The wall of the vagina of female rats treated with the vaginal pessaries Melanizol[®], A – on the 5th day after the administration of the mixture of terebenthine oil and dimethyl sulfoxide: non-uniform accumulation of glycogen in the epithelial cells. PAS reaction. $\times 200$; B – on the 8th day after the administration of the mixture of terebenthine oil and dimethyl sulfoxide in the proximal part (Prooestrus phase). PAS reaction. $\times 200$



Fig. 8. The wall of the vagina in female rats treated with the *Hippophaes oleum* pessaries on the 5th day after the administration of the mixture of terebenthine oil and dimethyl sulfoxide: significant PAS reaction in the epithelial cells (Oestrus phase), on the 5th day (A – Oestrus phase) and on the 8th day (B – Oestrus phase, C – Prooestrus phase) after the administration of the mixture of terebenthine oil and dimethyl sulfoxide. The ability of the epithelial cells to accumulate glycogen is not changed. PAS reaction. $\times 100$

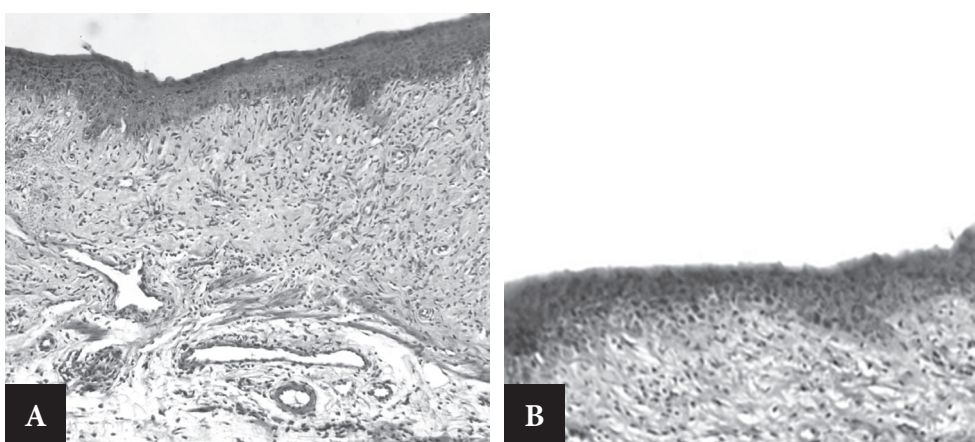


Fig. 9. The wall of the vagina of female rats treated with vaginal pessaries Gravagin[®], on the 5th day after the administration of the mixture of terebenthine oil and dimethyl sulfoxide: A, B – normal mucosal structure (oestrus phase), an expressive PAS reaction in the epithelial cells. PAS reaction. $\times 100$

8C illustrate the wall of the vagina in female rats treated with the *Hippophaes oleum* pessaries on the 8th day after the administration of the mixture of terebenthine oil and dimethyl sulfoxide.

Figure 9 illustrates the normal mucosal structure of the wall of the vagina of female rats treated with the vaginal pessaries Gravagin[®], on the 5th day after the administration of the mixture of terebenthine oil and dimethyl sulfoxide. On the background of the administration of the pessaries Gravagin[®] on the 5th day after the administration of the mixture of irritants, a sufficiently large cell destruction of the vaginal wall was found in 50% of females. In the undamaged areas, the clear PAS reaction in the cells of the epithelium was observed.

Figure 10 illustrates the wall of the vagina in female rats treated with the vaginal pessaries Micogynax[®], on the 5th day after the administration of the mixture of terebenthine oil and dimethyl sulfoxide. A similar effect on the condition of the vaginal wall was caused also by the vaginal tablets Micogynax[®]. On the 5th day after the administration of the mixture of terebenthine oil and dimethyl sulfoxide, in 2 of 8 females there were very extensive areas of damage of the vaginal wall. In the remaining animals the destruction of the vaginal wall was not revealed. In

the undamaged areas, an expressive PAS reaction in the epithelial cells was observed (Fig. 10).

After the administration of placebo vaginal pessaries, practically no positive changes in the state of the vagi-

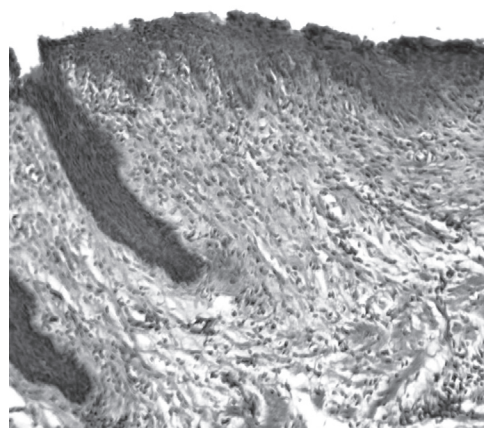


Fig. 10. The wall of the vagina in female rats treated with the vaginal pessaries Micogynax[®], on the 5th day after the administration of the mixture of terebenthine oil and dimethyl sulfoxide: an expressive PAS reaction (oestrus phase). PAS reaction. $\times 100$

nal wall of most of the female rats on the 5th day of the experiment were found, in comparison with the control pathology group. On the 8th day, the same as in the control pathology, a natural regression of the pathological process was taking place.

Summarizing the obtained microscopic data, we can draw the following conclusions. On the 5th day after the intravaginal administration of the mixture of terebenthine oil and dimethyl sulfoxide, in the vagina of the vast majority of female rats the focal or extensive destructive and inflammatory changes were observed. In the undamaged areas of the vaginal wall, the epithelium retained the ability for functional physiological transformations, inherent in the phases of the oestrous cycle, the synthesis and accumulation of glycogen, although sometimes the thickening of the epithelial layer, mosaic accumulation of glycogen in the epithelial cells were observed, which was accompanied by a significant decrease in its content. By the 8th day the physiological properties of the vaginal epithelium recovered.

The therapeutic administration of the vaginal pessaries Klimedeks[®] restored the physiological condition of the vaginal mucosa on the 5th day. The administration of the vaginal pessaries Melanizol[®] had a therapeutic impact in 75% of the animals on the level of the reference drug, the vaginal tablets Micogynax[®]. On the 5th day the therapeutic effect of the reference drug Hippophaes oleum pessaries (62.5%) and the vaginal pessaries Gravagin[®] (50%) were less efficient than the pessaries Klimedeks[®] and Melanizol[®]. By the 8th day, in 100% of animals treated with the studied drugs, there was a restoration of physiological properties of the vaginal epithelium to accumulate glycogen in line with the animals of the intact control group.

Vaginal pessaries placebo were on the level of control pathology, and on the 5th day showed practically no therapeutic effect, but by the 8th day there was a natural regression of the pathological process.

The synthesis and accumulation of glycogen in large quantities is typical exactly of the vaginal epithelial cells. Protective functions of regeneration and keratinization are in line with the high level of metabolism in the epithelium, and glycogen is the energy source for the synthesis of keratin⁽²⁵⁾. The amount of glycogen in the vaginal epithelium is regulated by estradiol^(26–29).

The ability of the vaginal epithelium of rats to accumulate glycogen under the influence of the pessaries Klimedeks[®], Melanizol[®] and the vaginal tablets Micogynax[®] can be explained by the reparative properties of the studied drugs and by an increase in the energy reserve of the vaginal epithelium. Probably the presence of dexamethasonum, the hormonal substance of steroid nature, in the pessaries Klimedeks[®] and Micogynax[®] may indirectly activate the accumulation of glycogen by the vaginal epithelium. This mechanism requires a further detailed study.

Conclusions

Based on the foregoing, the obtained experimental data indicate that on the background of experimental vaginitis

caused by the mixture of terebenthine oil with dimethyl sulfoxide, on the 5th and 8th day of the experimental vaginal pessaries Melanizol[®] and Klimedeks[®] had a therapeutic effect, significantly reducing the pH and increasing the level of glycogen in comparison with the control pathology. The pessaries Melanizol[®] and Klimedeks[®] surpassed the pessaries Gravagin[®] and Hippophaes oleum in the effectiveness, and were practically of the same efficiency as the vaginal tablets Micogynax[®]. The pessaries Melanizol[®] and Klimedeks[®] significantly surpassed the reference drugs Gravagin[®] and the Hippophaes oleum pessaries in the ability to restore the physiological functions and accumulate glycogen by the vaginal epithelium, but were less efficient than the reference drug, the vaginal tablets Micogynax[®] in the activity. Also in the groups of the pessaries Melanizol[®] and Klimedeks[®], an increase in the level of glycogen in animals was observed in comparison with the animals of intact control. This may indicate an increase in the energy reserve in the vaginal tissue and contribute to the reproduction of *Lactobacilli*. Thus, the vaginal pessaries Melanizol[®] and Klimedeks[®] are perspective drugs for further studies as medications for the treatment of vaginitis.

Conflicts of interest: none.

References

1. **Atashili J., Poole C., Ndumbe P. M., Adimora A. A., Smith J. S.** Bacterial vaginosis and HIV acquisition: A meta-analysis of published studies. *AIDS* 2008; 22(12), 1493–1501.
2. **Hill L. V.** Vaginitis: current microbiologic and clinical concepts. *CMAJ* 1986; 134(4), 321–331.
3. **Burka O. A.** One of the approaches in the treatment of inflammatory vaginitis. Newspaper “News of Medicine and Pharmacy”. Obstetrics, gynecology, reproduction 2011; 381. http://www.mif-ua.com/archive/article_print/22944
4. **Boskey E. R., Cone R. A., Whaley K. J., Moench T. R.** Origins of vaginal acidity: High D/L lactate ratio is consistent with bacteria being the primary source. *Hum Reprod.* 2001; 16(9), 1809–1813.
5. **Wilson W. A., Roach P. J., Montero M., Baroja-Fernández E., Muñoz F. J., Eydallin G., Viale A. M., Pozueta-Romero J.** Regulation of glycogen metabolism in yeast and bacteria. *FEMS Microbiol Rev.* 2010; 34(6), 952–985.
6. **Mirmonsef P., Gilbert D., Veazey R. S., Wang J., Kendrick S. R., Spear G. T.** A Comparison of Lower Genital Tract Glycogen and Lactic Acid Levels in Women and Macaques: Implications for HIV and SIV Susceptibility. *AIDS Res. Hum. Retroviruses* 2012; 28(1), 76–81.
7. **Yarnykh T. G., Levachkova Y. V., Maloshtan L. M., Stepanova K. O.** Anti-inflammatory agent in the form of pessaries with metronidazole and tea tree oil: Patent. 96646 of Ukraine for invention; the applicant and patentee: National University of Pharmacy a 2010 01 134; announced on 04.02.2010; published on 25.11.2011, bull. N 22; 3.
8. **Stepanova K. O., Dolzhykova O. V., Maloshtan L. M., Levachkova Yu. V., Chushenko V. M., Yarnykh T. G.** Preparation in the form of pessaries for treatment of infectious and inflammatory gynecological diseases: Patent 61038 of Ukraine for utility model; the applicant and patentee: National University of Pharmacy u 2010 13780; announced on 19.11.2010; published on 11.07.2011, bull. 13; 5.
9. **Sergienko A. V., Alieva M. U., Sampieva K. T., Ivashev M. N.** Effects of Metronidazole and Likopid on experimental inflammation. *Kuban scientific medical news.* 2009; 8(113), 68–74.

10. **Chernichenko I. I.** The use of Hippophaes oleum in gynecological practice. TERRA MEDICA 2006; 2, 26–29.
11. **European convention for the protection of vertebral animals used for experimental and other scientific purpose.** Council of Europe 18.03.1986. Strasbourg 1986; 52.
12. **Nizhenkovska I. V., Pidchenko V. T., Bychkova N. G., Bisko N. A., Rodnichenko A. Y., Kozyko N. O.** Influence of Ganoderma lucidum (Curt.: Fr.) P. Karst. on T-cell-mediated immunity in normal and immunosuppressed mice line CBA/Ca. Čes. slov. Farm. 2015; 64(4), 139–143.
13. **Rudko A. Y., Solntseva A. V., Usoieva L. A., Morugina L. V.** Pharmaceutical composition for treatment of diseases of the urogenital organs: Patent 95741 of Ukraine for invention; the applicant and patentee: Public corporation “Nizhegorodskiy Chemical-Pharmaceutical Plant” a201010120; announced on 16.08.2010; published on 25.08.2011, bull. 16; 11.
14. **Rybolovliev Y. R., Rybolovliev R. S.** Dosing substances for mammals according to the constants of biological activity. In: Reports of the USSR Academy of Sciences 1979; 247(6), 1513–1516.
15. **Meshkovi N. P., Severina S. E.** Method of determination of glucose and glycogen with anthrone. In: Practicum in biochemistry. Moscow: Publishing House of Moscow State University 1979; s. 41–43.
16. **Kononskii A. I.** Histochemistry. Kiev: Vishha shkola 1976.
17. **Merkulov G. A.** Histopathological technology course. Moscow: Medicine, Leningrad department 1969.
18. **Usov M. A.** Clinical and diagnostic aspects of dysbiosis of vagina and treatment of bacterial vaginosis in women in early pregnancy: abstract of dissertation ... candidate of medical sciences. Samara 2010; 24.
19. **Kent C.** The Role of Glycogen in Vulvovaginal Health. <https://wholewoman.com/blog/?p=1041> (1. 02. 2012).
20. **Mirmonsef P., Hotton A. L., Gilbert D., Burgad D., Landay A., Weber K. M., Cohen M., Ravel J., Spear G. T.** Free Glycogen in Vaginal Fluids Is Associated with *Lactobacillus* Colonization and Low Vaginal pH. PLoS One 2014; 9(7)e102467, 1–11.
21. **Mirmonsef P., Hotton A. L., Gilbert D., Gioia C. J., Maric D., Hope T. J., Landay A. L., Spear G.T.** Glycogen Levels in Undiluted Genital Fluid and Their Relationship to Vaginal pH, Estrogen, and Progesterone. PLoS One 2016; 11(4), e0153553.
22. **Badretdinova F. F., Mavzyutov A. R., Sheyda L. A., Kayumov F. A.** Some aspects of determining the efficiency of therapy of vaginal dysbiosis in clinical conditions. Obstetrics and Gynecology 2015; 01(86), 92–93.
23. **Lester J., Pahouja G., Andersen B., Lustberg M.** Atrophic Vaginitis in Breast Cancer Survivors: A Difficult Survivorship Issue. J. Pers. Med. 2015; 5, 50–66.
24. **Petrov Y. A.** Mechanism of action contraceptive intrauterine device. International Journal of Applied and Fundamental Research 2016; 8, 724–726.
25. **Apolikhina I. A., Horbunova E. A.** Clinical and morphological aspects of vulvovaginal atrophy. Obstetrics and gynecology. <http://www.remedium.ru/doctor/gynaecology/detail.php?ID=67429> (19. 11. 2015).
26. **Dobrokhotova Y. E., Zatikian N. G.** Hormone status and vaginal microbiocenosis. Obstetrics, gynecology, reproduction. 2008; 2(2), 7–9.
27. **Stika C. S.** Atrophic vaginitis. Dermatol Ther 2010; 23, 514–522.
28. **Dennerstein G. J., Ellis D. H.** Oestrogen, glycogen and vaginal candidiasis. Aust N Z J Obstet Gynaecol. 2001; 41(3), 326–328.
29. **Nunn K. L., Forney L. J.** Unraveling the Dynamics of the Human Vaginal Microbiome. Yale J Biol Med. 2016; 89(3), 331–337.